

Bonding to bleached enamel treated with 10% sodium bicarbonate: a one-year follow-up

Restaurações adesivas em esmalte clareado tratado com solução de bicarbonato de sódio a 10% - 1 ano de avaliação clínica

Carla Müller RAMOS¹, Odair BIM JUNIOR¹, Raphaela Farias RODRIGUES¹, Rafael Massunari MAENOSONO¹, Marina Studart ALENCAR¹, Linda WANG¹, Ana Flávia Sanches BORGES¹

1 – Department of Operative Dentistry, Endodontics and Dental Materials – Bauru School of Dentistry – University of São Paulo – Bauru – SP – Brazil.

ABSTRACT

Objective: The aim of this case report is to present the 1-year follow-up of composite resin restorations performed on immediate bleached enamel. **Clinical considerations:** The presence of residual oxygen after bleaching may be responsible for inhibiting the polymerization of the monomers present in the adhesive systems, leading to the failure of the restorative procedure. The use of antioxidants, especially the 10% sodium bicarbonate solution (SB), could be a fast and practical alternative to improve the bond strength of these restorations. Patient with high aesthetic demands submitted to the office bleaching with hydrogen peroxide 35% received restorative procedure performed immediately after bleaching. After unsatisfactory resin composite restorations removal, the antioxidant SB was applied and the restorative procedure performed. After one year, the clinical performance of the restorations were successful, showing no signs of failure nor infiltration. **Conclusions:** The use of the 10% sodium bicarbonate in bleached enamel seems to be a viable alternative for clinical practice, however a large number of restorations of longitudinal researches will be need for corroborate this technique.

KEYWORDS

Tooth bleaching; Antioxidants; Dental bonding.

RESUMO

Objetivo: O objetivo desse relato de caso clínico é apresentar o acompanhamento de 1 ano de restaurações de resina composta realizadas em esmalte dentário recém-clareado. **Considerações clínicas:** A presença de oxigênio residual após o clareamento dentário pode ser responsável pela inibição da polimerização dos monômeros presentes nos sistemas adesivos, que pode acarretar em falha do processo restaurador. A utilização de antioxidantes, especialmente a solução de bicarbonato de sódio a 10% (SB), pode ser uma alternativa rápida e prática para melhorar a resistência de união destas restaurações. Em um paciente com alta exigência estética submetido ao clareamento de consultório com peróxido de hidrogênio a 35% foi realizado procedimento restaurador imediatamente após o clareamento dentário. Após a remoção das restaurações insatisfatórias de resina composta, o antioxidante SB foi aplicado e o procedimento restaurador realizado imediatamente. Após um ano, o desempenho clínico das restaurações de resina composta foram adequadas, não mostrando sinais de falhas nem de infiltração marginal. **Conclusões:** O uso da solução de bicarbonato de sódio a 10% no esmalte clareado se mostrou uma alternativa viável e prática, contudo um maior número de estudos longitudinais é necessário afim de corroborar com a técnica utilizada neste caso clínico.

PALAVRAS-CHAVE

Clareamento dentário; Antioxidantes; União dentária.

INTRODUCTION

In many situations, clinicians need to associate the bleaching procedure with adhesive restorations, such as diastema closure, direct veneers or replacement of defective restorations, in order to achieve an optimal aesthetic result. The interaction of these procedures should be considered in terms of bonding to dental enamel, since it is expected that bleached teeth present an ideally similar performance to unbleached dental substrates. The presence of residual oxygen after bleaching treatment may be responsible for the premature failure of the restorative procedure, by inhibiting the in situ polymerization of the crosslinker monomers of the adhesive systems [1,2]. As a result, the functional groups in the system can remain trapped as residual monomers and unreacted pendant radicals [3]. Water and bacterial enzymes can diffuse into the loosely cross-linked domains and promote degradation of the adhesive, undermining the integrity of the tooth-adhesive interface [4,5]. The marginal seal may be compromised, resulting in a reduction in bond strength and the long-term performance of restorations [6-8].

The most common alternative to this clinical situation is delaying the restorative procedure for at least one week [8,9] in order to completely eliminate the residual oxygen that slowly dissipates to the extent that the oxidation reaction ends. Even considering that the reduction in the bond strength is temporary, several techniques have been proposed in order to reduce this time interval. Among these strategies, literature has shown the removal of the superficial enamel [10], the use of alcohol before the restoration [11,12] and the use of adhesives containing organic solvents [13].

In this context, the use of antioxidants can be highlighted since it seems to be a more

effective alternative to reduce or remove the residual oxygen [11,14]. The sodium ascorbate is the most investigated antioxidant [9,13-15] and despite its efficiency in reducing microleakage has been pointed out previously [15], there is still some controversy about its mechanisms [11]. Recent study [16] have shown promising results with the application of the 10% sodium bicarbonate (SB), present in whitening kits, for 5 min on bleached enamel.

The aim of this case report is to describe the clinical success of a one year-follow-up of two class IV restorations placed on bleached enamel previously treated with SB.

CASE REPORT

Male patient, 32 years old, sought care at the clinic of Dentistry, Bauru School of Dentistry, University of São Paulo, reporting esthetic dissatisfaction related to the general darkening of teeth after orthodontic treatment. Two Class IV restorations placed on teeth 11 and 21 (Figure 1) were opaque and unsatisfactory. From a palatal view, infiltration in the margins could be observed (Figure 2), indicating the need for replacement of the restorations. The treatment plan should involve teeth bleaching and subsequent replacement of the Class IV restorations.

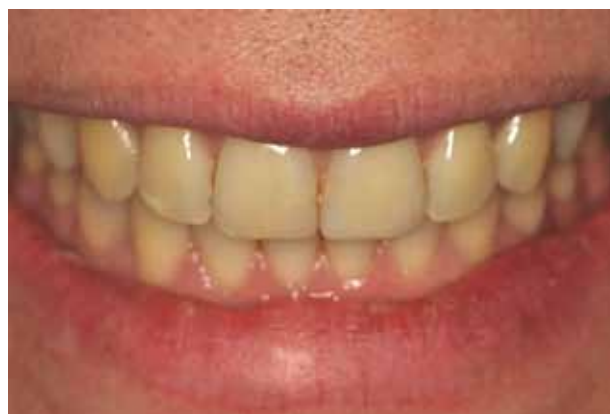

Figure 1 - Opaque and unsatisfactory Class IV restorations placed on teeth 11 and 21.

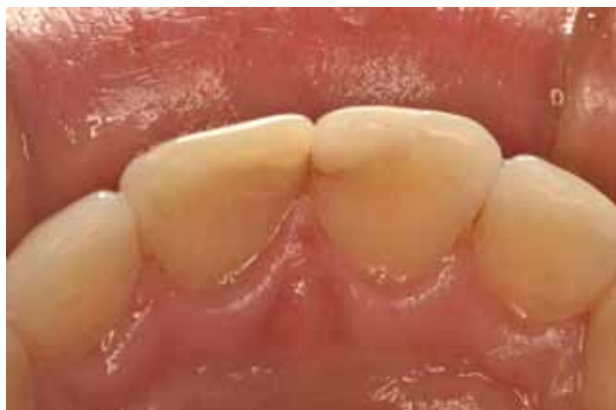

Figure 2 - Palatal view: infiltration in the margins.

Tooth whitening

In-office bleaching protocol was performed (Figure 3) in two sessions. Teeth were subjected to prophylaxis with a brush and abrasive paste (Herjos F – Vigodent, RJ, Brazil) followed by rinsing with water. After that, preoperative shade selection (A3,5) was checked with VITA classical A1-D4 colour scale (Vita Zahnfabrik, Bad Säckingen, Germany). Gingival barrier were used to gingival mucose isolation and prevent tissue irritation. In each session, three applications of 35 % hydrogen peroxide (Lase Peroxide Sense, DMC, Ribeirão

Preto, SP, Brazil) were performed for twelve minutes each. Following the last application, the whitening gel was completely removed from the teeth with the surgical suction tip and the polishing of the teeth in the vestibular faces was performed on all groups with a felt disc impregnated with abrasives (Lase Peroxide, DMC) to reestablish the enamel smoothness. 1.23% acidulated phosphate fluoride gel were application for 3 min in all teeth. After the last session, posoperative shade selection (A1) was checked.

Application of antioxidant agent

Due to aesthetic demands of the patient who would not accept to wait seven days for the replacement of the restorations, the SB apply were performed in an attempt to improve the condition of the enamel surface to receive the adhesive system immediately. Thereby, the unsatisfactory restorations in 11 and 21 were totally removed and enamel surface were air-dried. Sodium bicarbonate solution (SB) (Neutralize solution, DMC) that was available in-office bleaching kit were applied with a microbrush applicator by 5 min timeout (Figure 4). SB were removed and the surface was cleaned and dried.

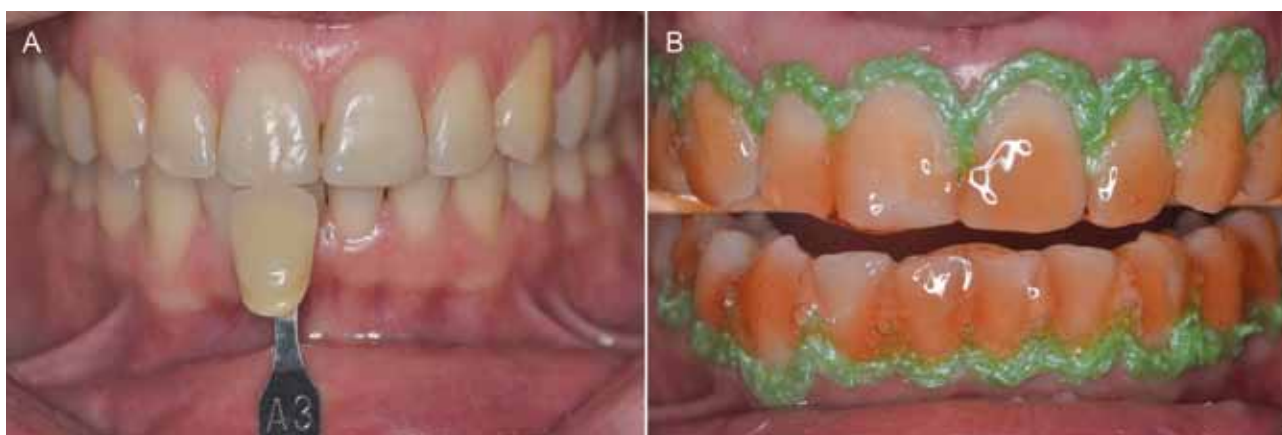

Figure 3 - A) Initial color of teeth (A3) with Vita scale (VITA Zahnfabrik); **B)** Teeth bleaching with 37 % hydrogen peroxide performed in 2 sessions of 3 applications of 12 min each.

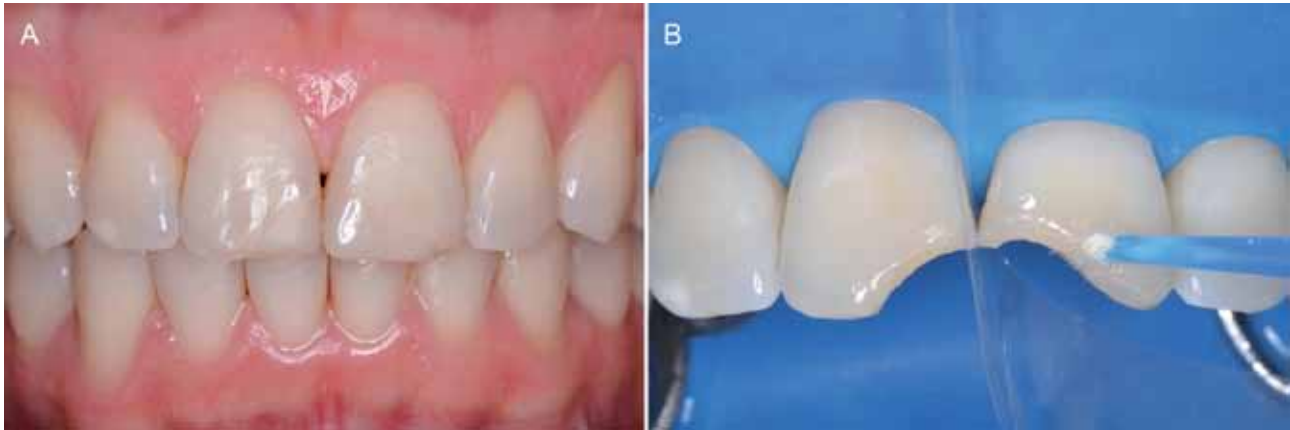

Figure 4 - A) After the bleaching: finalcolor of teeth (A1) with Vita scale (VITA Zahnfabrik) **B)** Unsatisfactory restorations were removed and the SB was applied for 5 min.

Restorative Procedure

After that, the restorative procedure was initiated with the etching of the surfaces with 37 % phosphoric acid for 30 s, rinsed thoroughly and air-dried. Then, since the teeth had dentin margins to be restored, we decided to use the adhesive systems (Schotbond Multipurpose, 3M ESPE, St.Paul, USA) followed by the application of the composite resin A1 dentin, body and enamel (Z-350 XT, 3M ESPE) (Figure 5). The finishing and polishing were performed with the sequence of abrasive discs Sof-lex Pop-on (3M ESPE) and abrasive silicone tips (KG Sorensen, São Paulo, SP, BRA). The final results in figure 6.

Clinical Follow-up

The evaluation after one year shown that the restorations remained stable, with no carious lesions and no sign of pulpal or periodontal disease (Figure 7). Experience examiner analyzed the restorations based on modified United States Public Health Service (USPHS) criteria, using the following parameters [17]: 1- restoration retention (visual inspection with an explorer), 2- preservation of tooth vitality (thermal sensitivity test), 3- marginal discoloration (visual inspection with mirror), 4- enamel and dentine marginal integrity (visual inspection with mirror), 5- postoperative sensitivity (blowing a stream of compressed air for 5 s) and 6- caries occurrence (visual inspection).

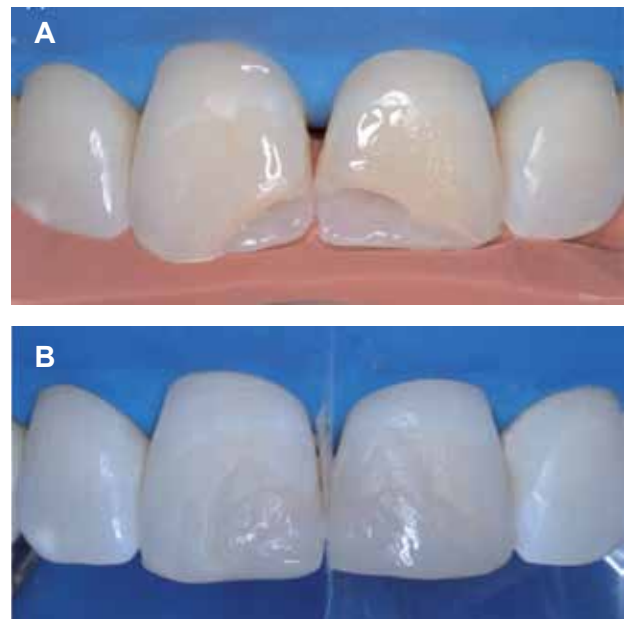


Figure 5 - A-B) Restorative procedure with composite resin.

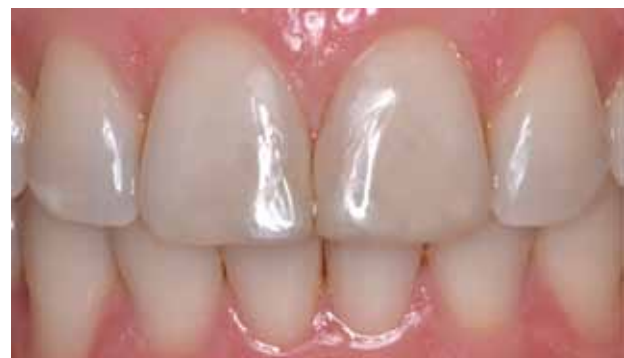

Figure 6 - Final results.

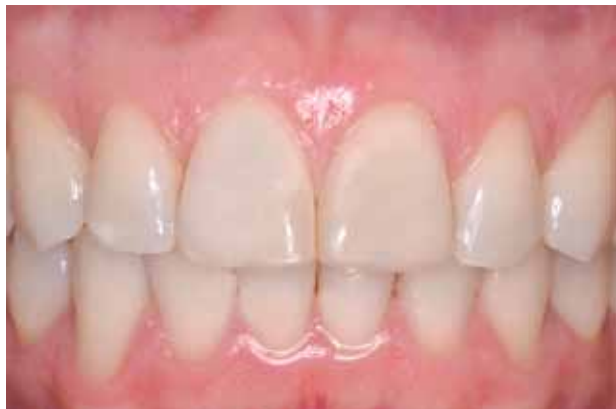

Figure 7 - After one year; restorations remained stable and satisfactory.

DISCUSSION

Dental bleaching has become a widely used treatment commonly associated with bonding procedures either for direct or indirect restoration [18]. In order to meet the high aesthetic demands of the patients nowadays, replacing these restorations immediately after teeth bleaching is eventually mandatory, as described in this case report. With regards to these situations where the dentist cannot wait the seven days intended for the optimal replacement of the restorations [8,9], many alternatives have been described in the literature [10-12] and the use of antioxidants is a handy one [9,11,13,15,16].

The 10 % sodium bicarbonate aqueous solution has been presented by manufacturers of bleaching agents as a neutralizer for the adverse effects in soft tissues. Its high pH (8.67) can destabilize the hydrogen peroxide molecule leading to its breakdown and inactivation [19]. This product is available in bleaching kits thus being handy to use. Even with promising results regarding the adhesion to the dental substrate [16], it is important to consider other important requirements leading to the success of the restorative procedure, such as the correct choice of the color. This step is very important to procedure success and may be a challenge to dentist. Since the teeth were dehydrated during the bleaching and the stabilization of the new

Chroma may take a few days. Therefore, the chance of wrong Chroma choice is very large. Whereas the requirement of the patient was not just stay with difference in teeth/restoration color after bleaching is essential makes clear the possibility of chroma error or a future exchange of restoration to achieve the ideal chroma.

Considering that there are few laboratory studies with the use of SB that support its effectiveness, longitudinal studies with a significant number of restorations in vivo should be performed in order to confirm the results found in this case report.

CONCLUSION

After one year, no alterations of color and shape were observed in the restorations. No presence of carious lesions too. The use of antioxidants, (10% sodium bicarbonate solution), could be a fast and practical alternative to improve the bond strength of these restorations. This restorative approach seems promising for cases of urgency aesthetic, but further studies are necessary for its consolidation.

DISCLOSURE

The authors do not have any financial interest in any of the companies whose products are included in this article.

REFERENCES

1. Stokes AN, Hood JA, Dhariwal D, Patel K. Effect of peroxide bleaches on resin-enamel bonds. *Quintessence Int.* 1992;23(11):769-71.
2. Barcellos DC, Benetti P, Fernandes VV, Jr., Valera MC. Effect of carbamide peroxide bleaching gel concentration on the bond strength of dental substrates and resin composite. *Operative dentistry.* 2010;35(4):463-9.
3. Ye Q, et al. Quantitative analysis of aqueous phase composition of model dentin adhesives experiencing phase separation. *Journal of Biomedical Materials Research Part B: Applied Biomaterials.* 2012;100(4):1086-92.
4. Abedin F, et al. Polymerization- and solvent-induced phase separation in hydrophilic-rich dentin adhesive mimic. *Acta Biomater.* 2014;10(7):3038-47
5. Carrilho MR, et al. Mechanical stability of resin-dentin bond components. *Dent Mater.* 2005;21(3):232-41.

6. Dishman MV, Covey DA, Baughan LW. The effects of peroxide bleaching on composite to enamel bond strength. *Dent Mater* : official publication of the Academy of Dental Materials. 1994;10(1):33-6. Epub 1994/01/01.
7. Muraguchi K, Shigenobu S, Suzuki S, Tanaka T. Improvement of bonding to bleached bovine tooth surfaces by ascorbic acid treatment. *Dent Mater J*. 2007;26(6):875-81.
8. Bittencourt ME, et al. Influence of in situ postbleaching times on shear bond strength of resin-based composite restorations. *J Am Dent Assoc*. 2010;141(3):300-6.
9. Gokce B, et al. Effect of antioxidant treatment on bond strength of a luting resin to bleached enamel. *J Dent*. 2008;36(10):780-5.
10. Cvitko E, Denehy GE, Swift EJ, Jr., Pires JA. Bond strength of composite resin to enamel bleached with carbamide peroxide. *J Esthet Dent*. 1991;3(3):100-2.
11. Sasaki RT, Florio FM, Basting RT. Effect of 10% sodium ascorbate and 10% alpha-tocopherol in different formulations on the shear bond strength of enamel and dentin submitted to a home-use bleaching treatment. *Oper Dent*. 2009;34(6):746-52.
12. Barghi N, Godwin JM. Reducing the adverse effect of bleaching on composite-enamel bond. *J Esthet Dent*. 1994;6(4):157-61.
13. Kimyai S, Valizadeh H. The effect of hydrogel and solution of sodium ascorbate on bond strength in bleached enamel. *Oper Dent*. 2006;31(4):496-9.
14. Lai SC, Mak YF, Cheung GS, Osorio R, Toledano M, Carvalho RM, et al. Reversal of compromised bonding to oxidized etched dentin. *J Dent Res*. 2001;80(10):1919-24.
15. Sgura R, Taddeo F, Moura NC, Tapety CMC, Rodrigues Júnior EC, Medeiros IS. Effect of sodium ascorbate and ascorbic acid hydrogels on microleakage of composite restorations after an office bleaching protocol. *Clin Lab Res Den*. 2014;20(1):6.
16. Tostes BO, Mondelli RF, Lima-Arsati YB, Rodrigues JA, Costa LC. The effect of baking soda when applied to bleached enamel prior to restorative treatment. *Gen dent*. 2013;61(5):e5-9.
17. Barcellos DC, Batista GR, Silva MA, PleffkenPR, Rangel PM, Fernandes Jr VV, et al. Two-year clinical performance of self-etching adhesive systems in composite restorations of anterior teeth. *Oper Dent*. 2013;38:258-66.
18. Garcia E, Mena-Serrano A, Andrade AM, Reis A, Grande RHM, Loguercio AD. Immediate Bonding to Bleached Enamel Treated with 10% Sodium Ascorbate Gel: A Case Report with One-Year Follow-up. *Eur J Esthet Dent*. 2012;7:8.
19. Torres CRG, Koga AF, Borges AB. The effects of anti-oxidant agents as neutralizers of bleaching agents on enamel bond strength. *Braz J Oral*. 2006 Sci.5(16):6.

**Ana Flávia Sanches Borges
(Corresponding address)**

Bauru School of Dentistry, University of São Paulo.
Al. Octávio Pinheiro Brisola, 9-75 , Vila Universitária
17012-901 – Bauru – SP – Brazil
e-mail address: afborges@fob.usp.br

Date submitted: 2014 Aug 18

Accept submission: 2014 Oct 20