



Periapical tissue repair of dog teeth after intracanal administration of capsaicin 0.075%

Reparação tecidual periapical em dentes de cão após administração intracanal de capsaicina 0,075%

Nair Narumi Orita PAVAN¹, Marcos Sergio ENDO¹, Marina Viudes BRUDER², Angelo José PAVAN¹, Eduardo GROSSMANN³, Luzmarina HERNANDES¹, Roberto Kenji Nakamura CUMAN¹

1 – State University of Maringá – PR – Brazil.

2 – University of Maringá – PR – Brazil.

3 – Federal University of Rio Grande do Sul – RS – Brazil.

ABSTRACT

Objective: The aim of this study was make a descriptively evaluate the repair of the periapical region of dog teeth. **Material and Methods:** Thirty-six root canals were used, eighteen were filled with 0.075% capsaicin and calcium hydroxide (test paste) and the rest eighteen root canals were filled with calcium hydroxide (control group). Histological analyzes were performed to classify inflammation as absent, mild, moderate or severe. The analyses also classified the presence or absence of repair at 7, 14 and 30 days. **Results:** The use of 0.075% capsaicin did not modify the inflammatory response and repair when compared to control group. **Conclusion:** Our data suggests that test group with 0.075% capsaicin as intracanal administration could be indicated for tissue repair; furthermore other experiments should be carried out to evaluate possible clinical use of capsaicin for atypical odontalgia.

KEYWORDS

Repair; Inflammation; Periapical tissue; Capsaicin; Calcium hydroxide.

RESUMO

Objetivo: O objetivo deste estudo foi realizar uma avaliação descritiva sobre a reparação tecidual da região periapical de dentes de cães. **Material e Métodos:** Foram utilizados trinta e seis canais radiculares, sendo dezoito preenchidos com capsaicina 0,075% e hidróxido de cálcio (pasta teste) e os outros dezoito canais preenchidos com hidróxido de cálcio (grupo controle). As análises histológicas foram realizadas para classificar a inflamação como ausente, leve, moderada ou grave. As análises também classificaram a presença ou ausência da reparação tecidual nos períodos de 7, 14 e 30 dias. **Resultados:** O uso de capsaicina 0,075% não alterou a resposta inflamatória e reparação quando comparado ao grupo controle. **Conclusão:** Nossos dados sugerem que o grupo teste, o qual utilizou capsaicina 0,075% como pasta intracanal, pode ser indicado para reparação tecidual. Além disso, outros experimentos devem ser realizados para avaliar a possível utilização clínica da capsaicina para odontalgias atípicas.

PALAVRAS-CHAVE

Reparação; Inflamação; Tecido periapical; Capsaicina; Hidróxido de cálcio.

INTRODUCTION

Capsaicin is a compound derived from the chili pepper extract [1]. Repeated applications cause a prolonged period of hypoalgesia, which is generally referred to as desensitization. Therefore, Capsaicin has been

recommended as treatment for a variety of neuropathic pain syndromes [2].

The atypical odontalgia is a neuropathic pain characterized by discomfort in a tooth or in a site where extraction has been performed, with no clinical or radiographic signs related to disease [3].

There is no agreement on the most appropriate therapeutic protocol for treating neuropathic pain, once this condition is difficult to diagnose and well elaborated clinical control studies to assess the effectiveness of drugs for atypical odontalgias are lacking [4].

Several drugs have been used in the treatment of atypical odontalgias and tricyclic antidepressants stand out among them [5]. Besides, there is also an association with oral anticonvulsants [6], analgesics [7] and the use of topical capsaicin in mucosa [8]. However, capsaicin topically applied in mucosa promotes intense irritation, characterized by the burning sensation, which leads to treatment interruption. The intracanal route could be an alternative use of capsaicin without causing adverse effects.

There are few studies [9] showing inflammatory and repair effect of capsaicin in living tissue by intracanal via, thus knowledge of the irritating potential of any dental material for living tissue is essential, because any constituents present in these materials could induce degeneration, irritation or tissue necrosis [10].

Capsaicin, in this experiment, is in close contact with the periapical tissues, and the principal features of the effects of capsaicin on primary afferent neurons are excitation, desensitization, neurotoxicity and selectivity [2]. Our working hypothesis was that, although capsaicin takes an initial excitation, there is no exacerbate inflammatory response resulting from this technique.

Therefore, the aim of the present study was to histopathologically evaluate the periapical region of dogs teeth, following the application of 0.075% capsaicin paste, overfilled via canal. We performed a descriptive analysis of the inflammatory changes and subsequent repair, using the hematoxylin and eosin staining technique.

MATERIAL AND METHODS

Animals

All surgical and experimental procedures were approved by the Ethics in Animal Research Committee of the State University of Maringá and were in compliance with the Ethical Guidelines of Animal Experimentation.

For the experiment, 36 teeth of three beagle dogs were used. The experiment included central and lateral incisors, second and third upper premolars, and second, third, and fourth lower premolars.

Anesthesia

The animals were anesthetized intravenously with 0.03 mg/kg of 0.2% acepromazine and 3 µg/kg fentanyl citrate, and Ringer's lactate solution was administered to maintain venous access. Anesthesia was induced with intravenous 3 mg/kg propofol and 2 mg ketamine to 10% (8 mg/kg ketamine; Agener Union Chemical Pharmaceutical National, Brazil). Anesthesia was maintained with isoflurane, and 0.5% bupivacaine was used for local anesthetic block.

Endodontic procedure and Experimental groups

After the dogs had been anesthetized, and teeth received rubber dam isolation, pulp chamber was accessed with #1090 cylindrical diamond bur. The pulp tissue was extirpated and the instrumentation up to #50 K-files (Dentsply Maillefer Instruments SA, Ballaigues, Switzerland) using the crown-down technique was performed. Irrigation was made with 2.5% sodium hypochlorite. After that, the apical foramen was cross-sectioned with Gates Glidden n°1 (Dentsply Maillefer Instruments SA, Ballaigues, Switzerland). The confirmation was performed by means of radiography.

Smear layer was removed with EDTA for 3 minutes and after that, root canal was finally

irrigated with 2.5% sodium hypochlorite. Teeth were then separated into two groups.

Group I (control group; calcium hydroxide + propyleneglycol + topical anesthetics).

Group II (calcium hydroxide + propyleneglycol + topical anesthetics + 0.075% capsaicin).

Cavities were sealed with mineral trioxide aggregate - MTA (Angelus, Londrina, Brazil), Cimpat (Septodont, Barueri, Brazil), and composite resin (Charisma, Heraeus Kulze, São Paulo, Brazil).

The analyses were made at 7, 14 and 29 days after the material was introduced to root canals. Therefore, there were six teeth filled with calcium hydroxide + propyleneglycol + topical anesthetics and the remaining six teeth were filled with calcium hydroxide + propyleneglycol + topical anesthetics + 0.075% capsaicin for each evaluation period. Finally, the dogs were euthanized by overdose of anesthetics.

Material collected and Histology

The maxillary bones were cut, fixed in 10% formalin, and decalcified in sodium citrate and formic acid. Each tooth with sustentation tissue was then processed for embedding in paraffin. Sections (6 μ m) were cut and stained with hematoxylin and eosin.

Evaluation Methodology

Descriptive histological analysis was performed to classify inflammation as absent, mild, moderate, or severe [11]. It also classified the presence or absence of repair.

RESULTS

7 days

Analyzing the control group, in the root canals, a moderate inflammatory infiltrate in the periapical region, with predominance of neutrophils and macrophages (Figure 1A), was observed at 7 days. The surrounding area of root apex, which was previously occupied

by the alveolar bone, has been filled by richly vascularized loose connective tissue, providing blood supply responsible for phagocytic cell formation and transportation. Tissue repair began just after the elimination of aggressor agents and the rest of cell tissues [12]. Granules of calcium hydroxide were visualized inside macrophages and were dispersed within the loose connective tissue. The alveolar bone indicates a significant resorption, leaving only few bone trabeculae, where there were many osteoclasts (Figure 2A). Cementum resorption was also observed (Figure 3).

At the capsaicin 0.075% group (test paste), there were no significant differences in the findings. Alveolar bone has undergone significant resorption (Figure 2B) and this reabsorbed region was filled with loose connective tissue, with inflammatory infiltration. In areas closer to overfilled paste, there was moderate inflammation. In more distant areas, the inflammation was classified as intense with predominance of macrophages (Figure 1B). Roots showed superficial cementum resorption, similarly in the control group.

14 days

At 14 days, the positive control morphology of periradicular region was similar to that observed at 7 days, except for a reduced number of osteoclasts (Figure 1C).

For the test paste, the morphology of periradicular region was not different, although at distant regions from the defect, blood vessels and fibroblasts with active morphology and irregular deposition of collagen are visualized. At this point in time, the tissue repair is beginning and a the presence of fibrosis tissue is visualized (Figure 4). The inflammatory response was moderate to intense (Figure 1D).

30 days

At 30 days, the control group presented inflammatory process, which was classified as moderate. It was circumscribed by a fibrous tissue

that partially replaced the loose connective tissue (Figure 1E). Hydroxyapatite granules could be detected inside the vessels and macrophages (Figure 5). During this period, we observed the presence of cementum resorption and a significant reduction in number of osteoclasts at the trabecular bone surface (Figure 6).

The test paste has shown that at the region immediately after the overfilled material, that loose connective tissue was replaced by dense connective tissue, which circumscribed the inflammatory infiltrate and was classified as mild (Figure 1F). Cementum resorption remained superficial (Figure 7).

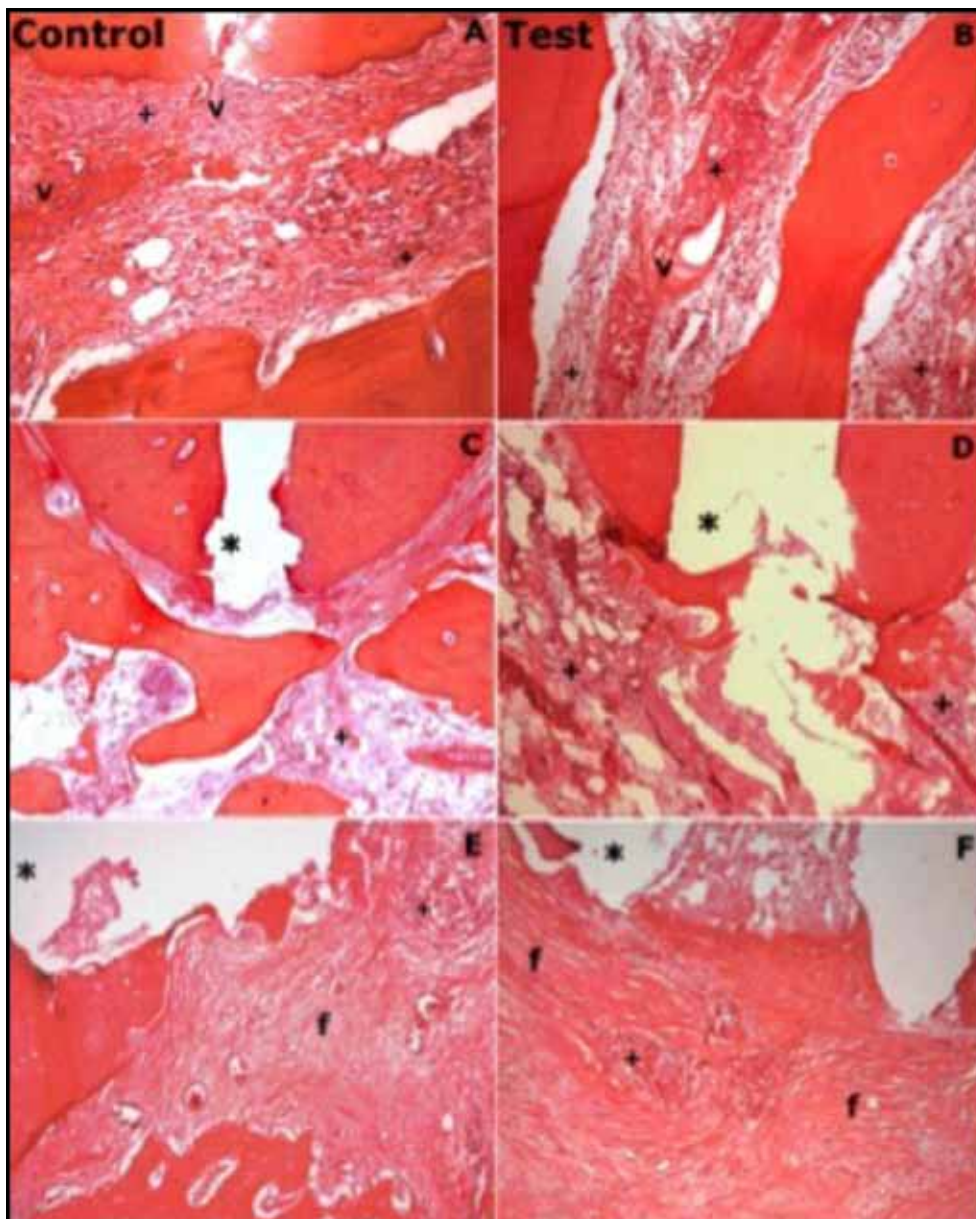


Figure 1 - Histological observation of tooth sections. (A) Control group at 7 days. Moderate inflammation. (B) 7 days after application of 0.075% capsaicin (10x magnification, H-E staining). Moderate to intense inflammation. (C) Control group at 14 days. Moderate inflammation. (D) 14 days after application of 0.075% capsaicin. Moderate to intense inflammation (4x magnification, H-E staining). (E) Control group at 30 days. Fibrous tissue. (F) 14 days after application of 0.075% capsaicin. Fibrous tissue. Appically to instrumentation (*), fibrosis area (f), inflammation (U), vessels (v) (10x magnification, H-E staining).

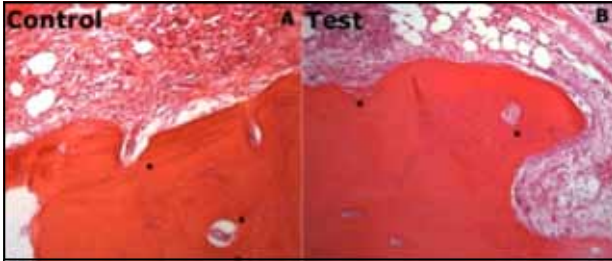


Figure 2 - Histological observations of bone resorption (star). (A) Control group at 7 days. (B) 7 days after application of 0.075% capsaicin (10x magnification, H-E staining).

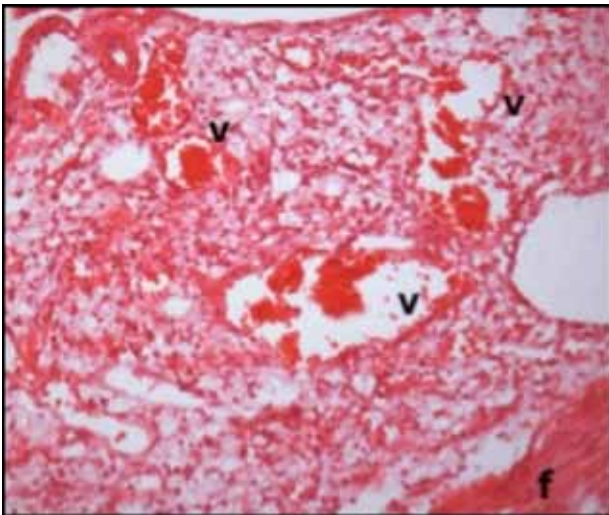


Figure 4 - Test tooth section after 14 days, showing vessels (v) and fibrosis (f) (20x magnification, H-E staining).

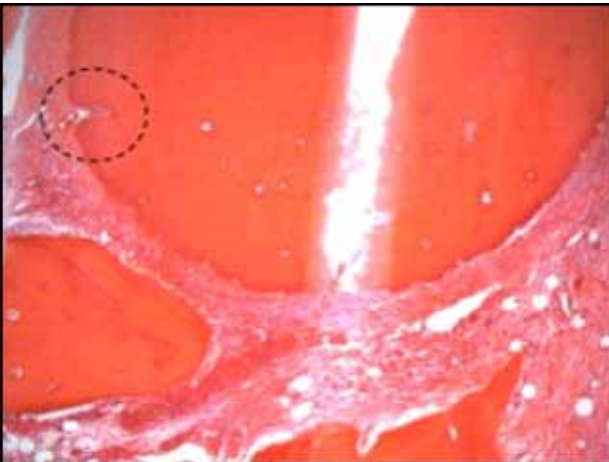


Figure 3 - Control tooth section after 7 days, cementum resorption (circle) (4x magnification, H-E staining).

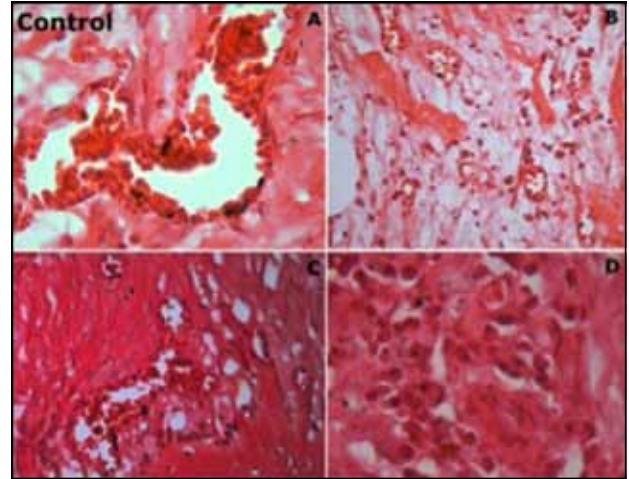


Figure 5 - After 30 days of root canal filling, showing hydroxyapatite granules inside the vessels and macrophages, respectively (A and C) (100x magnification, H-E staining) and 0.075% capsaicin (B and D) (40x and 100 magnification respectively, H-E staining).

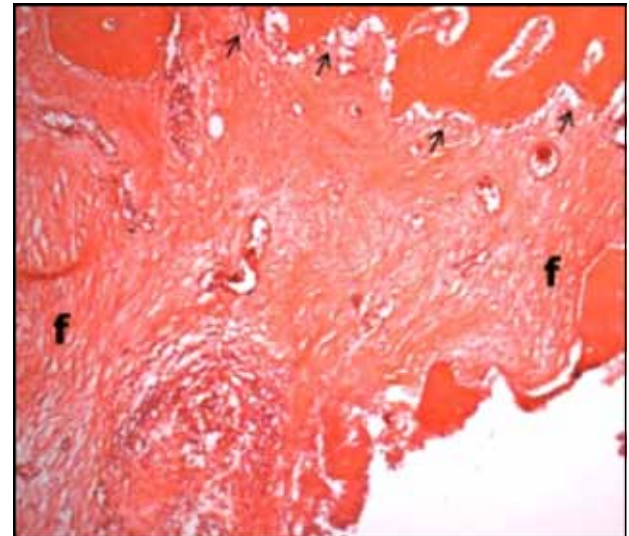


Figure 6 - Control section after 30 days, showing fibrosis (f) and osteoblasts (arrow) instead osteoclasts (4x magnification, H-E staining).

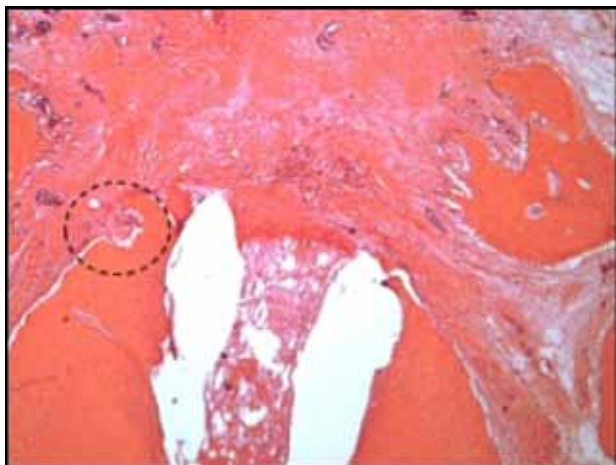


Figure 7 - Test tooth section after 30 days, showing cementum resorption (circle) (4x magnification, H-E staining).

DISCUSSION

In subchronic inflammation, the exudate is gradually resorbed and the neutrophilic infiltrate is replaced by mononuclear leukocytes with macrophages predominance, and these histological events could be observed in this experiment at 7 and 14 days.

During these periods, in the 0.075% capsaicin group, the inflammatory response was classified as moderate with predominance of polymorphonuclear cells, and at 30 days the inflammatory infiltrate was regarded as mild, indicating the evolution of the inflammatory process to its resolution. (Figure 1E)

The inflammation of the test group has demonstrated similarity to the control group, evidencing that capsaicin does not intensify the damaged tissue. This is probably due to desensibilization induced by capsaicin which led to changes in the release of substance P, neurokinin A, Calcitonin gene-related peptide (CGRP) and other neurotransmitters [13].

Therefore, the inflammatory response seen in the three periods was due to overinstrumentation of the apex, procedure that was performed to promote contact of the material with periapical region, and also to promote contact with calcium hydroxide [14], present in both groups.

This tissue damage induces cytokines release, growth factors and arachidonic acid products [12], which also participated in the initiation and maintenance of vascular phenomena, especially as the aggression found in our study that has been classified as mild to moderate.

The central mechanism for connective tissue repair is inflammation, and repair can be considered the last event of inflammatory response.

Repair of the 0.075% capsaicin group was similar to the control group. At 14 days, morphologically active fibroblasts could be noticed in areas more distant from defects (Figure 4), demonstrating the beginning of repairing process, and also the presence of blood vessels (Figure 4) important for the repair, since neovascularization resulting from the surgical site is an essential event [15].

At 30 days, at the periapical region immediately around the overflowed material, a wide area of dense connective tissue circumscribing the mild inflammatory infiltrate is observed (Figure 1E and 1F).

Capsaicin in this experiment has not affected the speed or quality of repair when compared to control group, therefore it is not a modifying factor in the repair process.

However, there are studies indicating reduction in the healing degree of the peripheral tissue when in contact with capsaicin, besides the increasing rate of the dental pulp necrosis [16]. Perhaps, these effects occur because capsaicin depends on the exposure time, its formulation and certainly its concentration, because capsaicin is dose-dependent [17].

Results obtained in this experiment are in agreement with the findings of another study [9], where the intracanal route has also been used in dog teeth, although capsaicin was used with concentration at 0.025% and 0.05%.

Intracanal administration of 0.075% capsaicin in dog teeth did not show histological changes in inflammatory events and repair at the

periapical region in comparison to the control group. (Figure 1)

Our data suggests that paste with 0.075% Capsaicin used as intracanal administration could be indicated to repair; furthermore other experiments should be carried out to evaluate the possible clinical use of capsaicin for atypical odontalgias.

ETHICAL APPROVAL

Ethics in Animal Research Committee of the State University of Maringá in compliance with the Ethical Guidelines of Animal Experimentation.

Number N. 013/2011-CEEA/UEM

REFERENCES

- McCleane G. Topical analgesics. *Anesthesiol Clin*. 2007;25(4):825-39, vii.
- Nolano M, Simone D A, Wendelschafer-Crabbe G, Johnson T, Hazenc E, Kennedy WR. Topical capsaicin in humans: parallel loss of epidermal nerve fibers and pain sensation. *Pain*. 1999;81(1-2):135-145.
- Melis M, Secci S. Diagnosis and treatment of atypical odontalgia: a review of the literature and two case reports. *J Contemp Dent Pract*. 2007;8(3):81-9.
- Chong MS, Bajwa ZH. Diagnosis and treatment of neurophatic pain. *J Pain Symptom Manage*. 2003;25(5 Suppl):S4-S11.
- Macdonald AD, Woolfe G, Bergel F, Morrisin AL, Rinderknecht H. Analgesic action of pethidine and related compounds. *Br J Pharmacol Chemother*. 1946;1:4-14.
- Okeson JP, Falace DA. Nonodontogenic toothache. *Dent Clin North Am*. 1997;41(2):367-83.
- Wirz S, Ellerkmann RK, Buecheler M, Putensen C, Nadstawek J, Wartenberg HC. Management of chronic orofacial pain: a survey of general dentists in German university hospitals. *Pain Med*. 2010;11(3):416-24.
- Durso BC, Cunha KSG, Napolitano WC, Janini MER, Cardoso AS. Dor por desferentação: protocolo terapêutico. *J. B. A. ATM e Dor Orofacial* 2001;1:130-3.
- Pavan NNO, Bruder MV, Amado CAB, Grossmann E, Hernandez LM, Cuman RKN. Effect of intracanal administration of association between calcium hydroxide paste and capsaicin in the periapical region of dog's teeth. *J Med Plant Res*. 2013;7(9):496-503.
- Huang TH, Yang CC, Ding SJ, Yan M, Chou MY, Kao CT. Biocompatibility of human osteosarcoma cells to root-end filling materials. *J Biomed Mater Res*. 2005;72(1):140-5.
- Holland R, Mazuqueli L, De Souza V, Murata SS, Dezan Júnior E, Suzuki P. Influence of the type of vehicle and limit of obturation on apical and periapical tissue response in dogs' teeth after root canal filling with mineral trioxide aggregate. *J Endod*. 2007;33(6):693-7.
- Consolaro A. Inflamação e reparo: um sílabo para a compreensão clínica e implicações terapêuticas. Maringá: Dental Press; 2009. p.269-88.
- Chancellor MB, de Groat WC. Intravesical capsaicin and resiniferatoxin therapy: spicing up the ways to treat the overactive bladder. *J Urol*. 1999;162(1):3-11.
- Pallotta RC, Machado MEL, Reis NS, Martins GHR, Nabeshima CK. Tissue inflammatory response to implantation of calcium hydroxide and iodoform in the back of rats. *Rev Odonto Cienc*. 2010;25(1):59-64.
- Ziche M, Morbidelli L, Pacini M, Geppetti P, Alessandri F, Magge CA. Substance P stimulates neovascularization in vivo and proliferation of cultured endothelial cells. *Microvasc Res*. 1990;40(2):264-78.
- Byers MR, Närhi MV. Dental injury models: Experimental tools for understanding neuroinflammatory interactions and polymodal nociceptor functions. *Crit Rev Oral Biol Med*. 1999;10(1):4-39.
- Holzer P. Capsaicin: cellular targets, mechanisms of actions, and selectivity for sensory neurons. *Pharmacol Rev*. 1991;43(2):143-201.

Marcos Sergio Endo (Corresponding address)

UEM – Universidade Estadual de Maringá
Av. Colombo, 5.790 - Jd. Universitário - Maringá -
Paraná – Brasil
Zipcode: 87020-900

Date submitted: 2014 Nov 10

Accept submission: 2014 Mar 24