

Cone-Beam Computed Tomography analysis of prevalence of Nasal Septum Deviation and its relationship with the presence of Middle Concha Bullosa

Avaliação da prevalência e relação entre o desvio de septo nasal e a presença de concha média bolhosa por meio de tomografia computadorizada de feixe cônico

Sérgio Lúcio Pereira de Castro LOPES¹, Mari Eli Leonelli de MORAES¹, Luiz Roberto Coutinho MANHÃES JUNIOR¹, Thiago de Oliveira GAMBA², Isadora Luana FLORES³, Carolina Fernandes de FARIA⁴, Afonso Celso ASSIS⁴

1 – Department of Diagnosis and Surgery – School of Dentistry – Institute of Science and Technology – UNESP – Univ Estadual Paulista – São José dos Campos – SP – Brazil.

2 – Department of Oral Diagnosis – Piracicaba Dental School – UNICAMP – Piracicaba – São Paulo – Brazil.

3 – Department of Semiology and Clinics – Post-graduate Program in Dentistry – Pelotas Dental School – UFPel – Pelotas – Rio Grande do Sul – Brazil.

4 – School of Dentistry – Institute of Science and Technology – UNESP – Univ Estadual Paulista – São José dos Campos – SP – Brazil.

ABSTRACT

Objective: This study aimed to analyze the prevalence of nasal septum deviation and the presence of middle nasal concha bullosa, as well as to study the possible relationship between these findings by means of cone-beam computed tomography (CBCT) images. **Material and Methods:** One hundred and eighteen CBCT exams were selected from a file previously acquired for diverse reasons in dentistry. All images were obtained with CT i-CAT Next Generation (Imaging Sciences International, Hatfield, PA, USA) with the same protocol, and the field of view (FOV) covered the middle and lower third of the face. All images were evaluated in the specific software system by one trained evaluator. The deviated septum, nasal concha bullosa, and other data were tabulated and a descriptive analysis was performed. The McNemar test was used to study the possible relationship between them. **Results:** The results indicated that, in cases without nasal septum deviation, 26.5% and 73.5% were associated or not to the presence of middle concha bullosa, respectively. Considering patients with nasal septum deviation on one side only, the proportions of 22.9% and 77.1% were associated or not to middle concha bullosa in the same direction, respectively. **Conclusion:** Thus, it was concluded there was no relationship ($p =$

RESUMO

Objetivo: Este estudo teve com objetivo analisar a prevalência do desvio do septo nasal e da presença de concha nasal média bolhosa e estudar a possível relação entre estes por meio de imagens por tomografia computadorizada de feixes cônicos (TCFC). **Material e Métodos:** Foram selecionados 118 exames de TCFC de arquivo, previamente adquiridos por indicações diversas para odontologia. Todos os exames foram realizados em tomógrafo i-CAT Next Generation (imaging Sciences International, Hatfield, PA, EUA) com o mesmo protocolo, tendo o FOV (Field of View) abrangendo o terço médio e inferior da face. Todas as imagens foram avaliadas no software específico do sistema por 01 avaliador devidamente treinado. O desvio de septo nasal, a concha nasal média bolhosa e demais dados foram tabulados e realizada a análise descritiva dos mesmos. O teste de McNemar foi aplicado para se estudar a possível relação entre os mesmos. **Resultados:** Os resultados indicaram que, nos casos em que não ocorria o desvio de septo nasal, 73,5% destes não apresentaram e 26,5% destes apresentaram a concha média bolhosa. Considerando-se apenas os casos que apresentaram o desvio de septo nasal para um dos lados, a proporção que não apresentou a concha média bolhosa para o mesmo lado foi de 77,1% e a que apresentou também a concha média bolhosa para o mesmo lado foi de 22,9%. **Conclusão:** Concluiu-se que não houve relação ($p = 0,568$) entre a presença das duas

0.568) between nasal septum deviation and the presence of middle concha bullosa.

KEYWORDS

Nasal cavity; Nasal septum, abnormalities; Turbinates; Cone-beam computed tomography.

variáveis analisadas na pesquisa – desvio de septo nasal e presença de concha média bolhosa.

PALAVRAS-CHAVE

Cavidade nasal; Septo Nasal, anormalidades; Conchas Nasais; Tomografia Computadorizada de Feixe Cônico.

INTRODUCTION

The evaluation of paranasal sinuses and nasal fossa is highlighted among the various current indications of computed tomography (CT) scans. This type of image analysis is the choice regarding the study of these structures, identifying them accurately and with great anatomical details. Some anatomical variations may predispose one to sinusitis and constitute high-risk areas for injuries and complications during surgical procedures [1]. Cone-beam computed tomography (CBCT) is a method first introduced in Italy in 1997 [1] and has been used commercially since 2001 in the USA [2]. Among its advantages are lower radiation dose compared to fan-beam computed tomography (CT), used in medical tomography, and its high spatial resolution of bone tissue, which makes it a widely used method in dental practice [2-4].

The prevalence of nasal septum deviation varies with age; being a septal deformity. It is one of the main causes of nasal obstruction and feeding difficulty in childhood, and it may also cause blockage of the nasolacrimal ducts, rhinosinusitis, recurrent otitis media, and mouth-breathing sequelae [5,6].

Recent literature defines middle concha bullosa as the presence of any degree of pneumatization of this anatomic structure. This variation is best viewed in CT scans. Hypothetically, the middle concha bullosa can increase the volume of the corresponding nasal turbinate, resulting in deviation of the nasal septum to the contralateral side, with consequent

problems as a result [7]. The literature relating to deviation of the nasal septum and the presence of concha bullosa is scarce; in addition, the few studies conducted for this purpose have been performed using CT images, not CBCT.

This study aimed to use the CBCT images to identify the presence of septal deviation and concha bullosa, as well as to study their prevalence and the possible relationship between them.

MATERIALS AND METHODS

This study was carried out after approval by the Research Ethics Committee at Julio de Mesquita Filho State University (protocol number 754.631 in 08/15/2014).

We evaluated 118 CBCT scans belonging to the clinical file of Radiology, Julio de Mesquita Filho State University–ICT UNESP. CBCT images were acquired with i-CAT Next Generation Tomography (Imaging Sciences International, Hatfield, PA, USA) for various indications, such as planning implant placement and orthodontic planning. The tests included in the sample were acquired with a field of view (FOV) measuring 16.0 x 13.0 cm and 0.25-mm voxel and entirely covering the nasal cavities. The images were obtained from patients aged between 10 and 80 years, of both sexes, and excluded those in which the nasal passages (lower and middle thirds) were not displayed. All tests were evaluated in the original format of image acquisition on a 19-inch LCD monitor with the XORAM software (Xoran Technologies LLC, Ann Arbor, MI, USA). Their evaluations were performed on a cutting

window with multi-planar reconstruction (MPR) software, according to the following protocol:

1) Evaluation of nasal septum deviation

First, we assessed the sagittal plane of the image, according to the nasal septum deviation symmetry, based on axial reconstruction. The mid-guideline on sagittal reconstruction was positioned in the axial mid-sagittal plane and, when necessary, the axial image was moved until the sagittal plane of the patient and the guideline

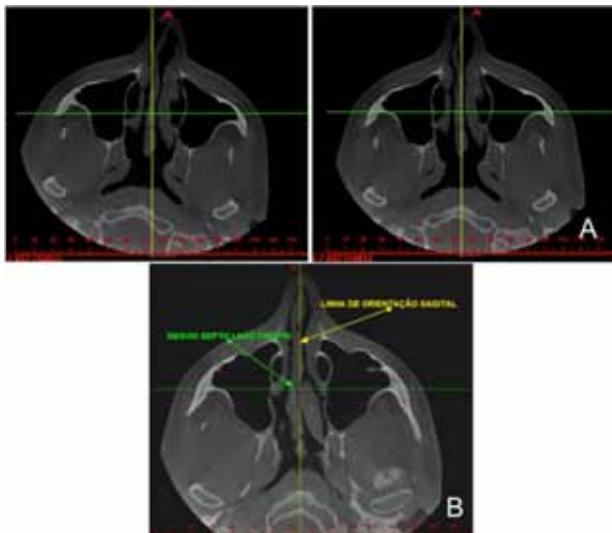


Figure 1 - CBCT axial slices showing: (a) previous alignment of the image to the sagittal plane (in yellow); (b) nasal septum deviation to the right side.

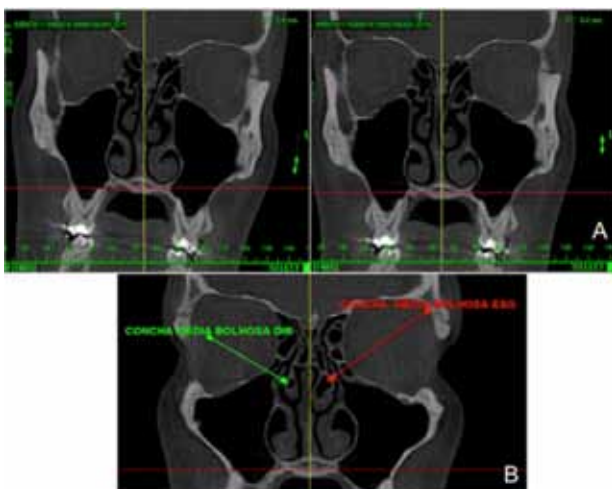


Figure 2 - CBCT coronal slice showing: (a) previous alignment of the image to the occlusal plane (in red); (b) bilateral middle concha bullosa.

reference lined up (Figure 1A). After performing the adjustment of the sagittal plane, the presence or absence of nasal septum deviation in the axial view was assessed, as well as the side of deviation if present (Figure 1B).

2) Assessment of the presence of middle concha bullosa

Further, we evaluated the coronal images, after the adjustment of the occlusal plane, considering the bony palate parallel to the horizontal plane, which was represented by the corresponding guideline to the axial plane (Figure 2A). We performed the taking of the occlusal plane in the coronal image, looking for the presence or absence of middle concha bullosa, represented by a hypodense image within one or both middle nasal concha (Figure 2B).

RESULTS

The frequency of the sample according to its distribution in relation to gender and age groups is highlighted in Table 1. Frequency of nasal septal deviation and the distribution according to the side are shown in Table 2. The frequency of middle concha bullosa and the uni- or bilateral involvement are shown in Table 3. The frequency of the occurrence of the side of the middle concha bullosa is shown in Table 4.

Table 1 - Frequency distribution of subjects according to gender and age

Sex	Number of Individuals	Percentage (%)
Female	78	66.1
Male	40	33.9
Total	118	100
Age Range*	Number of Individuals	Percentage (%)
10–20 years	11	9.34
21–30 years	16	13.5
31–40 years	26	22.03
41–50 years	23	19.5
51–60 years	25	21.2
61–70 years	12	10.2
71–80 years	5	4.23
Total	119	100

* mean age = 42 years

Table 2 - Frequency of nasal septum deviation and the distribution, if present, according to the side (right or left)

Nasal Septum Deviation	Frequency	Percentage (%)
Presence	71	60.17
Absence	47	38.83
Total	118	100
Side of Nasal Septum Deviation	Frequency	Percentage (%)
Right	35	49.3
Left	36	50.7
Total	71	100

Table 3 - Frequency of middle concha bullosa and their distribution (unilateral or bilateral)

Middle Concha Bullosa	Frequency	Percentage (%)
Presence	62	52.55
Absence	56	47.45
Total	118	100
Middle Concha Bullosa	Frequency	Percentage (%)
Unilateral	41	66.12
Bilateral	21	33.88
Total	62	100

Table 4 - Frequency of middle concha bullosa considering the side of occurrence

Middle Concha Bullosa	Frequency	Percentage (%)
Right	30	48.38
Left	32	51.62
Total	62	100

In order to study the possible relation between the presence of middle concha bullosa and the presence of nasal septum deviation, we applied McNemar statistical paired test considering separately the side occurrence (right or left). The test was performed using the SPSS software (IBM, Armonk, NY).

The proportions with presence or not of middle concha bullosa in the same direction were 22.9% and 77.1%, respectively, considering only the cases with nasal septum deviation to one side (left or right).

There was no relationship between presence of nasal septum deviation and middle concha bullosa according to McNemar test, chi-square value (0.568).

DISCUSSION

Some authors [8] emphasize nasal septum deviation is a common clinical finding in otolaryngology and head and neck surgery; it presents as a deviation from the midline associated with deformities or asymmetry of the adjacent concha or the structure of nasal walls, presenting in various ways in the population. Studies show CT is the modality of choice for the evaluation of nasal and paranasal sinuses, as with it we can identify anatomical variations accurately with anatomical detail. The importance of identification is related predisposition to developing sinusitis as well as injuries and complications during endoscopic surgery [9].

The middle nasal concha bullosa, originating from variation in pneumatization of the bone plate caused by extension of ethmoid cells, can be unilateral or bilateral. The degree of pneumatization varies and may cause obstruction of the middle meatus or infundibulum [9].

Based on the increase in requests for this type of examination by the dental field, this study used CBCT images with several indications to evaluate the prevalence of nasal septum deviation and middle concha bullosa and any possible relationship between the two.

In this study, the majority (66.1%) of the sample individuals were female, unlike other studies on nasal septum deviation [10-14], where the prevalence of males was higher than females. This preponderance in studies with same aim can be explained by the fact that one of the most common causes of nasal septum deviation is trauma to the nose, which occurs mostly in males [15]. In our study, however, the sample consisted of examinations with CBCT indications for implant and prosthetic treatment,

usually common types of intervention in females related to the aesthetic factor. The most common age group included was aged 31–40 years (22.03%), followed by those aged 51–60 years (21.2%), with an average age of 42 years. Our study corroborates with respect to mean age the findings of other authors [10], who analyzed 137 patients for the presence of septal deviation and also found an average of 42 years. However, our results differ in regard to the mean age found in other studies [11], which have found the presence of septal deviation in patients with an average age lower than ours (between 32 and 36 years). One explanation for this difference could be the fact that patients from those studies were selected based on the presence of signs and symptoms related to rhinopathies, and a higher incidence of these changes affects the fourth decade of life. In contrast, in our study, the selected sample belonged to CBCT image files that were acquired for different purposes, among which prevailed the planning of dental implants placement, which justifies a greater number of tests in the age group between the fifth and seventh decades of life .

Deviation of the nasal septum was found in 60.17% of the sample, and there was no significant predilection of it to the right or left side, as has been observed in other studies [10-14].

More than half (52.25%) of scans showed the presence of middle concha bullosa in this study. The middle nasal concha bullosa corresponds to the most common anatomic variation of the ostiomeatal complex and is usually visualized affecting the middle nasal turbinate (incidence of 13–53.6%), being rare in the upper turbinate and even rarer in the inferior turbinate, with just one reported case in the literature [16-18]. Previous studies have reported the incidence of bilateral concha ranges from 45.0% to 61.5% [18-20]. In our study, it was observed presence of middle concha bullosa in 52.25%, being the majority (66.12%) presented in one side, which differs from the findings described in previous studies [18-20].

Among the few studies associating the presence of middle concha bullosa with the presence of nasal septal deviation, one found a high relationship between the presence of middle concha bullosa and a deviated septum to the contralateral side [20]. In our study, we found the opposite result with no relationship between these variables ($p = 0.568$). When considering only cases nasal septum deviation, the proportion not associated with middle concha bullosa at the same side was 77.1%, and association with concha bullosa in the same direction was present in 22.9% of cases. We emphasize that in other study [20], the sample inclusion criteria incorporated the presence of septal deviation and complaints of nasal obstruction. Our research, by contrast, did not have access to patient data, only the CBCT images, gender, and age were available. Thus, in our sample we found individuals with and without nasal septum deviation. Our results are in concordance with other study [20] with regard to the fact that nasal septum deviation did not favor the formation of middle concha bullosa. However, we emphasize that the degree of middle turbinate pneumatization was not considered in this study.

A study on the incidence of bullous turbinate [21] noted there was a greater tendency for this to develop bilaterally in patients with no nasal septum deviation. Moreover, unilateral middle nasal concha bullosa occurred in cases of septal deviation that presented, more frequently, on the contralateral side. These aspects suggest nasal septum deviation would be a factor in preventing the occurrence of middle concha bullosa for the ipsilateral side. In our study, the absence of septum deviation also seemed to correspond to the absence of concha bullosa, where 73% of the sample that showed deviation did not show concha bullosa, without, however a statistical relationship between them.

CONCLUSION

Considering the results obtained in this study, it can be concluded that most of the

sample subjects showed nasal septum deviation and middle concha bullosa, with the latter being unilateral in the majority. There was no significant prevalence in the side of occurrence for either the deviated septum or the middle concha bullosa. There was also no correlation between nasal septum deviation and the presence of middle concha bullosa.

REFERENCES

- Mozzo P, Procacci C, Tacconi A, Martini PT, Andreis IA. A new volumetric CT machine for dental imaging based on the cone-beam technique: preliminary results. *Eur Radiol*. 1998;8(9):1558-64.
- Scarfe WC, Farman AG, Sukovic P. Clinical applications of cone-beam computed tomography in dental practice. *J Can Dent Assoc*. 2006 Feb;72(1):75-80.
- Pette GA, Norkin FJ, Ganeles J, Hardigan P, Lask E, Zfaz S, et al. Incidental findings from a retrospective study of 318 cone beam computed tomography consultation reports. *Int J Oral Maxillofac Implants*. 2012 May-Jun;27(3):595-603.
- Pliska B, DeRoche M, Larson BE. Incidence of significant findings on CBCT scans of an orthodontic patient population. *Northwest Dent*. 2011 Mar-Apr;90(2):12-6.
- Scarfe WC, Farman AG, Sukovic P. Clinical applications of cone-beam computed tomography in dental practice. *J Can Dent Assoc*. 2006 Feb;72(1):75-80.
- Maniglia JV, Molina, FD, Maniglia LP, Maniglia CP. Rinossepto-plastia em crianças. *Rev Bras Otorrinolaringol*. 2002;68(3):320-3.
- Kinsui MM, Guilherme A, Yamashita HK. Variações anatômicas e sinusopatias: estudo por tomografia computadorizada. *Rev Bras Otorrinolaringol*. 2002;68(5):645-52.
- Aziz T, Biron VL, Ansari K, Flores-Mir C. Measurement tools for the diagnosis of nasal septal deviation: a systematic review. *J Otolaryngol Head Neck Surg*. 2014 Apr 24;43:11.
- Miranda CMNR, Maranhão CPM, Arraes FMNR, Padilha IG, Farias LPG, Jatobá MSA, et al. Variações anatômicas das cavidades paranasais à tomografia computadorizada multislice. *Radiol Bras*. 2011 Jul/Ago;44(4):256-62.
- Sedaghat AR, Busaba NY, Cunningham MJ, Kieff D. Clinical assessment is an accurate predictor of which patients will need septoplasty. *Laryngoscope*. 2013 Jan;123(1):48-52.
- Lin JK, Wheatley FC, Handwerker J, Harris NJ, Wong BJ. Analyzing nasal septal deviations to develop a new classification system: a computed tomography study using MATLAB and OsiriX. *JAMA Facial Plast Surg*. 2014 May-Jun;16(3):183-7.
- Mamikoglu B, Houser S, Akbar I, Ng B, Corey JP. Acoustic rhinometry and computed tomography scans for the diagnosis of nasal septal deviation, with clinical correlation. *Otolaryngol Head Neck Surg*. 2000 Jul;123(1 Pt 1):61-8.
- Tahamiler R, Canakcioglu S, Yilmaz S, Dirican A. Expiratory nasal sound analysis as a new method for evaluation of nasal obstruction in patients with nasal septal deviation: comparison of expiratory nasal sounds from both deviated and normal nasal cavity. *J Laryngol Otol*. 2008 Feb;122(2):150-4.
- Szücs E, Clement PA. Acoustic rhinometry and rhinomanometry in the evaluation of nasal patency of patients with nasal septal deviation. *Am J Rhinol*. 1998 Sep-Oct;12(5):345-52.
- Oliveira AKP, Júnior EE, Santos LV, Bettge G, Mocellin M. Prevalence of deviated nasal septum in Curitiba, Brazil. *Int Arch Otorhinolaryngol*. 2005;9(4):288-92.
- Onerci M. Endoskopik sinus cerrahisi. *Boyun Cerrahisi*. 1996;4(3):9-21.
- Doğru H, Döner F, Uygur K, Gedikli O, Cetin M. Pneumatized inferior turbinate. *Am J Otolaryngol*. 1999 Mar-Apr;20(2):139-41.
- Unlü HH, Akyar S, Caylan R, Naçça Y. Concha bullosa. *J Otolaryngol*. 1994 Feb;23(1):23-7.
- Calhoun KH, Waggenspack GA, Simpson CB, Hokanson JA, Bailey BJ. CT evaluation of the paranasal sinuses in symptomatic and asymptomatic populations. *Otolaryngol Head Neck Surg*. 1991 Apr;104(4):480-3.
- Uygur K, Tüz M, Doğru H. The correlation between septal deviation and concha bullosa. *Otolaryngol Head Neck Surg*. 2003 Jul;129(1):33-6.
- Yiğit O, Acioglu E, Cakir ZA, Sişman AS, Barut AY. Concha bullosa and septal deviation. *Eur Arch Otorhinolaryngol*. 2010 Sep;267(9):1397-401.

Sérgio Lúcio Pereira de Castro Lopes (Corresponding address)

Av. Eng. Francisco José Longo, nº 777, Jardim São Dimas
12245-000 - São José dos Campos, SP
sergioluciolopes@gmail.com

Date submitted: 2014 Dec 09

Accept submission: 2015 May 11