

## CASE REPORT

## Decoronation as an alternative procedure for dental ankylosis after dental reimplantation due to trauma in a growing child: case report

Decoronação como procedimento alternativo para anquilose dentária após reimplante dental devido a trauma em crianças em crescimento: relato de caso.

Pedro DINIZ-REBOUÇAS<sup>1</sup>, Adriana Kelly de Sousa SANTIAGO<sup>2</sup>, Juliana Oliveira GONDIM<sup>2</sup>, José Jeová Siebra MOREIRA NETO<sup>2</sup>

1 – Piracicaba Dental School – Campinas University – Piracicaba – SP – Brazil.

2 - Faculty of Pharmacy – Dentistry and Nursing – Ceara Federal University – Fortaleza – CE – Brazil.

### ABSTRACT

Dental ankylosis occurs by fusion of the root surface with the alveolar bone due to necrosis of the periodontal ligament. Although there is not a known treatment for dentoalveolar ankylosis, there are alternative procedures that may be realized as a way to prevent serious consequences. Decoronation is a procedure which the crown of the ankylosed tooth is surgically removed below the cemento-enamel junction and the root is buried. Our aim is to report the case of patient LSM, female, 8 years-old, who came to the Oral Dental Trauma Center of Federal University of Ceará after colliding against a wall. Avulsion of the dental element 21 occurred and the tooth was stored in milk. The reimplantation occurred one hour after the injury. After two years of the dental trauma, the treatment performed was decoronation and installation of an aesthetic and functional space maintainer. This case report presents a clinical and radiographic follow-up of 6 months and 3 years. In the 6-month evaluation, the buried root showed signs of resorption, but without bone loss, the aesthetic space maintainer was still well adapted and the alveolar ridge have no signals of gingival or bony issues. After three years, radiographic evaluation showed complete root resorption and signs bone formation in root previous site. Decoronation is a procedure that aim to maintain the alveolar bone ridge width, height and continuity and may be indicated to dental ankylosis, being a successful procedure in the reported case, allowing the patient to maintain the aesthetic, function and preserve the alveolar process to a future reahabilitation.

### KEYWORDS

Tooth Ankylosis, Tooth avulsion; Tooth injuries.

### RESUMO

A anquilose dentária ocorre por meio da fusão de superfície da raiz com o osso alveolar, devido à necrose do ligamento periodontal. Trauma local, infecção periapical, desordens endócrinas e metabólicas, esforço mastigatório excessivo, falta de força eruptiva do sucessor permanente e alterações genéticas são alguns dos fatores que podem levar a anquilose. Embora não haja um tratamento conhecido para anquilose dentoalveolar, existem procedimentos alternativos, tais como manter o dente anquilosado ou sua raiz, extração seguida de fechamento ortodôntico, autotransplante, implante, osteotomia da unidade dento-óssea ou decoronação. A decoronação é um procedimento em que a coroa do dente anquilosado é removido cirurgicamente abaixo da junção cemento-esmalte e a raiz é sepultada. Após o procedimento, mantenedor de espaço estético-funcional é instalado para evitar a perda de espaço até a oportunidade de proporcionar um tratamento de reabilitação definitiva. Nosso objetivo é relatar o caso de paciente LSM, fêmea, 8 anos de idade, que se apresentou para o Centro de Trauma Bucodentário da Universidade Federal do Ceará após colidir contra uma parede. Avulsão do elemento dentário 21 ocorreu e o dente foi armazenado em leite. O reimplante ocorreu uma hora após a injúria. O tratamento realizado foi decoronação e instalação de um mantenedor de espaço estético e funcional. Este relato de caso apresenta um acompanhamento clínico de 6 meses e 3 anos de acompanhamento radiográfico.

### PALAVRAS-CHAVE

Anquilose dental; Avulsão dentária; Traumatismos dentários

## INTRODUCTION

Traumatic injuries are quite common in young people, especially among children between 8-11 years [1-4]. Among the facial injuries, which occur frequently and represent about 5 % of cases of people seeking treatment, increasing to 18% in preschool [1,5], dental are the most prevalent [5], but avulsion prevalence surrounds about 0.5-18.3 % of all dental injuries [6,7].

Avulsion is a traumatic injury which can cause serious complications [4] and is defined as the complete separation of a tooth of its socket occurring disruption of the periodontal ligament fibers, a part of them remain adhered to the cement tooth and the other part to the alveolar bone [8], thus compromising dental pulp, periodontal ligament and alveolar bone [9]. If the root surface suffers an injury of low intensity and the inflammatory stimulus is only transitory, the prognosis is favorable, with a new formation of cementum and periodontal ligament, but if the injury is of high intensity, which usually occurs in cases of avulsion the alveolar bone can undergo replacement resorption or ankylosis [10]. The etiology of ankylosis is not fully elucidated, but the theory most accepted is that it happens because of periodontal ligament necrosis through mechanical damage by crushing [11-13].

Ankylosis is accompanied by a relative increase in dental infra-position and inclination of adjacent teeth, resulting in functional and aesthetic problems [14]. The severity of infra-occlusion depends on the stage of the patient's facial development [13].

Although there is no known treatment for dentoalveolar ankylosis, there are various alternative procedures suggested in the literature, such as keeping the ankylosed tooth or its root, extraction followed by orthodontic treatment, autotransplantation, implant, osteotomy tooth-bone or decoronation [14,15].

Decoronation is a procedure in which the crown of the ankylosed tooth is surgically

removed below the cemento-enamel junction and the root is buried. Generally, an aesthetic space maintainer is installed, preventing bone loss until the opportune to provide a definitive rehabilitative treatment [15].

The aim of this paper is report a case in which decoronation was performed in a young child (8-year-old girl) and discuss the literature on the philosophy of decoronation addressing technique, advantages and factors influencing their choice.

## CASE REPORT

Patient LSM, a 8-year-old girl, was referred to our Pediatric Clinic of School of Dentistry at the Federal University of Ceará after colliding with a wall while she was playing. The tooth 21 was avulsed and brought by her mother stored in milk. The replantation occurred one hour after injury. 14 days after the initial treatment, the patient returned and the endodontic therapy was started, returning every two months to exchange endodontic dressing based in calcium hydroxide until the decoronation procedure was done.

With a regular monitoring (every month), it was realized that the element 21 was ankylosed (Figure 1). It was in infra-occlusion with metallic percussion sound and, radiographically, with areas of replacement resorption (Figure 2). Then, an orthodontic assessment and documentation was requested for evaluation of treatment options.

From the analysis of the models and imaging exams (panoramic and teleradiography), was diagnosed that the patient presented with malocclusion Angle Class I, with a straight facial profile and brachycephalic pattern. The premolars of the patient were in stage 8 of Nolla. So, as the first option, the proposed plan was the auto-transplantation. The tooth that would be transplanted to the region of tooth 21 was the second premolar of the inferior jaw and the second option for transplant was the first upper premolar. However, from a psychological evaluation of the child and a conversation with the mother, it was

realized that this procedure would not be feasible. Therefore, the choice of the treatment was to perform a decoronation followed by installation of a removable space maintainer and subsequent prosthetic rehabilitation.

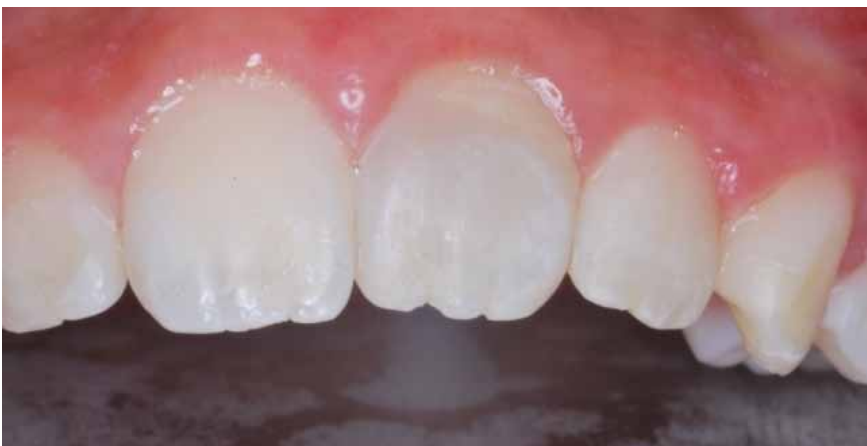Prior to surgery, the patient's dental arches had been molded with alginate to make possible the preparation of rehabilitation unit through models. The choice was a aesthetic space maintainer, which contributes to not harm function and aesthetics immediately after decoronation. The space maintainer was removable and adapted by staples with an expander bolt installed (Figure 3).

The surgical procedure was performed approximately 2 years after the first clinical examination. Initially, was made the antisepsis of the oral cavity with chlorhexidine digluconate 0.12% followed by application of benzocaine topical anesthetic in the bottom of the groove. Then, terminal infiltrative anesthesia was done in the ankylosed tooth region. Fitted with a scalpel blade # 15, the intra-sulcus around the tooth and adjacent marginal relief incision was made [Figure 4]. The buccal mucoperiosteal flap was elevated, exposing the vestibular cortical bone of the teeth 11, 21 and 22 [Figure 5] and the palatal tissue is left intact. With the aid of a surgical drill 702 high speed and under irrigation with saline, the dental crown was removed near the cementum-enamel junction [Figure 6]. Then a drill #6 was resorted to lower the root

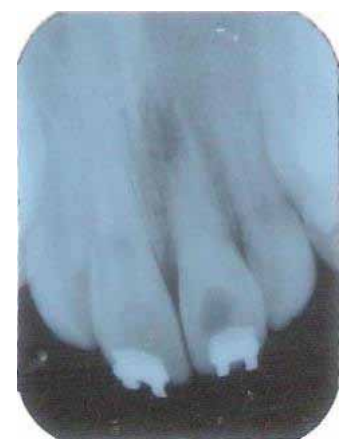approximately 1mm below the marginal bone, favoring bone formation coronal to the root. The channel was irrigated with enough saline solution, but still keeping the blood clot [Figure 7]. The wound edges were approximated, but not tensioned, and sutured by first intention healing occurs. Shortly after, the aesthetic space maintainer [Figure 8] was installed. This gadget should be kept until the patient completes all their bone growth.

The patient was oriented how and when installs the gadget as well as the hygiene that must be done and analgesic was prescribed. The patient returned for follow-up visits after one week for removal the suture and for clinical and radiographically evaluation after 1 month, 3 months, 6 months and 3 years in order to check the healing process and to assess whether there was need to adjust the appliance.

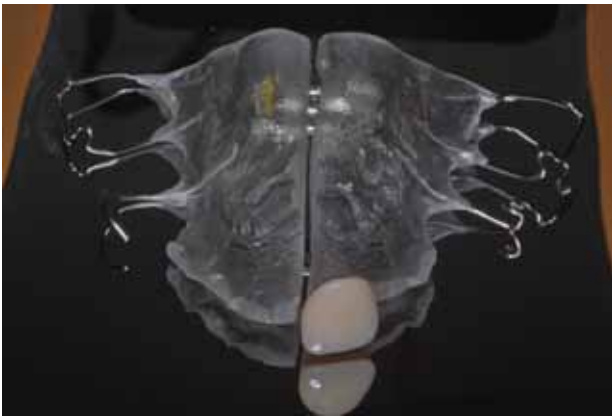
In the 6-month evaluation, radiographically, the buried root showed signs of resorption, but without bone loss. In fact, was possible to observe vertical bony ridge growth at the decoronation site [Figure 9]. The aesthetic space maintainer was still well adapted [Figure 10] and the alveolar ridge have no signals of inflammation or any other gingival or bony issues [Figure 11]. After three years, radiographic evaluation [Figure 12] showed complete root resorption and signs bone formation in root previous site.



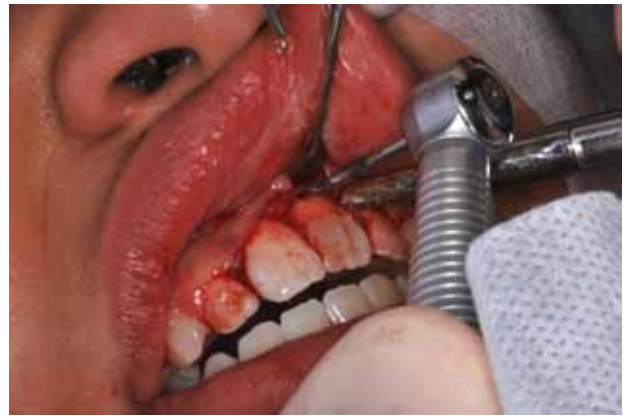**Figure 1** - Infra-position as a clinical sign of dental ankylosis [frontal view].



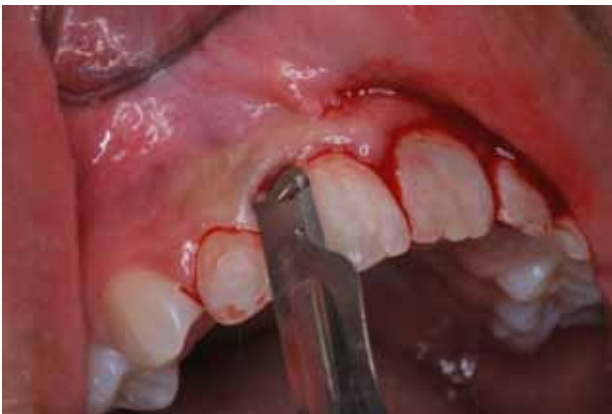**Figure 2** - Radiography showing the substitutive tooth resorption.



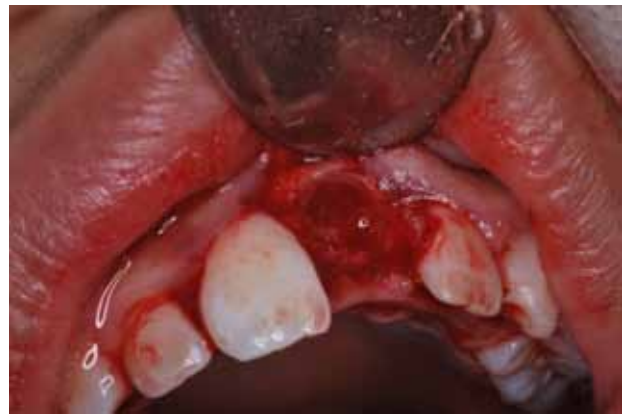**Figure 3** - Aesthetic space maintainer.



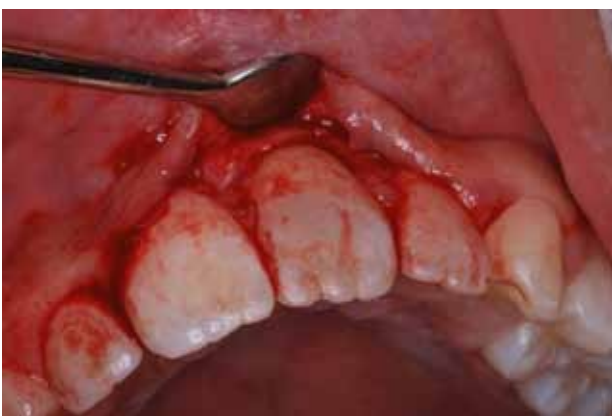**Figure 6** - Removal of dental crown with surgical drill # 702.



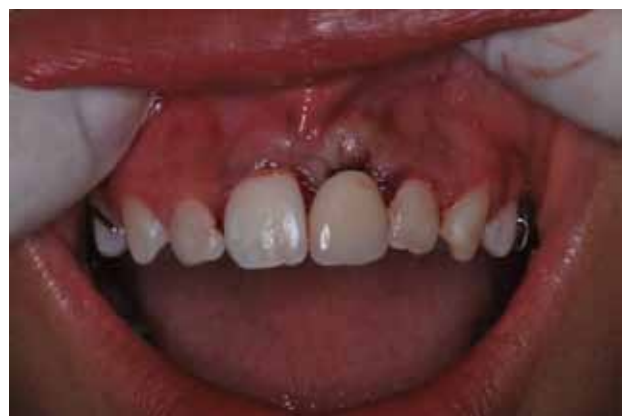**Figure 4** - Incision with blade n° 15.



**Figure 7** - Maintenance of blood clot.

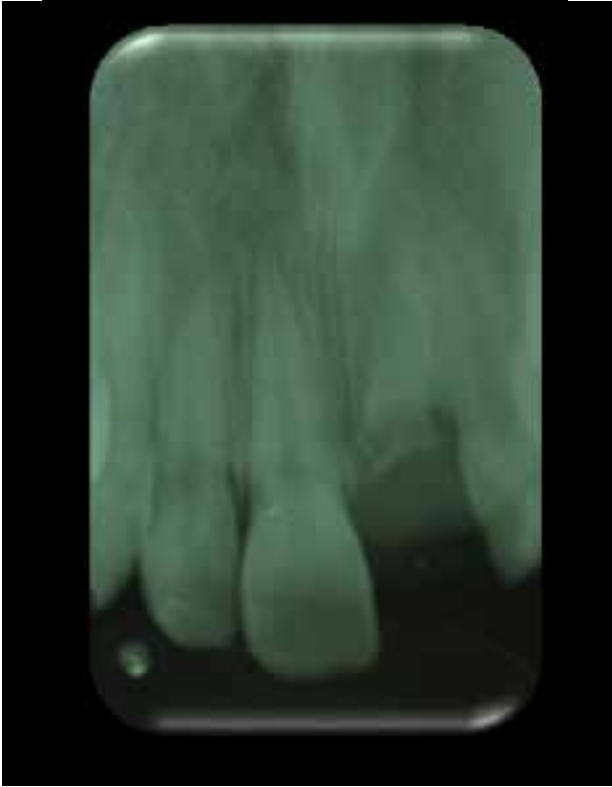


**Figure 5** - Cortical bone exposure of the ankylosed tooth and its adjacent.

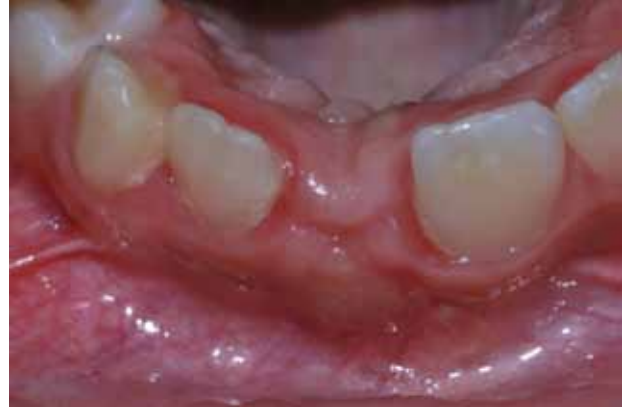

**Figure 8** - Patient after surgery with aesthetic device already installed.

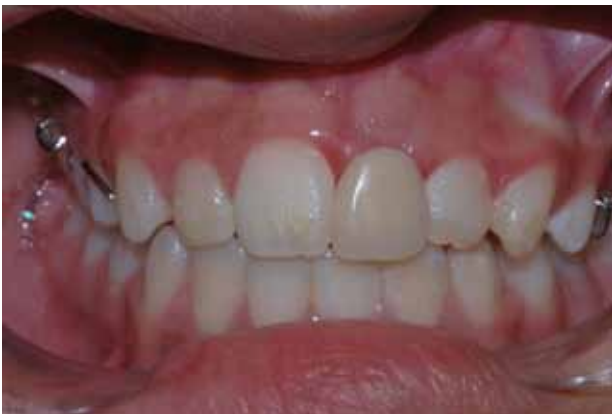



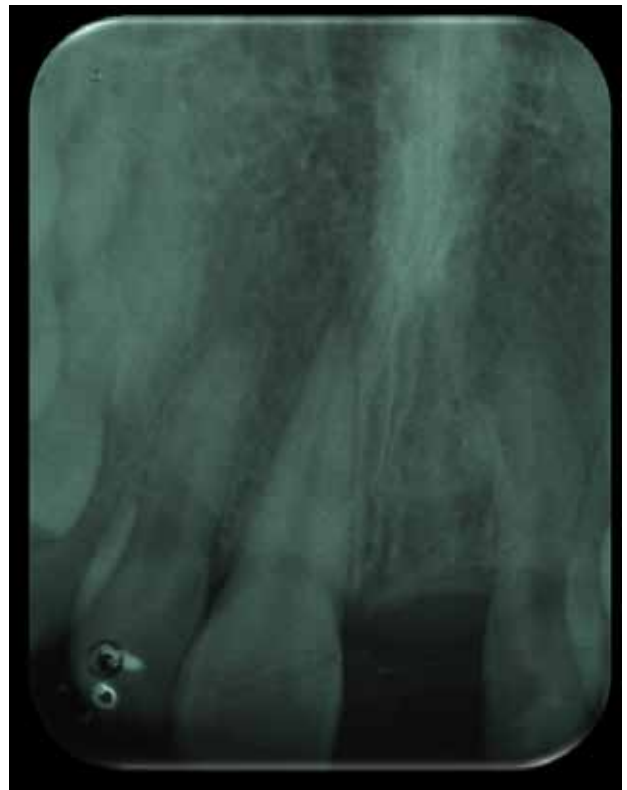**Figure 9** - Radiographic evaluation of root buried 6 months after decoronation.



**Figure 11** - Clinical evaluation 6 months after decoronation: verification of the condition of the alveolar ridge.



**Figure 10** - Clinical evaluation 6 months after decoronation: verification of the adaptation of the aesthetic space maintainer.



**Figure 12** - Radiographic evaluation of root buried 3 years after decoronation.

## DISCUSSION

In young patients with ankylosed maxillary central incisors, the auto-transplantation of premolars replacing the affected element, as well as orthodontic space closure are viable treatment options [15-17]. However, there are contraindications for such techniques.

In the described clinical case, the patient did not present a favorable self-transplant psychological profile, though having the premolars with open apex.

Upon diagnosis of ankylosis, it is not necessary to perform decoronation immediately. Usually, it is performed 2-3 years after diagnosis.

Sapir and Shapira [13] considered that the best time for decoronation is two years prior to implant placement. Malmgren et al. [18] suggested that in the early mixed dentition [7-10 years] decoronation should be performed within 2 years of diagnosis or before the growth spurt and at the end of mixed dentition [10-12 years]. The skeletal maturity and not the chronological age of the patient must be considered to avoid an undesirable aesthetic outcome of the implant-supported final prosthesis [19]. In the case reported, were decided to perform the decoronation when the patient were psychologically ready to the procedure and to use the aesthetic space maintainer for a long period, two years after dental trauma. The root and bone resorption must be also a factor to decide to perform the procedure.

Decoronation provides certain advantages over other treatment options: [1] it is reliable in terms of width and height preservation of the alveolar process, [2] it is a simpler and more economical surgical procedure than ridge augmentation, and [3] vertical bone apposition is possible [13,14].

The indication for coronal release should therefore take into account this level of risk and difficulty, which is commensurate with the degree of crown submergence, however skillful, the surgeon [20]. After removal of the tooth crown, the root canal must be filled, this must be removed before the root is buried to avoid any foreign body reaction. After surgery to remove the crown of the ankylosed tooth, a blood clot should maintained because that procedure reduces the risk of infection and induces bone formation on the inner surface of the root canal [14].

Maintenance of width, height and continuity of the alveolar bone ridge was noticed, without any signals of inflammation or any gingival issue. The vertical bone height was preserved and bony apposition in the site was also noticed, but a tomography would be helpful to check the additional apposition of bone coronal to the decoronation level. Those factors

may promote a better prognostic in the future rehabilitation with dental implants. Sapir et al. [16] reported that decoronation maintains the thickness and height of the alveolar bone, aiding in future rehabilitation with minimal or no bone grafting procedure. Previous published studies have shown that this procedure is a reliable technique in terms of preservation of the width and height of the alveolar process [18]. But Lin et al. [22] concluded that the longer was the follow-up period, the greater was the resorption of the bucco-palatal dimension of the alveolar bone of the decoronated tooth. In association of those studies, Tsukiboshi and Tsukiboshi [23] analyzed a serie of 4 cases and observed that buccal bone and the ankylosed root were resorbed on the buccal side, but the palatal side was unaffected.

Alveolar process resorption after tooth extraction in both jaws is significantly greater on the buccal aspect than the lingual or palatal; thus, the reduction in width of the maxillary alveolar ridge is greater than the loss of height [24]. Although many case reports describing decoronation can be found in dental literature, there is a paucity of cases that actually present successful implant insertion after decoronation [17, 20]. In our case, the patient will wait until she is old enough to have a dental implant inserted on her alveolar bone. There are several reasons that lead many authors to accept decoronation as a viable technique. The studies indicate that there are vertical bone apposition be removed after a crown, enhancing bone volume in place of a future implant.

Aesthetic space maintainers are a good option for aesthetic and functional needs in children. Although need being changed over time due to bony growth, these devices are constantly used in pediatric dentistry, fixed or removable. The prosthetic crowns are an excellent way of aesthetic and functional rehabilitation, but difficult to be used in pediatric patients, because it needs more and longer sessions and high cost. Removable maintainer was chosen due

to the patient age, with greater possibility of collaboration to use it, and low cost.

The decoronation is a simple, economical, reliable surgical procedure to ensure the preservation of normal height and thickness of the alveolar process, which besides being a complete extraction of an ankylosed tooth safe and less traumatic procedure. In reported case, it was a successful procedure, allowing the patient to maintain the aesthetic, function and preserve the alveolar process to a future reahabilitation.

## REFERENCES

- Andreasen J O. Replantation of avulsed teeth. In: Andreasen J O, Andreasen F M, Andersson L. Textbook and color atlas of traumatic injuries to the teeth. 4th ed. Copenhagen: Blackwell Munksgaard; 2007. p. 472–5.
- Petrovic B, Markovic D, Peric T, Blagojevic D. Factors related to treatment and outcomes of avulsed teeth. *Dent Traumatol*. 2010 Feb;26(1):52-9. doi: 10.1111/j.1600-9657.2009.00836.x
- Zhang X, Ghong Y. Characteristics of avulsed permanent teeth treated at Beijing Stomatological Hospital. *Dent Traumatol*. 2011 Oct;27(5):379-84. doi: 10.1111/j.1600-9657.2011.01024.x.
- Flores MT, Andreasen JO, Bakland LK, Feiglin B, Gutmann JL, Oikarinen K et al. Guidelines for the evaluation and management of traumatic dental injuries. *Dent Traumatol*. 2001 Oct;17(5):193-8.
- Petersson EE, Andersson L, Sorensen S. Traumatic oral vs. non-oral injuries. *Swed Dent J*. 1997;21(1-2):55-68.
- Fountain SB, Camp JH. Traumatic injuries. In: Cohen S, Burns AC, eds. *Pathways of the Pulp*, 6th ed. St Louis: Mosby; 1994. p. 436–85.
- Guedes OA, de Alencar AH, Lopes LG, Pécora JD, Estrela C. A retrospective study of traumatic dental injuries in a Brazilian dental urgency service. *Braz Braz Dent J*. 2010;21(2):153-7.
- American Association of Endodontists. Glossary of endodontic terms. 7th ed. Chicago: American Association of Endodontists; 2003.
- Barret K, Kenny DJ. Avulsed permanent teeth: a review of the literature and treatment guidelines. *Endod Dent Traumatol*. 1997 Aug;13(4):153-63.
- Trope M. Avulsion of permanent teeth: theory to practice. *Dent Traumatol*. 2011 Aug;27(4):281-94. doi: 10.1111/j.1600-9657.2011.01003.x.
- Filippi A, Pohl Y, von Arx T. Decoronation of an ankylosed tooth for preservation of alveolar bone prior to implant placement. *Dent Traumatol*. 2001 Apr;17(2):93-5.
- Campbell KM, Casas MJ, Kenny DJ. Development of ankylosis in permanent incisors following delayed replantation and severe intrusion. *Dent Traumatol*. 2007 Jun;23(3):162-6.
- Sapir S, Shapira J. Decoronation for the management of an ankylosed young permanent tooth. *Dent Traumatol*. 2008 Feb;24(1):131-5. doi: 10.1111/j.1600-9657.2006.00506.x..
- Cohenca N, Stabholz A. Decoronation: a conservative method to treat ankylosed teeth for preservation of alveolar ridge prior to permanent prosthetic reconstruction – literature review and case presentation. *Dent Traumatol*. 2007 Apr;23(2):87-94.
- Khalilak Z, Shikholislami M, Mohajeri L. Delayed tooth replantation after traumatic avulsion: A case report. *Iran Endod J*. 2009;3(3):86–9.
- Sapir S, Kalter A, Sapir MR. Decoronation of an ankylosed permanent incisor: alveolar ridge preservation and rehabilitation by an implant supported porcelain crown. *Dent Traumatol*. 2009 Jun;25(3):346-9. doi: 10.1111/j.1600-9657.2009.00788.x.
- Sigurdsson A. Decoronation as an approach to treat ankylosis in growing children. *Pediatr Dent*. 2009 Mar-Apr;31(2):123-8.
- Malmgren O, Malmgren B. Orthodontic management of the traumatized dentition. In: Andreasen FM, Andreasen JO, Andersson L. [eds]. Textbook and color atlas of traumatic injuries to the teeth. Copenhagen: Munksgaard; 2007. p. 669–715.
- Calasans-Maia JA, Neto AS., Batista MMD, Alves ATNN, Granjeiro JM, Calasans-Maia, MD. Management of ankylosed young permanent incisors after trauma and prior to implant rehabilitation. *Oral Surgery*. 2014;7(1):45–51.
- Garcia, A. Ankylosis of impacted canines: A retrospective post-surgical study. *Int Orthod*. 2013;11:422-31.
- Malmgren B. Ridge preservation / decoronation. *J Endod*. 2013;39 [Suppl]:S67–72.
- Lin S, Schwarz-Arad D, Ashkenazi M. Alveolar Bone Width Preservation after Decoronation of Ankylosed Anterior Incisors. *J Endod*. 2013;39(12):1542-4.
- Tsukiboshi M, Tsukiboshi T. Bone morphology after delayed tooth replantation – case series. *Dent Traumatol*. 2014 Dec;30(6):477-83. doi: 10.1111/edt.12111.
- Araujo MG, Lindhe J. Dimensional ridge alterations following tooth extraction: an experimental study in the dog. *J Clin Periodontol* 2005;32:212–8.

### José Jeová Siebra Moreira Neto (Corresponding address)

Correspondence to: Prof. Dr Jose Jeova Siebra Moreira Neto,  
Faculdade de Farmacia, Odontologia e Enfermagem,  
Universidade Federal do Ceara  
Rua Parsifal Barroso, 1061 – Edson Queiroz, Fortaleza, Ceará  
E-mail: jeova@ufc.br

Date submitted: 2015 Mar 12

Accept submission: 2015 May 23