

Combination of dentoalveolar traumatic injury: a case report (10 - year follow-up)

Associação de injúrias traumáticas dentoalveolares: relato de caso (10 anos de controle)

Jacqueline Dolphine GRENIER¹, Marcos Sergio ENDO¹, Joana Yumi Teruya UCHIMURA¹, Elen de Souza TOLENTINO¹, Nair Narumi Orita PAVANI

¹ – Department of Dentistry – Health Science Center – State University of Maringá – Maringá – PR – Brazil.

ABSTRACT

Tooth Injury comprises a group of clinical conditions that might lead to separation or breakage of tooth and its surrounding tissues. A case of multiple concomitant dental trauma is reported. In 2004, a female patient, 11 years old, visited the dental office half hour after dental trauma caused by a fall in the pool. She complained of mild discomfort in tooth 11 (right central maxillary permanent incisor); in the clinical assessment, the tooth showed partial displacement from its socket and grade 2 mobility; in the radiographic analysis, the tooth showed an increase in periodontal ligament space, a diagnosis of extrusive luxation. The adjacent teeth 21 and 22 (left central and lateral maxillary permanent incisors), presented subgingival bleeding, and were diagnosed with subluxation. After treatment planing, the clinical approach consisted of manual reduction of tooth 11 and non-rigid splint of the affected teeth. The patient received prescription of antibiotic and anti-inflammatory medicine. After 15 days, the splint was removed and teeth 11, 21 and 22 showed pulpal sensibility, maintaining the same results for 4 months. In the 4th month, tooth 11 was diagnosed with pulp necrosis, thus requiring endodontic treatment. After 10 years, teeth were asymptomatic, with a slight color change in tooth 11; cone beam scan indicated root resorption in the apical third of the three elements and the presence of dystrophic calcification in teeth 21 and 22. In conclusion, the injured teeth remained in function with relevant follow-up period, highlighting the search for a response, upon the purpose of the study.

KEYWORDS

Endodontics; Multiple trauma; Treatment.

RESUMO

Os traumatismos dentários são um grupo de situações clínicas que podem apresentar a separação ou ruptura do dente e de seus tecidos adjacentes. Um caso de múltiplos traumatismos dentários concomitantes será relatado. Em 2004, paciente do gênero feminino, 11 anos, compareceu ao consultório odontológico meia hora após sofrer um traumatismo dentário causado por queda na piscina. Queixava-se de leve desconforto no dente 11 que clinicamente, apresentava-se parcialmente deslocado de seu alvéolo e com grau 2 de mobilidade. Radiograficamente, com um aumento do espaço do ligamento periodontal obtendo um diagnóstico de luxação extrusiva. Os dentes adjacentes, 21 e 22, com sangramento subgingival foram diagnosticados com subluxação. Após elaboração do plano de tratamento, a conduta clínica consistiu na redução manual do dente 11 e contenção não rígida dos dentes acometidos. A paciente foi apoiada com terapia medicamentosa, com antibiótico e anti-inflamatório. Após 15 dias, a contenção foi removida, e os dentes 11, 21 e 22 apresentavam-se com sensibilidade pulpar, mantendo os mesmos resultados durante 4 meses. No 4º mês diagnosticou-se necrose pulpar do dente 11, requerendo assim, intervenção endodôntica. Após 10 anos, ao exame clínico os dentes apresentam-se assintomáticos, sendo que o dente 11 sugere leve alteração de cor; enquanto que por meio da análise cone beam verifica-se reabsorção radicular no terço apical dos três elementos e presença de calcificação distrófica do 21 e 22. Concluiu-se que, os dentes traumatizados permanecem em função com período de controle relevante, destacando-se procurar uma resposta frente ao objetivo do estudo.

PALAVRAS-CHAVE

Endodontia; Traumas múltiplos; Tratamento.

BRIEF LITERATURE REVIEW

Luxation of permanent teeth is classified into the following categories: subluxation, lateral luxation, intrusion and extrusion. Subluxation is an injury to tooth supporting structures with abnormal loosening, but without displacement of the tooth. Often there is minor bleeding from the sulcus around the tooth, and periapical radiographs show that the periodontal ligament width is normal or only slightly thickened. A clinical sign of extrusion is an elongated mobile tooth and a common radiographic finding is an apically increased periodontal space. The accepted treatment for extrusion is repositioning of the extruded tooth at the earliest opportunity and stabilization with a splint for up to 3 weeks [1].

Severely luxated and displaced teeth tend to develop more extensive sequelae (e.g., pulp necrosis, root resorption, canal calcification, and/or cessation of root development of immature teeth) than teeth that suffer only a minor luxation and displacement [2].

Pulp canal obliteration, also called calcific metamorphosis, is a sequel of dental trauma. It has been reported to develop more frequently in teeth with concussion and subluxation injuries [3]. Furthermore, pulp necrosis is a frequent complication in teeth with extrusive luxation injury [4]. When a dental trauma results in extrusion of tooth, a close to total severance of the periodontal ligament occurs. The trauma involves a high risk of disruption of the neurovascular supply at the apex of the tooth, which causes pulp infarction [5].

The factors that determine the type and severity of the luxation injury seem to be related to the power and direction of the impact. The resilience of the alveolar bone, which decreases with age, probably plays an important role [6]. The prognosis of the traumatized tooth depends on accurate diagnosis and treatment procedures. Dental injuries result in functional, esthetic and psychological disturbances accompanied by a

great concern for the child and parents. A case of multiple trauma concomitant with different dental traumatic injuries is reported in this study.

CASE REPORT

In 2004, an 11-year old girl visited the dental office within 30 min immediately after the accident, with discomfort and mild pain in her maxillary right central incisor. The child reported she fell on her face while playing at swimming pool. She did not feel great pain after the trauma.

Clinically, the right central incisor (11) was extrusively luxated. The tooth was partially displaced from its bony socket. The central incisor (11) was extruded, displaced palatally and was slightly mobile (grade 2: horizontal loosening between 1 and 2 mm). There was bleeding from the periodontal ligament and the girl reported pain during occlusion. Moreover, the clinical examination of the patient indicated subluxation of teeth 21 and 22.

Radiographically, the right central incisor was displaced, with an increased periodontal ligament space after the accident (Figure 1).

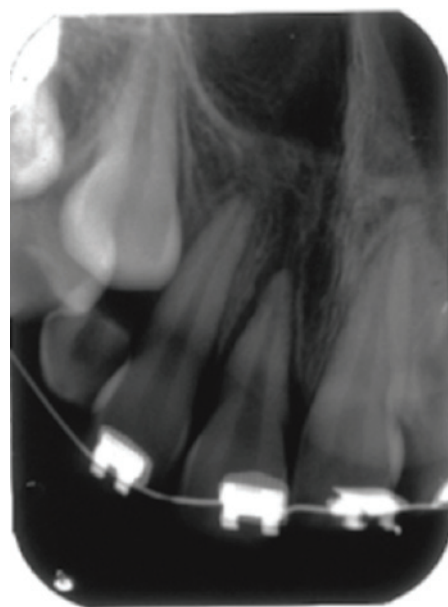


Figure 1 - Periapical radiograph of the incisors after the accident.

Treatment performed after dental injury

The treatment consisted of manual reduction and splinting of the injured tooth using non-rigid splint with Unitek twist wire (3M Unitek, Monrova, CA, USA), acid etching, bonding agent (Prime&Bond NT; Dentsply, De Trey, Konstanz, Germany) and resin composite (Filtek Z250; 3M, St Paul, MN, USA) to labial crown surfaces of teeth 11, 12, 21 and 22. The injury of gingival tissue was cleaned. The patient was supported with drug therapy including antibiotics and anti-inflammatories, and advised to use chlorhexidine twice a day for 1 week, eat a soft diet for 10-14 days and to brush teeth with a soft toothbrush after each meal. The patient returned 15 days later, and the non-rigid splint was removed. The teeth (11, 21 and 22) were diagnosed as vital after cold test during 4 months. There was no color change in the crown and the crown of the tooth was intact.

Pulp necrosis of the tooth 11 was observed after 4 months. The root formation was completed.

The root canal of the tooth 11 was cleaned, shaped and filled with the interim placement of slurry calcium hydroxide (CALEN S.S White, Artigos dentários LTDA., Rio de Janeiro, RJ) for 3 months, changing the medication every month. Root canal therapy was performed using laterally condensed gutta-percha and sealer (Sealapex; Kerr-Sybron, Orange, USA) and restored with a composite resin (Filtek Z250; 3M, St Paul, MN, USA).

A 10-year clinical follow-up revealed a yellowish, no extruded tooth with adequate gingival health (Figure 2). The right central incisor was well positioned, with physiological mobility and the crown was discolored. The occlusion was normal. Percussion and palpation testing revealed no pain. The tooth showed external root resorption as complication of periodontal ligament healing by cone beam tomography (Figure 3).

A periapical radiograph (Figure 4) indicated no signs of apical periodontitis for all teeth.

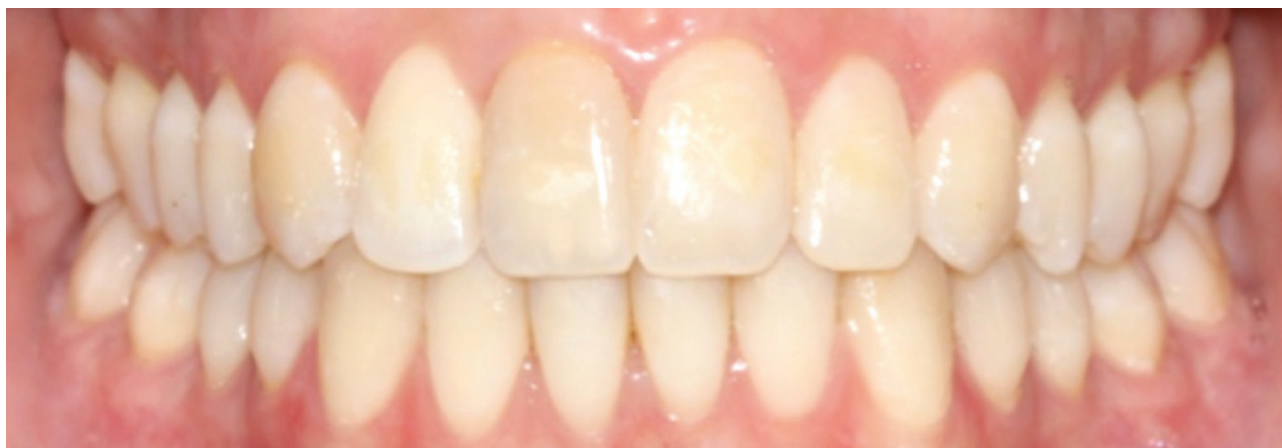

Figure 2 - 10-year clinical follow-up.

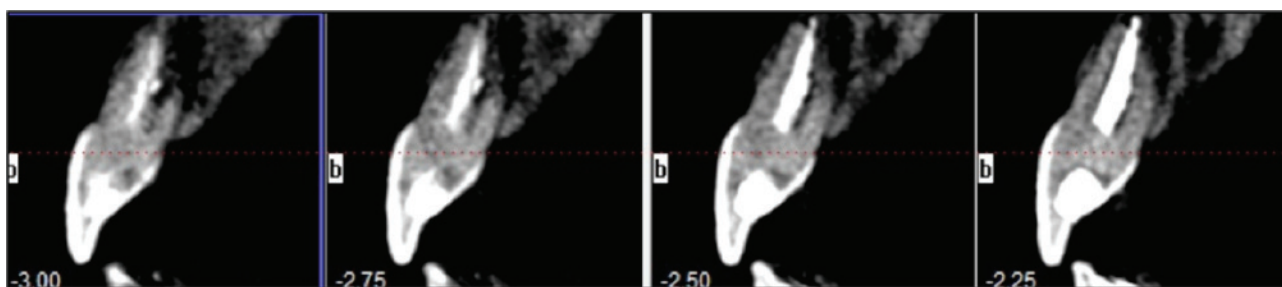


Figure 3 - Cone beam computed tomography analysis.

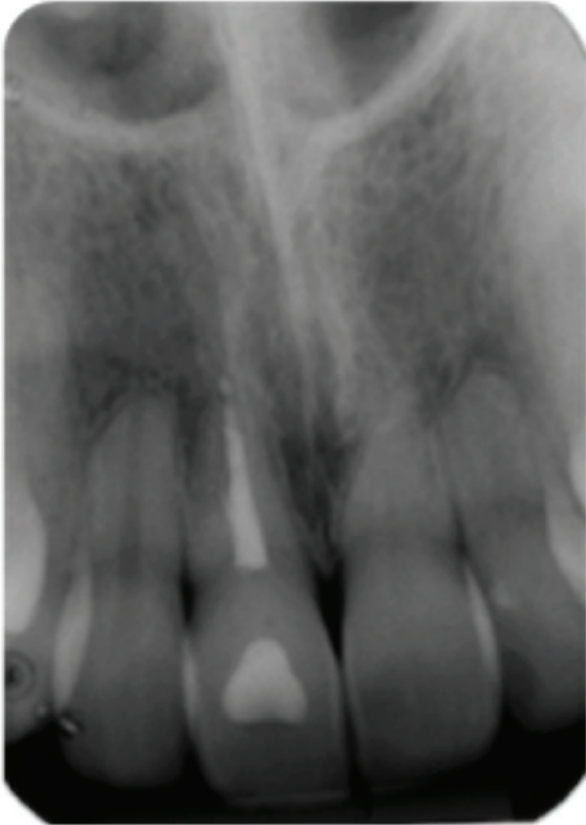


Figure 4 - 10-year periapical radiograph follow-up.

The pulp of teeth 21 and 22 have not responded to vitality testing with cold spray due to the presence of calcification (Figure 4).

DISCUSSION

This case report describes the management of dentoalveolar trauma involving subluxation (21, 22) and extrusive luxation (11) of permanent teeth. Previous studies have shown that maxillary incisors are the most often traumatized teeth [7,8]. Single injury was the most common type in the literature [8].

Subluxation injury induced a deposition of hard tissue in the root canal space. Calcification may be clinically recognized in the first 3 months after injury, in most cases it is not detected for about 1 year [9]. Teeth are usually asymptomatic and periapically normal in the radiograph assessment, according to the present case. Responses to heat and cold decrease with time,

and generally there is no sensitivity to percussion [10]. Some dentists have performed a prophylactic root canal treatment, which should be initiated before the calcification process, however, in this case, we chose a more conservative approach with radiographic follow-up.

In extrusions, as in the tooth 11, the tooth is loose and markedly extended out of its socket in comparison with adjacent teeth. It is known that if a tooth moves more than 2 mm in the axial direction, there is little hope for pulp survival, particularly if the involved tooth shows a fully formed apex [11].

The positive response of the pulp (11) of the tooth subjected to extrusive luxation remained for some months. Skieller (1960) reported that, in a sample of six extrusively luxated teeth with closed apices, two of the teeth responded to electric vitality testing after one to six years, whereas the other four teeth remained non-responsive [12]. Similarly as shown in this report, Andreasen (1970) observed that in a sample of teeth with open and closed apices, 56 out of 88 (64%) showed pulpal necrosis after extrusive luxation injuries [13].

In cases of lateral luxation with apical displacement, intrusive luxation, or severe extrusive luxation of a mature tooth, there is little chance for pulp survival [14]. Endodontic therapy should therefore be initiated between 7 and 10 days post-trauma to prevent the necrotic pulp from becoming infected [12]. However, in this case, endodontic therapy started just after 4 months due to positive pulp response obtained during control examination.

A thorough clinical and radiographic examination is very important because it may be questionable whether the entire tooth is extruded or whether there is an extruded coronal fragment of an intraalveolar root fracture. Depending on how far the tooth has been extruded, the pulp may or may not respond to pulp tests. The greater the extent of the extrusive luxation, the greater the likelihood that the tooth neurovascular

bundle has been severed [13]. Therefore, before any treatment, it is important to document how much the tooth has moved away from its original position. The clinician should also ask if the tooth has been repositioned back to its socket before the dental visit.

Andreasen et al. categorized the treatment periods after traumatic dental injuries into acute (within few hours), subacute (within the first 24 h) and delayed (after the first day) [2]. The classification was based on the data obtained from the consequences of treatment delay on pulpal and periodontal healing following dental traumatic injuries. According to this criterion, the extrusively luxated tooth should be repositioned to its original position within the first 24 h in an acute or subacute manner. In case of delayed treatment, the tooth may realign spontaneously into its normal position or may be repositioned orthodontically [15].

Two important aspects of dental trauma healing should be considered, namely the effect of repositioning and splinting and, secondly, the prevention of infection. Early repositioning and stabilization will promote the best periodontal repair [16]. Because the luxated tooth may still be somewhat loose 7 to 10 days after the trauma, it is, in most cases, easier to keep the tooth splinted, while it is being endodontically treated. The splint can then be removed at the end of the appointment, if so indicated.

The 7 - to 10 - day delay in endodontic treatment is necessary because: (1) additional manipulation of the tooth could further traumatize the tooth and PDL, besides adding treatment time to the emergency visit, and (2) the early application of calcium hydroxide, the most commonly used intracanal medicament in dental trauma, can have a detrimental effect on PDL healing, if applied too early [17]. Time must be allowed for the PDL to reattach [18].

If endodontic therapy is necessary, the tooth should be accessed aseptically, with rubber dam isolation, and instrumented to the

appropriate size. It is not advisable to clamp the traumatized tooth. Currently, the most widely accepted intracanal medicament is calcium hydroxide paste, either premixed or mixed with chlorhexidine or sterile water [19,20]. It has been shown that if calcium hydroxide is placed into the root canal system of a traumatized tooth before becoming infected, and kept in place from 2 weeks to several months, the treatment outcome is favorable [21]. Thus, in this case report, it was recommended the use of temporary dressing of calcium hydroxide, 90 days before the filling, in order to prevent infection of the root canal and in an attempt to stimulate the periapical repair [22].

In tooth with extrusive luxation and pulp necrosis, root-canal therapy is indicated. If neglected, infection-related root resorption is a distinct and dangerous possibility. Pulp necrosis and root resorption are often found in young patients with delayed or no treatment after dental trauma [16].

The major parameters affecting pulp healing after luxation trauma is the stage of root formation and the severity of luxation [2,15]. As a result of displacement of the root after luxation injuries, several pulpal changes may occur. These changes are pulp necrosis with gray color change in the crown, pulp revascularization which may lead to regressive changes and pulp canal obliteration with yellow color change in the crown [15]. There is a possibility of pulp necrosis associated with periapical radiolucency among these teeth showing pulp canal obliteration over time [23]. Likewise, in this case, for teeth with mature root development, this healing process is affected by the small contact area between the ischemic pulp tissue and the periodontal tissue [24]. Pulp healing is critically dependent on the absence of bacteria [25,26].

Abnormal periodontal healing is usually diagnosed within 2–3 months when root resorption becomes apparent [27]. However, in this case, the resorption was identified later. The degree of involvement of adjacent structures

associated with immediate therapeutic conduct may have delayed this pathological condition.

Experimental studies on monkeys showed normal healing of the periodontal ligament of the extrusively luxated teeth after 3 weeks [18]. However, external root resorption may be seen as complication of periodontal ligament healing following luxation injuries [28,29].

In accordance with a previous clinical study by Andreasen & Andreasen, periodontal healing after luxation injuries is divided into the following four groups: (1) normal periodontal healing, (2) repair-related resorption (surface resorption), (3) infection-related resorption (inflammatory resorption, only in teeth with pulp necrosis), and (4) ankylosis-related resorption (replacement resorption) [30]. In this case, it was detected 10 years after apical resorption.

Recently, cone beam computed tomography (CBCT) [31] has become increasingly important for diagnosis and treatment planning. Studies have suggested that CBCT provides accurate and reliable linear measurements for reconstruction and imaging of dental and maxillofacial structures [32]. When lesions are small, CBCT imaging shows better diagnostic results [33]. These clinical studies presume that the radiologic findings from CBCT scanning represent the “true” status of the periapical tissues [34].

In this case, 10 years after the trauma, the teeth involved in the trauma showed apical resorption. The treatment was considered successful. This is probably because of early diagnosis of acute treatment.

CONCLUSION

In conclusion, acute treatment is important after dental traumatic injuries, which are common in children and adolescents, resulting in successful cases when properly treated. An education program should be developed to encourage patients, parents and medical physician to seek dental treatment immediately after traumatic injuries.

REFERENCES

1. Flores MT, Andreasen JO, Backland LK, Feiglin B, Gutmann JL, Oikarinen K, et al. Guidelines for the evaluation and management of traumatic dental injuries. *Dent Traumatol.* 2001;17(4):145–8.
2. Andreasen JO, Andreasen FM, Skeie A, Hjorting-Hansen E, Schwartz O. Effect of treatment delay upon pulp and periodontal healing of traumatic dental injuries - a review article. *Dent Traumatol.* 2002;18(3):116–28.
3. Oginni AO, Adekoya-Sofowora CA. Pulpal sequelae after trauma to anterior teeth among adult Nigerian dental patients. *BMC Oral Health.* 2007 Aug 31;7:11.
4. Lee R, Barrett EJ, Kenny DJ. Clinical outcomes for permanent incisor luxations in a pediatric population. II. Extrusions. *Dent Traumatol.* 2003;19(5):274–9.
5. Andreasen FM, Andreasen JO. Extrusive luxation and lateral luxation. In: Andreasen JO, Andreasen FM, Andersson L, editors. *Textbook and color atlas of traumatic injuries to the teeth*, 4th edn. Oxford: Blackwell Munksgaard; 2007. p. 411–27.
6. Chantawiboonchai P, Iida J, Soma K. Effects of aging on oxytalan fibre in mouse periodontal ligament. *J Med Dent Sci.* 1999;46(2):75–82.
7. Schatz JP, Joho JP. A retrospective study of dento-alveolar injuries. *Endod Dent Traumatol.* 1994;10(1):11–4.
8. Zerman N, Cavalleri G. Traumatic injuries to permanent incisors. *Endod Dent Traumatol.* 1993;9(2):61–4.
9. Rock WP, Grundy MC. The effect of luxation and subluxation upon the prognosis of traumatized incisor teeth. *J Dent.* 1981;9(3):224–30.
10. Patterson SS, Mitchell DF. Calcific metamorphosis of the dental pulp. *Oral Surg Oral Med Oral Pathol.* 1965;20(1):94–101.
11. Crona-Larsson G, Bjarnason S, Norén JG. Effect of luxation injuries on permanent teeth. *Endod Dent Traumatol.* 1991;7(5):199–206.
12. Skieller V. The prognosis for young teeth loosened after mechanical injuries. *Acta Odontol Scand.* 1960;18:171–81.
13. Andreasen JO. Luxation of permanent teeth due to trauma. A clinical and radiographic follow-up study of 184 injured teeth. *Scand J Dent Res.* 1970;78(3):273–86.
14. Andreasen FM, Pedersen BV. Prognosis of luxated permanent teeth—the development of pulp necrosis. *Endod Dent Traumatol.* 1985;1(6):207–20.
15. Andreasen JO, Andreasen FM, editors. *Luxation injuries. In: Textbook and Color Atlas of Traumatic Injuries to the Teeth.* Copenhagen: Munksgaard; 1993. p. 315–81.
16. Bakland LK, Andreasen JO. Dental traumatology: essential diagnosis and treatment planning. *Endod Topics.* 2004;7(1):14–34.
17. Lengheden A, Blomlof L, Lindskog S. Effect of immediate calcium hydroxide treatment and permanent root-filling on periodontal healing in contaminated replanted teeth. *Scand J Dent Res.* 1991;99(2):139–46.
18. Mandel U, Viidik A. Effect of splinting on the mechanical and histological properties of the healing periodontal ligament in the vervet monkey (*Cercopithecus aethiops*). *Arch Oral Biol.* 1989;34(3):209–17.
19. Sjogren U, Figdor D, Spangberg L, Sundqvist G. The antimicrobial effect of calcium hydroxide as a short-term intracanal dressing. *Int Endod J.* 1991;24(3):119–25.

20. Haapasalo HK, Siren EK, Waltimo TM, Orstavik D, Haapasalo MP. Inactivation of local root canal medicaments by dentine: an in vitro study. *Int Endod J*. 2000;33(2):126-31.
21. Trope M, Yesilsoy C, Koren L, Moshonov J, Friedman S. Effect of different endodontic treatment protocols on periodontal repair and root resorption of replanted dog teeth. *J Endod*. 1992;18(10):492-6.
22. Trope M, Moshonov J, Nissan R, Buxt P, Yesilsoy C. Short vs. long-term calcium hydroxide treatment of established inflammatory root resorption in replanted dog teeth. *Endod Dent Traumatol*. 1995;11(3):124-8.
23. Robertson A, Andreasen FM, Bergholtz G, Andreasen JO, Norén JG. Incidence of pulp necrosis subsequent to pulp canal obliteration from trauma of permanent incisors. *J Endod*. 1996;22(10):557-60.
24. Andreasen FM, Zhijie Y, Thomsen BL. Relationship between pulp dimensions and development of pulp necrosis after luxation injuries in the permanent dentition. *Endod Dent Traumatol*. 1986;2(3):90-8.
25. Andreasen JO, Jensen SS, Varawan S. The role of antibiotics in preventing healing complications after traumatic dental injuries: a literature review. *Endod Topics*. 2006;14(1):80-92.
26. Cvek M, Cleaton-Jones P, Austin J, Lownie J, Kling M, Fatti P. Effect of topical application of doxycycline on pulp revascularization and periodontal healing in reimplanted monkey incisors. *Endod Dent Traumatol*. 1990;6(4):170-6.
27. Hermann NV, Lauridsen E, Ahrensburg SS, Gerds TA, Andreasen JO. Periodontal healing complications following extrusive and lateral luxation in the permanent dentition: a longitudinal cohort study. *Dent Traumatol*. 2012;28(5):394-402.
28. Andreasen FM, Pedersen BV. Prognosis of luxated permanent teeth: the development of pulp necrosis. *Endod Dent Traumatol*. 1985;1(6):207-20.
29. Oikarinen KS, Stoltze K, Andreasen JO. Influence of conventional forceps extraction and extraction with an extrusion instrument on cementoblast loss and external root resorption of replanted monkey incisors. *J Periodontol Res*. 1996;31(5):337-44.
30. Andreasen FM, Andreasen JO. Diagnosis of luxation injuries: the importance of standardized clinical, radiographic and photographic techniques in clinical investigations. *Endod Dent Traumatol*. 1985;1(5):160-9.
31. Danforth RA, Dus I, Mah J. 3-D volume imaging for dentistry: a new dimension. *J Calif Dent Assoc*. 2003;31(11):817-23.
32. Lascala CA, Panella J, Marques MM. Analysis of the accuracy of linear measurements obtained by cone beam computed tomography (CBCT-NewTom). *Dentomaxillofac Radiol*. 2004;33(5):291-4.
33. Tsai P, Torabinejad M, Rice D, Azevedo B. Accuracy of cone-beam computed tomography and periapical radiography in detecting small periapical lesions. *J Endod*. 2012;38(7):965-70.
34. Moura MS, Guedes OA, De Alencar AH, Azevedo BC, Estrela C. Influence of length of root canal obturation on apical periodontitis detected by periapical radiography and cone beam computed tomography. *J Endod*. 2009;35(6):805-9.

**Elen de Souza Tolentino
(Corresponding address)**

Avenida Colombo, 5790 - Jardim Universitario,
Maringá - PR, 87020-900
elentolentino@gmail.com

Date submitted: 2015 May 18

Accept submission: 2015 Aug 10