



CASE REPORT

doi: 10.14295/bds.2017.v20i4.1401

Immediate implants placed into central incisors sockets: a surgical and prosthetic two years follow-up

Implantes imediatos instalados em alvéolos de incisivos centrais: follow-up cirúrgico e protético de dois anos

George Miguel SPYRIDES¹, Silvana Marques Miranda SPYRIDES¹, Tayane Holz RESENDE¹, Elson Braga de MELLO¹, Osmar AGOSTINHO NETO¹, Jeter Bochnia RIBEIRO¹¹ – Department of Prosthesis and Dental Materials – School of Dentistry – Federal University of Rio de Janeiro – Rio de Janeiro – RJ – Brazil.

ABSTRACT

The authors present a complete surgical and prosthetic case report of a 50-year-old male patient who lost the element 11 by periodontal disease, and during the phase of provisional restorations of the elements 12, 11, 21 and 22 had the element 21 fractured in domestic accident. The roots of the elements 11 and 21 suffered extraction and were replaced in the same act by a conic osseointegrated HE implant measuring 18 X 4 mm and graft of synthetic hydroxyapatite with a three months gap between the two surgical procedures. Six months after the second extraction with replacement of the root of the 21 element by an implant, four individual metal-free ceramic crowns were placed on the elements 12, 11, 21 and 22, two tooth-supported (12, 22) and two implant-supported on custom abutments of zirconia (11, 21), which fully rehabilitated the function and esthetics of the patient with the regeneration and maintenance of bone level and gingival papillae between the elements, due to the strict respect of the biological distances between the individual parts, with monitoring and photographic, radiographic and tomographic documentation previously, during and after the surgery, twenty eight months after the installation of the implant of the 21 element and twenty-one months after the cementing of the four crowns. The authors and the patient signed the Free Informed Consent Form for the presentation of the case which was submitted in accordance with the standards of CONEP.

KEYWORDS

Maxillary sockets; Immediate implant; Periodontal failure; Incisor fracture.

RESUMO

Os autores apresentam um caso clínico implanto-cirúrgico-protético completo em área estética com follow-up de dois anos de um paciente do sexo masculino, 50 anos de idade que inicialmente perdeu o elemento 11 por problema periodontal e, durante a fase dos provisórios nos elementos 12, 11, 21 e 22 teve o elemento 21 fraturado em acidente doméstico. As raízes dos elementos 11 e 21 sofreram exodontia e substituídas no mesmo ato por implantes osseointegráveis HE cônicos na medida de 18 X 4 mm e enxerto com hidroxiapatita sintética com interstício de três meses aproximadamente entre os dois procedimentos cirúrgicos. Seis meses após a segunda exodontia com substituição da raiz do 21 por implante, foram realizadas quatro coroas cerâmicas metal-free individuais nos elementos 12, 11, 21 e 22, sendo duas dento suportadas (12 e 22) e duas implanto-suportadas sobre abutments de zircônia personalizados (11 e 21), as quais reabilitaram plenamente a função e a estética do paciente com a regeneração e manutenção do nível ósseo e das papilas gengivais entre os elementos, graças ao estrito respeito às distâncias biológicas entre os elementos isolados, com acompanhamento e documentação fotográfica, radiográfica e tomográfica do período pré, trans e pós-operatório até a presente data, vinte e oito meses após a instalação do implante da região do 21 e vinte e um meses após a cimentação das quatro coroas cerâmicas. Os autores e o paciente assinaram o Termo de Consentimento Livre e Esclarecido (TCLE) para apresentação do caso o qual foi submetido de acordo com as normas da CONEP.

PALAVRAS-CHAVE

Alvéolos maxilares; Implantes imediatos; Colapso periodontal; Fratura de incisivos

INTRODUCTION

The need of tooth extraction due to periodontal or trauma reasons in the maxillary esthetic zone may lead to loss of the buccal alveolar plate following tooth extraction with severe esthetic complications. Immediate placement of dental implants and biomaterial graft into fresh post extraction sockets have been suggested by a great number of authors because it may avoid and preclude dramatic post extraction bone loss [1-5].

Misje et al. [6] in a 12-to 15-year retrospective study stated that follow-up is of great importance to predict high long-term survival of dental implant treatment in the esthetic zone, at least in healthy patients free from periodontal disease, and that prosthetic complications such as implants infra-position and porcelain fractures may be unavoidable. Conclude that patients should be given thorough preoperative information regarding the possible long-term outcome of dental implants in the esthetic zone.

The retrospective 5-year follow-up study of 56 patients treated with implants immediately placed in post-extraction sockets and immediately loaded of Mura [7] demonstrated good treatment outcome with regard to implant survival, soft tissue condition, and marginal bone response.

The level of the papilla around anterior maxillary teeth and dental implants is a major esthetic concern [8,9]. Starr [10] reported that maintaining the papilla height between a tooth and an adjacent implant is less predictable than between two adjacent teeth, and that concern for the loss of or reduction in height of the papilla between two adjacent implants has created the most difficult esthetic dilemma. Especially in the anterior maxilla, to address and manage the esthetic issues relative to the smile, the goal is to restore the hard and soft tissue height and width to an ideal anatomic ridge form. This would allow for construction of a clinical crown equal in size and shape to the adjacent clinical crowns. This is the great esthetic challenge. The smile line is the critical feature in this endeavor, and it's important to define the challenge anatomically

i. e, to study the most proper implant placement and the esthetic outcomes that can be achieved.

The authors describe in this double maxillary anterior palatal implant positioning report, the harmony of soft and hard tissue achieved after immediate implant replacement with bone augmentation in a unique and single esthetically challenging situation after two years of clinical, radiographic and tomographic follow-up.

CASE REPORT

Diagnosis

A 50-year-old male patient stood before the Department of Prosthesis and Dental Materials of the School of Dentistry of the Federal University of Rio de Janeiro, Brazil, for evaluation of the upper anterior region. The patient did not have any medical conditions and was not taking any medications that were associated with a compromised healing response.

Clinical, radiographic and tomographic examination indicated buccal plate loss of the upper right central incisor with unfavorable prognosis (Figures 1a, b, and c). There was disharmony in gingival margin and asymmetry in the anterior region. The right central incisor was positioned more labially compared to the left central incisor. The right central incisor showed a clinical mobility labially and lingually, respectively. Tooth extraction and immediate implant placement with synthetic anorganic hydroxyapatite graft of the right central incisor and acrylic provisional bridge including the four maxillary incisors were proposed as initial treatment. After evaluation and development of a treatment plan, the patient was given a detailed explanation concerning the present state, alternative treatment plans, the proposed procedures, and then an informed consent was obtained from the patient which signed the Free Informed Consent Form for the presentation and/or publication of the case which was submitted and approved in accordance with the standards of CONEP*

*PLATR protocol number 035129/2015
CAAE: 44436215.2.0000.5279

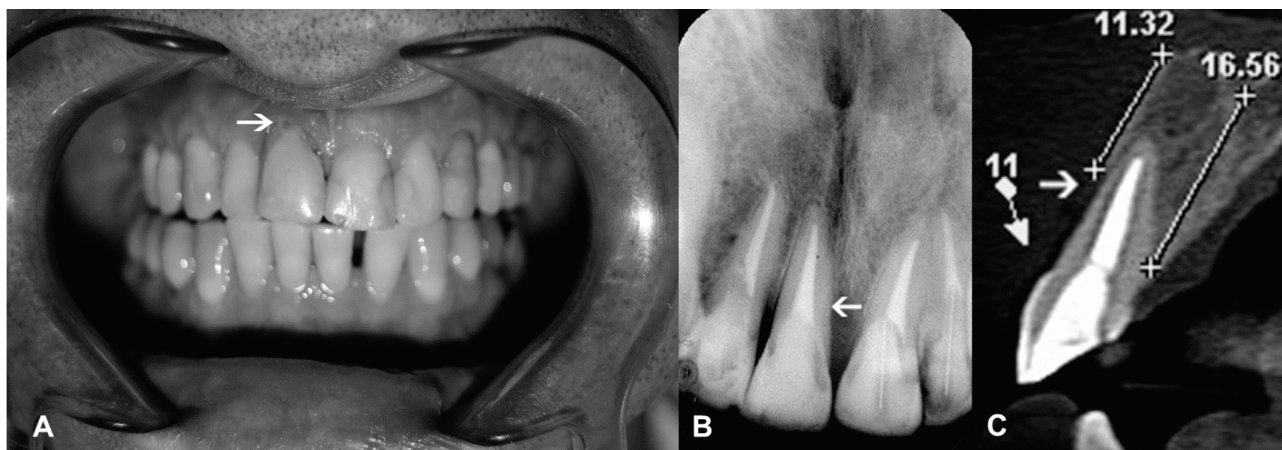


Figure 1 - A: clinical, B: radiographic and C: tomographic diagnosis of bone loss due to periodontal disease and traumatic mobility of the right upper incisor

Surgical Procedure

Treatment with immediate placement of dental implant was planned after precise consultation. Immediately before the procedure, the patient rinsed for 2 minutes with a 0.12% chlorhexidine digluconate solution (Hexamedine, Bukwang, Seoul, Korea). Following an injection of 2% lidocaine with 1:100 000 epinephrine local anesthetic, the crown portion and the residual roots were atraumatically removed. The extraction socket was thoroughly debrided and degranulated to remove all tissue. A surgical template was used to locate the desired implant position, but it showed that installing the implant at the desired position might compromise the initial stability and the esthetic result. Consequently, ridge expansion with an osteotome was done before implant installation. The site was prepared to accept a conic Hex 4.1 x 18 mm screw implant (Tryon, Sin, São Paulo, Brazil). The implant was placed lingually in relation to incisal line and flush to the bone margin, with the insertion torque of 40 N.cm (Figure 2a) and its platform protected by a 5 x 4 mm healing cover divergent screw (Sin, São Paulo Brazil). Marginal voids about 1.0 mm wide were noted between the implant surface and the buccal cortex (Figure 2b). The buccal surface and marginal voids were grafted with synthetic anorganic hydroxyapatite (Osteogen, Intra-lock,) and covered the occlusal surface completely. Undermining of mucoperiosteal tissue was

performed to cover the graft material and implant without tension. Despite the gold standard in esthetic root replacement by immediate implants is to place an immediate abutment and temporary crown to achieve a better response of soft and hard surrounding tissues, we decided that in this particular case it would be too risky, due to the great loss of bone, mainly in the buccal cortex observed after tooth extraction. Because of this, a provisional acrylic stock crown was fixed to adjacent incisors with orthodontic wire and composite resin in order to provide esthetic and function during the healing and osseointegration period to avoid any occlusal charges into the implant. The wound was closed by means of single sutures (Ethicon, Johnson and Johnson Medical Inc, Arlington, Tex) [11-13].

Postoperative Management

The patient was placed on amoxicillin 500 mg + clavulanic acid 125 mg 3/day for 6 days, diclofenac sodium 100 mg 2/day for 3 days, and chlorhexidine digluconate 0.12% 3/day for 4 weeks. He was asked not to chew on or brush the surgical area for the first 4 weeks postoperatively. The patient was shown how to perform a roll-stroke brushing technique, and oral hygiene reinforcement was performed at each visit. The patient reported no specific symptoms and showed no adverse clinical signs. Healing was uneventful until three months of postoperative radiographic control (figure 2c) [14].

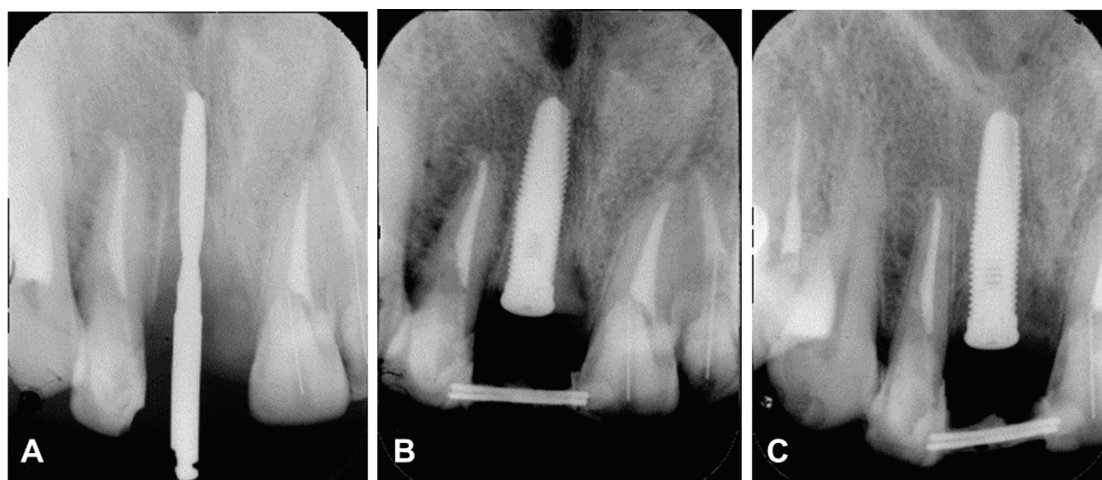


Figure 2 - A and B: atraumatic extraction and immediate implant placement into the incisor socket, and C: three months postoperative radiographic control

Tooth Fracture

Just over three months after the installation of the first implant, the patient presented root fracture of the adjacent upper left central incisor due to domestic accident. Figure 3a shows the 3-month postoperative radiograph of hard and soft tissue healing of the implant and oblique fracture between crown and root of the adjacent central incisor and without any apparent damage or commitment of the surrounding tissues, such as gum, bone crest and the first installed implant. Because of this new situation, the same surgical procedure was planned and performed to replace the fractured tooth by a similar implant screw

already installed. A new conic Hex 4.1 x 18 mm screw implant (Tryon, Sin, São Paulo, Brazil) was placed respecting the biological spaces, i. e., lingually in relation to incisal line, more than 1.5 mm within teeth and more than 3 mm between the two implants, with the insertion torque of 40 N.cm and its platform protected by a 5 x 4 mm divergent healing cover screw (Sin, São Paulo Brazil). The two adjacent maxillar incisors were previously prepared to receive full acrylic provisional crowns and after the surgical procedure, a four incisors provisional bridge was placed. The provisional bridge was adjusted to clear centric and eccentric contacts and to reshape the natural gingival contour [15,16] (Figure 3b and c).

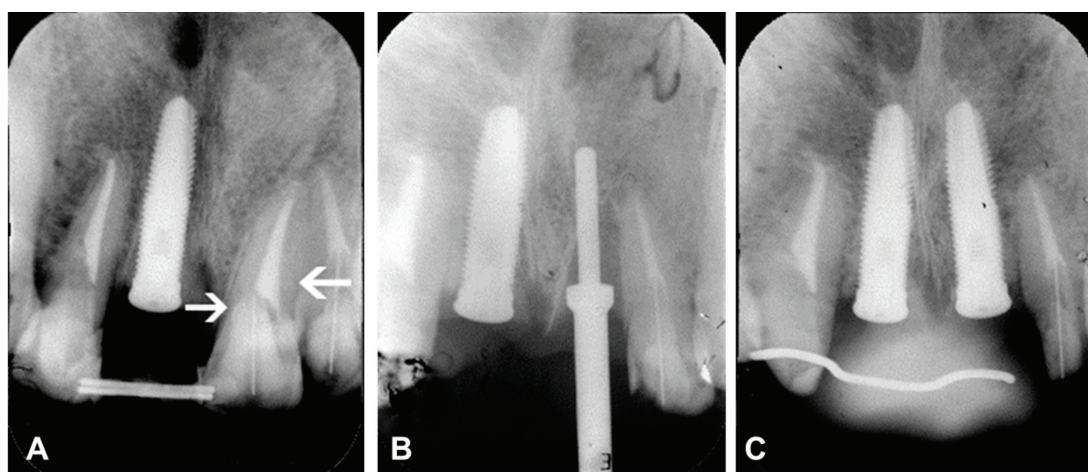


Figure 3 - A: Oblique fracture between crown and root of the left central incisor; B: atraumatic extraction and immediate second implant placement into the left upper incisor socket, and C: Three months postoperative radiographic control after the second implant surgery

Trans-operative esthetic procedures

After the second implant installation, cosmetic restorations and tooth bleaching were performed in order to improve esthetics during osseointegration period. (Figure 4a, b and c).

Prosthetic Procedures and follow-up

Six months after the installation of the second implant, selection of appropriate individual and customized zirconia abutments designed and performed by CAD-CAM process were done after

evaluating the bone level and gingival thickness reached by convenient gingival conditioning performed by four new individual acrylic resin provisional crowns. The use individual zirconia abutments helped us to achieve better esthetic results because of its better optic properties and to improve emergence profile of the crowns. Next to the achievement of proper gingival contouring and shape, the four provisional crowns were replaced by four permanent cemented crowns of metal free ceramic IPS e.max Ceramill ZI Aman Girschbach.

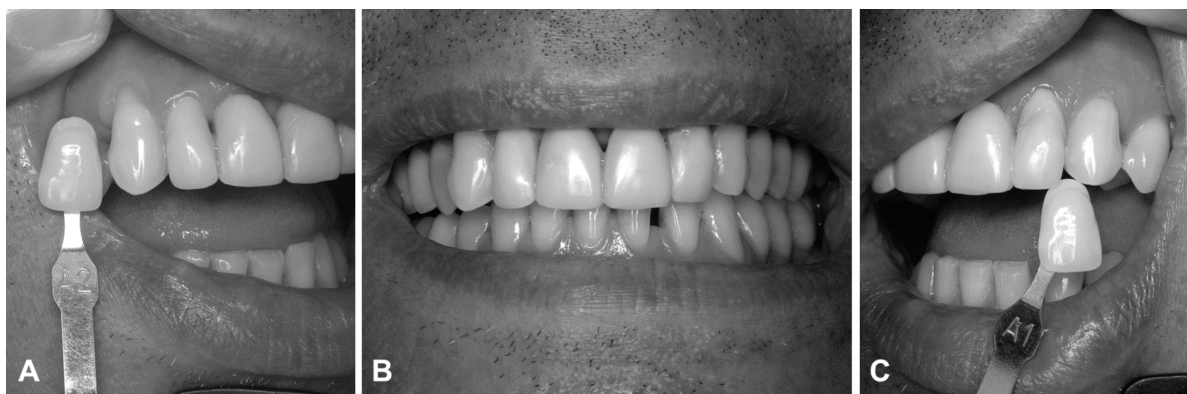


Figure 4 - A: color selection for tooth bleaching procedure, B: four incisors anterior provisional bridge for gingival conditioning and C: color conference after tooth bleaching

The postoperative width of ridge and keratinized tissue was evaluated on the buccal side. Symmetry of gingival margin contour was achieved with complete fill of the interdental space between central incisors with a complete neoformation of the papilla as shown in figure 5a, b and c [17]. The transfer molding technique used

in this case was open tray with Polyvinyl Siloxane (President, Coltène Switzerland). Proper gingival contour was achieved by mediate and continued gingival conditioning by increasing the individuals acrylic provisional crowns in each appointment till the achievement of ideal soft and hard tissue contour.

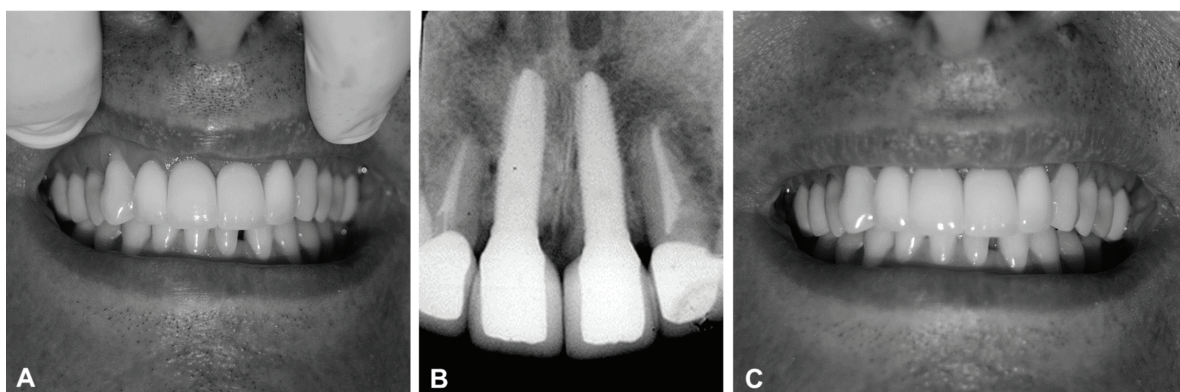


Figure 5 - A: postoperative clinical gingival margin contour and papilla after cementation of four metal-free crowns, B: postoperative radiographic control 32 months after the first and 29 after the second implant surgery, and C: clinical aspect after 29 months of follow-up

DISCUSSION AND CLINICAL RESULTS

Immediate implant placement into fresh anterior sockets has been a very effective therapy not only to avoid several alveolar bone resorptions but to fulfill and recover esthetic requirements mainly in maxilla. Complications in anterior teeth such as advanced periodontal disease, chronic periapical infections and root fractures require immediate and urgent procedures by all professionals involved in order to provide a predictive solution to these clinical situations. This requires a very precise indication and demands appropriate clinical preoperative and trans-operative procedures like atraumatic tooth extraction, meticulous care in cleaning and debridement of the alveolar bone socket, and

previous antibiotic administration before placing the endosseous implant for replacement of lost anterior teeth [18].

Another important criteria that may be considered is to achieve the right and desired placement of the implant itself, lingually in relation to incisal line and flush to the bone margin, assuring the initial stability with the insertion torque of 40 N.cm and respecting the recommended minimum horizontal biological distances between two adjacent implants (more than 3 mm), between implant and adjacent natural teeth root (more than 1,5 mm) and between implant and buccal and lingual bone ridges (more than 1 mm) as suggested by the authors Rodriguez et al. [19] Fradeani [20] and Rocha et al. [21] (Figure 6a-6g).

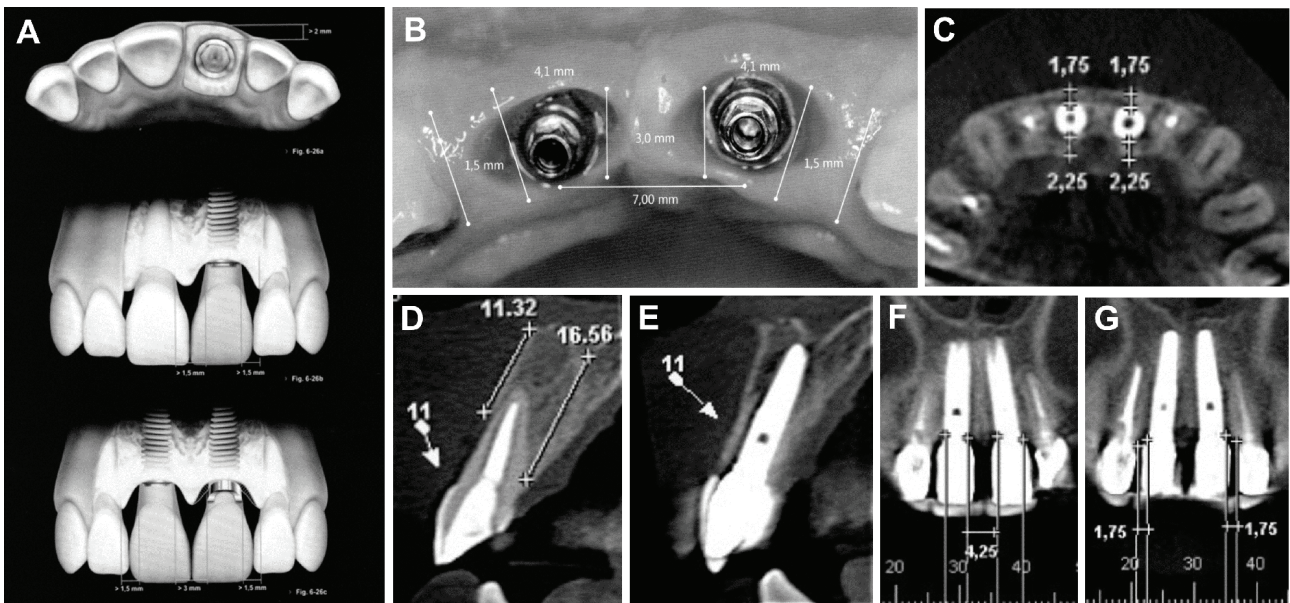


Figure 6 - A: Fradeani [20] adapted schedule of ideal biological distances between implant and natural tooth and between two adjacent implants, B: Rocha et al. (21) adapted schedule of ideal biological distances between implant and natural tooth and two adjacent implants, and C to G: special tomography images showing the bone ridge augmentation achieved and the biological distances of this case report

Several types of prosthetic platforms are available such as external and internal hexagon, Morse taper connection, and the concept of platform switching. Some authors stated that the most suitable type of platform for aesthetic areas is the Morse taper connection [22]. Wang et al. [23]

found no difference in bone loss between crestally and subcrestally placed implants for both external hexagon and Morse taper abutment connections. Conversely a 2 year study by Crespi et al. [24] which compared external hexagon regular platform implants to platform switched implants placed

in fresh extraction sites and immediately loaded, showed no difference in bone loss. The authors decided to use external hexagon regular platform implants in this report due to the great expertise with the technique, combined with accessible and wide cost availability of prosthetic resources, which makes it the best selling platform in the country, and the fact that their clinical esthetic behavior and outcomes are similar to the other types of platforms. Indeed, after 29 months of clinical, radiographic and tomographic follow-up, the authors attribute the success of the case through the precise and strict spatial position of the two adjacent implants, placed lingually in relation to incisal line and flush to the bone margin with bone ridge augmentation observed in all interfaces between implants and

the adjacent teeth in this esthetically challenging situation. The establishment of a peri-implant hard and soft tissue contour with intact papilla and gingival margins was always a major esthetic concern. The best gingival contour was reached due to continuous and periodical conditioning of the surrounding tissues by the addition of acrylic resin during the use of individual provisional crowns which lasted thereabout six months and was considered essential to achieve an aesthetically favorable outcome. The harmony of soft and hard tissue achieved helped a lot in giving back function and self-esteem to the patient. (Figure 7). Further evaluation is needed to monitor hard and soft tissue possible changes on a very long-term basis.

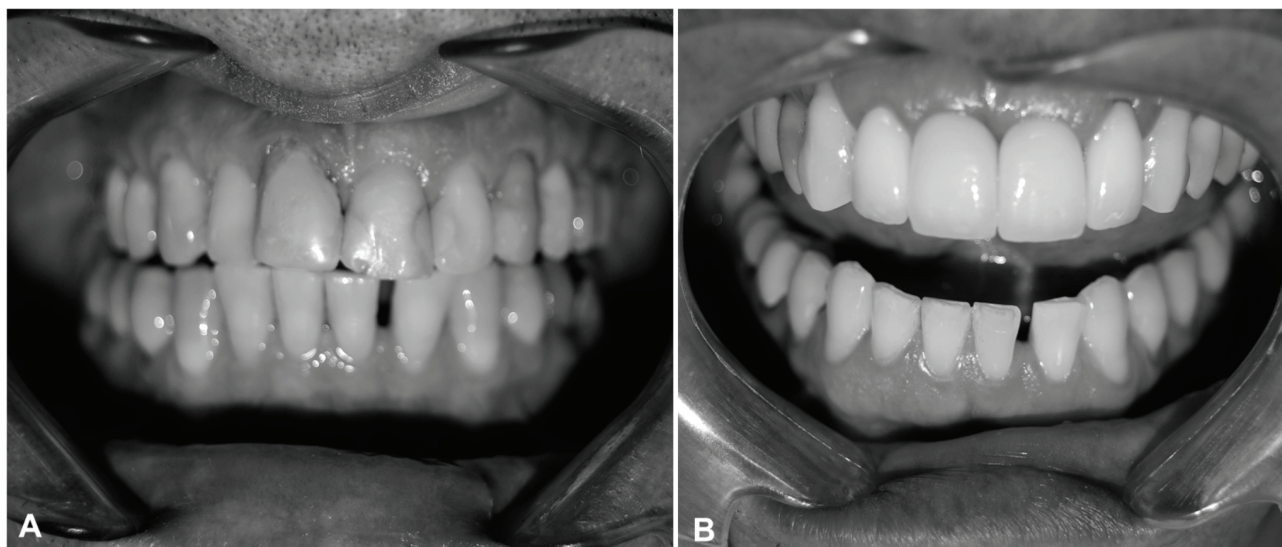


Figure 7 - A: clinical aspect of the first visit of the patient, and B: clinical aspect, 32 months after

REFERENCES

1. Novaes AB Jr, Novaes AB. Immediate Implant placed into infected sites: a clinical report. *Int J Oral Maxillofac Implants*. 1995 Sep-Oct;10(5):609-13.
2. Crespi R, Capparé P, Gherlone E, Romanos GE. Immediate Versus Delayed Loading of Dental Implants Placed in Fresh Extraction Sockets. in the Maxillary Esthetic Zone: A Clinical Comparative Study. *Int J Oral Maxillofac Implants*. 2008 Jul-Aug;23(4):753-8.
3. Kan JYK, Rungcharassaeng K, Lozada JL, Zimmerman G. Facial Gingival Tissue Stability Following Immediate Placement and Provisionalization of Maxillary Anterior Single Implants: A 2- to 8-Year Follow-up. *Int J Oral Maxillofac Implants*. 2011 Jan-Feb;26(1):179-87.
4. Petropoulou A, Pappa E, Pelekanos S. Esthetic considerations when replacing missing maxillary incisors with implants: A clinical report. *J Prosthet Dent*. 2013 Mar;109(3):140-4. doi: 10.1016/S0022-3913(13)00056-5.
5. Cristalli MP, Marini R, Monaca GL, Sepe C, Tonoli F, Annibaldi S. Immediate loading of post-extractive single-tooth implants: a 1-year prospective study. *Clin Oral Implants Res*. 2015 Sep;26(9):1070-9. doi: 10.1111/clr.12403.
6. Misje K, Bjørnland T, Saxegaard E, Janicke LJ. Treatment Outcome of Dental Implants in the Esthetic Zone: A 12- to 15-Year Retrospective Study. *Int J Prosthodont*. 2013 Jul-Aug;26(4):365-9. doi: 10.11607/ijp.3097.

7. Mura P. Immediate Loading of Tapered Implants Placed in Postextraction Sockets: Retrospective Analysis of the 5-Year Clinical Outcome. *Clin Implant Dent Relat Res.* 2012 Aug;14(4):565-74. doi: 10.1111/j.1708-8208.2010.00297.x.
8. Chen MC, Liao YF, Chan CP, Ku YC, Pan WL, Tui YK. Factors Influencing the Presence of Interproximal Dental Papillae Between Maxillary Anterior Teeth. *J Periodontol.* 2010 Feb;81(2):318-24. doi: 10.1902/jop.2009.090361.
9. Nisapakultorn K, Suphanantachai S, Silkosessak O, Rattanamongkolgul S. Factors affecting soft tissue level around anterior maxillary single-tooth implants. *Clin Oral Implants Res.* 2010 Jun;21(6):662-70. doi: 10.1111/j.1600-0501.2009.01887.x.
10. Starr NL. The extraction socket and the dental implant restoration. *Alpha Omegan.* 2014 Summer;107(2):16-27.
11. Misch CE. *Prótese sobre implantes.* São Paulo: Santos; 2007.
12. Cho HL, Lee JK, Um HS, Chang BS. Esthetic evaluation of maxillary single-tooth implants in the esthetic zone. *J Periodontal Implant Sci.* 2010 Aug;40(4):188-93. doi: 10.5051/jpis.2010.40.4.188.
13. Park JB. Immediate placement of dental implants into fresh extraction socket in the maxillary anterior region: a case report. *J Oral Implantol.* 2010;36(2):153-7. doi: 10.1563/AAID-JOI-D-09-00045.
14. Visser A, Raghoobar GM, Meijer HJA, Meijndert L, Vissink A. Care and aftercare related to implant-retained dental crowns in the maxillary aesthetic region: a 5-year prospective randomized clinical trial. *Clin Implant Dent Relat Res.* 2011 Jun;13(2):157-67. doi: 10.1111/j.1708-8208.2009.00196.x.
15. Tymstra N, Raghoobar GM, Vissink A, Meijer HJA. Dental implant treatment for two adjacent missing teeth in the maxillary aesthetic zone: a comparative pilot study and test of principle. *Clin Oral Implants Res.* 2011 Feb;22(2):207-13. doi: 10.1111/j.1600-0501.2010.02017.x.
16. Di Alberti L, Donnini F, Alberti CD, Camerino M, Sgaramella N, Muzio LL. Clinical and Radiologic Evaluation of 70 Immediately Loaded Single Implants in the Maxillary Esthetic Zone: Preliminary Results After 1 Year of Functional Loading. *Int J Oral Maxillofac Implants.* 2012 Jan-Feb;27(1):181-6.
17. Vanlıoğlu BA, Kahramanoğlu E, Özkan Y, Kulak-Özkan Y. Clinical and Radiographic Evaluation of Early Loaded Maxillary Anterior Single-Tooth Bone-Level Implants. *Int J Oral Maxillofac Implants.* 2014 Nov-Dec;29(6):1369-73. doi: 10.11607/jomi.3446.
18. Naves MM, Horbilonbz, Gomes CF, Menezes HHM, Bataglion C, Magalhães D. Immediate Implants Placed into Infected sockets: A Case Report with 3-year Follow-up. *Braz Dent J.* 2009;20(3):254-8.
19. Rodriguez AM, Rosenstiel SF. Esthetic considerations related to bone and soft tissue maintenance and development around dental implants: Report of the Committee on Research in Fixed Prosthodontics of the American Academy of Fixed Prosthodontics. *J Prosthet Dent.* 2012 Oct;108(4):259-67. doi: 10.1016/S0022-3913(12)60174-7.
20. Fradeani M. *Análise estética: Uma abordagem sistemática para o tratamento protético.* Volume 1. São Paulo: Quintessence; 2006.
21. Rocha PV. *Todos os passos da prótese sobre implante: do planejamento ao controle posterior.* São Paulo: Napoleão; 2013.
22. Mangano FG, Mangano C, Ricci M, Sammons RL, Shibli JA, Piattelli A. Single-tooth Morse taper connection implants placed in fresh extraction sockets of the anterior maxilla: an aesthetic evaluation. *Clin Oral Implants Res.* 2012 Nov;23(11):1302-7. doi: 10.1111/j.1600-0501.2011.02307.x.
23. Weng D, Nagata MJ, Bell M, de Melo LG, Bosco AF. Influence of microgap location and configuration on peri-implant bone morphology in nonsubmerged implants: an experimental study in dogs. *Int J Oral Maxillofac Implants.* 2010 May-Jun;25(3):540-7.
24. Crespi R, Cappare P, Gherlone E. Radiographic evaluation of marginal bone levels around platform-switched and non-platform switched implants used in an immediate loading protocol. *Int J Oral Maxillofac Implants.* 2009 Sep-Oct;24(5):920-6.

George Miguel Spyrides
(Corresponding address)

Rua Prof. Rodolpho Paulo Rocco 325 / 2º andar
Ilha da Cidade Universitária - Rio de Janeiro - RJ - Brasil
CEP: 21.941-913
E-mail: georgems@odonto.ufrj.br

Date submitted: 2017 Feb 21

Accept submission: 2017 May 09