



Prevalence of soft tissue calcifications in cone beam computed tomography images in the region of head and neck

Prevalência de calcificações de tecidos moles em exames de tomografia computadorizada de feixe cônico

Vandenberg DINIZ¹, Elaine Cristina de Carvalho Beda Corrêa de ARAÚJO¹, Bianca Costa GONÇALVES¹, Karolina Aparecida Castilho FARDIM¹, Luiz Roberto C MANHÃES JUNIOR¹, Estela Kaminagakura TANGO², Isis Patricia Soares da Silva¹, Sérgio Lúcio Pereira Castro LOPES¹

1 - São Paulo State University (Unesp) – Institute of Science and Technology, São José dos Campos –Department of Diagnosis and Surgery - São José dos Campos - SP - Brazil.

2 - São Paulo State University (Unesp) – Institute of Science and Technology, São José dos Campos – Department of Biosciences and Oral Diagnosis - São José dos Campos - SP - Brazil.

ABSTRACT

Objective: to evaluate the prevalence of calcifications in the soft tissues of the cervical-facial region using cone beam computed tomography (CBCT) images.

Material and Methods: two hundred and ten CBCT exams was analyzed by 01 examiner previously trained, with field of view (FOV) of 16 x 13 cm and voxel of 0.25 mm, in ICAT Vision software (Imaging Science International, Hatfield, PA, USA) in coronal, axial and sagittal sections. The following calcifications were evaluated: tonsiloliths, sialoliths, calcification of the styloid complex, calcified carotid atheromas, calcifications in laryngeal cartilages, calcified lymph nodes and osteoma cutis. The findings were tabulated according to the total of the sample, related to the gender, age group of the individuals.

Results: Calcification of the styloid complex was the most frequent in the sample studied in both genres (39.04%), followed by the presence of tonsiloliths (19.52%), and calcified lymph nodes (6,67%).

Conclusion: calcifications are frequent radiographic findings in CBCT and important for the diagnosis of some possible pathologies that do not present clinical symptoms.

KEYWORDS

Cone-beam computed tomography; Prevalence; Soft tissue calcification.

RESUMO

Objetivo: avaliar por meio de imagens de tomografia computadorizada de feixe cônico (TCFC) a prevalência de calcificações em tecidos moles da região cérvico-facial. **Material e Métodos:** os exames foram avaliados por um examinador, previamente treinado que avaliou 210 exames de TCFC, com campo de visão (FOV) de 16 x 13 cm e voxel de 0,25 mm. Os exames foram avaliados no software ICAT Vision (Imaging Science International, Hatfield, PA, Estados Unidos da América) em cortes coronais, axiais e sagitais. As seguintes calcificações foram avaliadas: tonsilólitos, sialólitos, calcificação do complexo estiloide, atheromas da carótida calcificados, calcificações na cartilagens laríngeas, nódulos linfáticos calcificados e osteoma cútis. Os achados foram tabulados de acordo com o total da amostra, relativos ao gênero e faixa etária dos indivíduos. **Resultados:** a calcificação do processo estiloide foi a mais frequente na amostra estudada em ambos os sexos, seguido da presença dos tonsilólitos e linfonodos calcificados. **Conclusão:** as calcificações de tecidos moles são achados radiográficos frequentes na TCFC e importantes para diagnósticos de algumas possíveis patologias que não apresentam sintomatologia clínica.

PALAVRAS-CHAVE

Tomografia computadorizada de feixe cônico; Prevalência; Calcificação.

INTRODUCTION

Calcification is a biochemical phenomenon, characterized by the deposition of calcium salts, mainly calcium phosphate, in a certain region of the organism [1-3]. However, when it occurs disorganized in soft tissues, it is referred to as heterotopic calcification, which can be divided into three: dystrophic, idiopathic and metastatic [1,2].

Soft tissue calcifications in the head and neck region are usually incidental radiographic findings and with the advent of concomitant Cone Beam Computed Tomography (CBCT), they are more frequently encountered, since it consists of a diagnostic imaging method which allows the visualization of structures in three planes, accurately identifying and becoming an indication for diagnosis [4-6].

The analysis of CBCT location requires knowledge of the soft tissue anatomy involved, such as the position of lymph nodes, styloid ligaments, blood vessels, cartilages of the larynx and major ducts of the salivary glands. Important points should be considered in order to arrive at a correct interpretation such as the anatomical location, the number, the distribution and the shape of the calcifications. Some soft tissue calcifications do not require any intervention or long-term follow-up, while others may pose a threat to life and their main cause must be treated. [7-9].

In this context, the present study aimed to evaluate the prevalence of the following calcifications in soft tissues, tonsilloliths, sialoliths, calcification of the styloid complex, calcified carotid atheromas, calcifications in laryngeal cartilages, osteoma cutis and calcified lymph nodes, using cone beam computed tomography (CBCT) images.

MATERIAL AND METHODS

For this research, 210 CBCT exams belonging to the archive of the Radiology Clinic of the Institute of Science and Technology (ICT-UNESP) were selected and obtained

approval by the Research Ethics Committee (protocol 48801215.1.0000.0077).

The inclusion criteria were: (I) both age groups and genders; (II) presented good image quality; acquired with the FOV (field of view) of 16x13 cm and voxel of 0.25 mm, which in this way registered the middle and lower 1/3 of the face, mandible and upper cervical portion. Exclusion criteria were: (I) the tests that did not present the FOV described in the inclusion criteria or that presented poor image quality (presence of patient movement artifacts); (II) the presence of fractures, surgical interventions such as orthognathic surgeries and neoplasias that affect maxillofacial structures. The CBCT images were analyzed in the i-CAT Vision software, belonging to the tomographic acquisition system and evaluated in the MPR (multiplanar reconstruction) screen, which simultaneously displays the coronal, axial and sagittal sections of the region.

The evaluator, duly trained in the analysis and manipulation of the software, had free access to the system tools such as alteration of brightness, contrast, application of filters, zoom tool, to aid in image quality and diagnosis. The analysis of the images obeyed the protocol (Table I).

Table I - Soft tissue calcifications protocol for analysis

Calcification Hyohyoid Complex	Evaluated in the coronal and sagittal MPR, taking into account that the styloid process above 3.0 cm in length (measured in said windows, with the tool "distance"). Considering the possible presence of calcification during the course of the style-hyoid and mandibular ligaments, which considered as segmented calcifications (Figure 1).
Tonsillolith	Examined in axial and coronal sections and were considered as hyperdense images, irregular and precise borders, located in the parapharyngeal regions.
Sialoliths	Three anatomical planes were evaluated, analyzing the presence of irregular hyperdensities in the submandibular, sublingual and parotid regions.
Calcified carotid artery atheroma	Calcification was considered presence of hyperdense images in the carotid regions, observed in axial sections, corresponding to the C3-C4 pre-vertebral region (Figure 2).
Calcified lymph nodes	Axial and coronal sections were evaluated, where the presence of irregular, hyperdense, lobulated images (described as cauliflower) corresponding to the cervical and submandibular regions was considered. sialoliths, with the criterion of presence of lobular aspect as a determinant of calcified lymph node (Figure 3).
Calcifications in the laryngeal cartilages	Hyperdensities were observed in the regions corresponding to the laryngeal cartilages, that is, in the anterior region the upper pharyngeal air space and close to the major horn of the hyoid bone
Osteoma cutis	Multiple punctiform calcifications in the regions corresponding to facial subcutaneous tissue.

For statistical purposes, data were analyzed and all the findings were tabulated, taking into account the incidence side, gender, age group of individuals and types of dystrophic, idiopathic and metastatic calcification, being submitted to descriptive statistics.

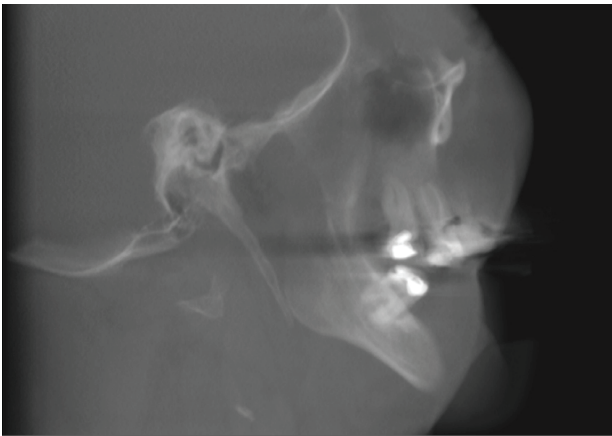

Figure 1 - Sagittal section of the cone beam computed tomography showing the calcification of the styloid process.

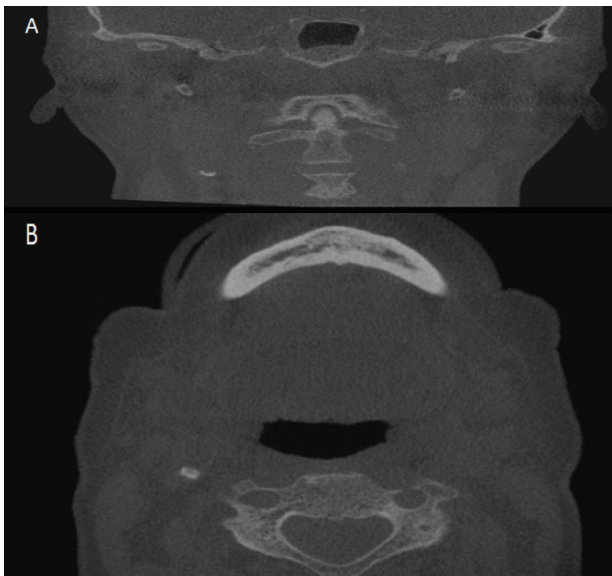


Figure 2 - Coronal section (A) and axial section (B) of the cone beam computed tomography showing the calcified carotid artery atheroma.

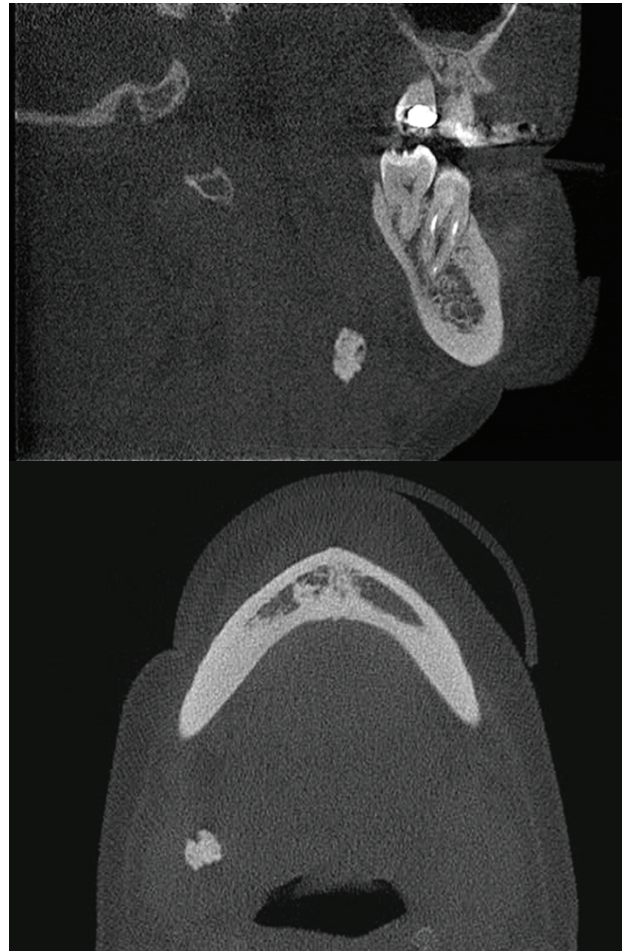

Figure 3 - Sagittal views (A) and axial views (B) of the cone beam computed tomography showing the calcified lymph nodes.

RESULTS

Observed that of the 210 analyzed samples, 144 examinations (68.57%) presented soft tissue calcifications (Figure 4). When analyzing the prevalence among the three classifications of calcifications, it was observed that the metastatic calcification presented the highest prevalence, followed by the dystrophic calcification and the idiopathic calcification.

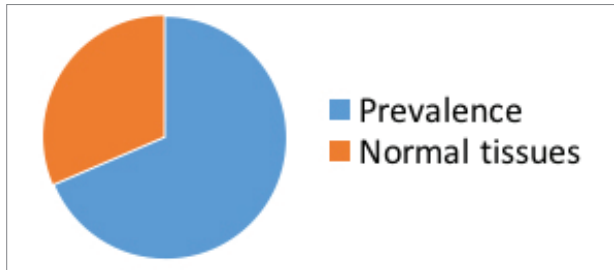


Figure 4 - Prevalence of calcifications the total sample.

Considering the total sample, 131 were female patients (62.38%) and 79 male patients (37.62%). The most frequent types of calcifications analyzed by gender were the hyoid-styles complex and the presence of tonsiloliths (Table II).

Table II - Prevalence of soft tissue calcifications: styloid complex and tonsiloliths, considering frequency in males and females

Soft tissue calcification	Males %	Females %
Styloid complex	45,57	35,11
Tonsiloliths	21,51	18,32

When checking the frequency between calcifications, the following results on table III. The age group that presented the most calcification was 31 to 50 years of age.

Table III - Soft tissue calcifications, Total, total%, Right (R), Left (L) and Bilateral, prevalent age group.

Soft tissue calcification	Total	Total %	R %	L %	Bilateral %	Age group
Styloid complex	82	39,04	3,29	6,10	29,58	31-50
Tonsiloliths	41	19,52	3,29	4,69	11,27	31-50
Calcified lymph nodes	14	6,67	6,57	-	-	31-50
Carotid artery calcifications	10	4,76	0,0	0,47	2,82	51-70
Sialoliths	1	0,47	0,47	-	-	31-50

Being that the age group from 51 to 70 years of age obtained the greatest presence of carotid artery calcifications (Table IV).

Table IV - Prevalence of soft tissue calcifications by age group.

Age group	N	Percentual (%)
10-30	14	6,57
31-50	70	32,83
51-70	57	26,76
71-80	5	2,34

In this study, no cases of calcification were found in the laryngeal cartilage and calcinosis cutis.

DISCUSSION

Soft tissue calcifications are incidental and sometimes frequent radiographic findings in CBCT exams [4,6,7], and there is a consensus in the literature about the accuracy and the ability to detect small cranial soft tissue structures [4,6,8].

Therefore, due to the prevalence of these calcifications, it is important to emphasize and recognize these changes more assertively [2,5,10]. However, the great advantage of the CBCT becomes its greatest challenge, because the images are three-dimensional, due to the lack of training of professionals in the area of dentistry for its correct interpretation, errors can occur due to the non-recognition of lesions or pathologies. In this study, the evaluator was trained to verify the prevalence of soft tissue calcifications, which were present in routine patients, who obtained the CBCT examination.

The highest frequency occurred in metastatic calcifications of the stylohyoid complex [2,9,11,12]. Metastatic calcifications occur due to the increase of levels of calcium ions in the blood stream, which may result from the removal of these ions from bones, common in situations of hyperparathyroidism, hypervitaminosis D or bone inflammations and due to the excess of these ions in the diet [7,8]. Frequency was also present in both genders and in the age group from 31 to 50 years.

The second most prevalent calcification in this sample, dystrophic calcification, showed a higher amount of tonsilloliths, followed by lymph nodes and carotid atheroma, according to other studies [9,11]. Dystrophic calcifications occur when there is insufficient blood supply and necrotic and ischemic tissues are present, although serum calcium and phosphate levels are normal [4,6].

In the detection of carotid atheroma, some authors agree that the major importance of this diagnosis is to avoid the occurrence of a stroke [10,13,14]. Calcified carotid atheromas were present in 4.76% of the total sample, in the age range of 51 to 70 years. These changes require treatment, and since the calcification of the carotid artery is silent, it may be reported after a routine examination. It is important to evaluate other signs and symptoms to confirm the diagnosis, and it is necessary to differentiate the atheroma of the carotid artery from calcifications, such as thyroid cartilage, calcified lymph nodes, sialoliths and phleboliths [15-17].

The type of calcification that presented the third highest incidence was idiopathic. Idiopathic calcifications, although the individual presents normal levels of blood calcium, there is deposition of calcium in healthy tissues [4]. Sialoliths were present in 0.47% of the sample, the incidence was not significant, however according to other studies [10], these mostly occur [18- 20]. The age group with the highest prevalence of sialoliths was 31 to 50 years. These calcifications can present pain, also need treatment. Sometimes other types of complementary tests may be needed. Already osteoma cutis, this is a rare benign condition in which soft tissue calcifications occur in the dermis layer of the skin [21], and were not detected in this study.

CONCLUSION

Soft tissue calcifications presented expressive prevalence in the studied sample. The calcification of the metastatic type

(calcification of the styloid complex) showed the highest prevalence in the analysed sample. Some calcifications do not need treatment; however, the professional dental surgeon should be alert and check the routine exams to detect such calcifications.

REFERENCES

1. Jacome AMSC, Abdo EN. Aspectos radiográficos das calcificações em tecidos moles da região bucomaxilofacial. *Odontol Clín Cient*. 2010;9(1):25-32.
2. Centurion BS, Imada TS, Pagin O, Capelozza AL, Lauris JR, Rubira-Bullen IR. How to assess tonsilloliths and styloid chain ossifications on cone beam computed tomography images. *Oral Dis*. 2013;19(5):473-8. doi: 10.1111/odi.12026.
3. Nunes LFS, Santos KCP, Junqueira JLC, Oliveira JX. Prevalence of soft tissue calcifications in cone beam computed tomography images of the mandible. *Rev. Odonto Ciênc. [Internet]*. 2011 [cited 2018 set 10];26(4):297-303. doi: 10.1590/S1980-65232011000400004. Available from: http://www.scielo.br/scielo.php?script=sci_arttext&pid=OS1980-65232011000400004&lng=en&nrm=iso.
4. Lopes IA, Tucunduva RMA, Handem RH, Capelozza ALA. Study of the frequency and location of incidental findings of the maxillofacial region in different fields of view in CBCT scans. *Dentomaxillofac Radiol*. 2017;46(1):20160215.
5. Kumar M, Shanavas M, Sidappa A, Kiran M. Cone beam computed tomography - know its secrets. *J Int Oral Health*. 2015;7(2):64-8.
6. Price JB, Thaw KL, Tyndall DA, Ludlow JB, Padilla RJ. Incidental findings from cone beam computed tomography of the maxillofacial region: a descriptive retrospective study. *Clin Oral Implants Res*. 2012 Nov;23(11):1261-8. doi: 10.1111/j.1600-0501.2011.02299.x
7. Khojastepour L, Haghnegahdar A, Sayar H. Prevalence of soft tissue calcifications in cbct images of mandibular region. *J Dent (Shiraz)*. 2017 Jun;18(2):88-94.
8. Barghan S, Tahmasbi Arashlow M, Nair MK. Incidental findings on cone beam computed tomography studies outside of the maxillofacial skeleton. *Int J Dent*. 2016; 2016:9196503. doi:10.1155/2016/9196503.
9. Missias EM, Nascimento E, Pontual M, Pontual AA, Freitas DQ, Perez D. et al. Prevalence of soft tissue calcifications in the maxillofacial region detected by cone beam CT. *Oral Dis*. 2018;24(4):628-37. doi: 10.1111/odi.12815.
10. Wells AB. Incidence of soft tissue calcifications of the head and neck region on maxillofacial cone beam computed tomography [thesis]. Louisville : University of Louisville; 2011. Available from: <http://ir.library.louisville.edu/cgi/viewcontent.cgi?article=02544&context=Oetd>.
11. Çağlayan F, Sümbüllü MA, Miloğlu Ö, Akgül HM. Are all soft tissue calcifications detected by cone-beam computed tomography in the submandibular region sialoliths? *J Oral Maxillofac Surg*. 2014 Aug;72(8):1531e1-6. doi: 10.1016/j.joms.2014.04.005.
12. Dreiseidler T, Ritter L, Rothamel D, Neugebauer J, Scherr M, Mischkowski RA. Salivary calculus diagnosis with 3-dimensional cone-beam computed tomography. *Oral Surg Oral Med Oral Pathol Oral Radiol Endod*. 2010 Jul; 110(1):94-100. doi: 10.1016/j.tripleo.2010.03.013.
13. Carter LC. Discrimination between calcified triticeous cartilage and calcified carotid atheroma on panoramic radiography. *Oral Surg Oral Med Oral Pathol Oral Radiol Endod*. 2000; 90(1):108-10.

14. Damaskos S, Silveira HLD, Berkhout EWR. Severity and presence of atherosclerosis signs within the segments of internal carotid artery: CBCT's contribution. *Oral Surg Oral Med Oral Pathol Oral Radiol.* 2016 Jul; 122(1):89-97. doi: 10.1016/j.oooo.2016.03.017.
15. Ramadan SU, Gokharman D, Kosar P, Kosar U. The stylohyoid chain: CT imaging. *Eur J Radiol.* 2010;75(3):346-51. doi: 10.1016/j.ejrad.2010.04.021
16. Magat G, Ozcan S. Evaluation of styloid process morphology and calcification types in both genders with different ages and dental status. *J Istanbul Univ Fac Dent.* 2017; 51(2):29-36. doi:10.17096/jiufd.35768.
17. Misirlioglu M, Nalcaci R, Adisen MZ, Yardimci S. Bilateral and pseudobilateral tonsilloliths: Three-dimensional imaging with cone-beam computed tomography. *Imaging Sci Dent.* 2013 Sep;43(3):163-9. doi: 10.5624/isd.2013.43.3.163
18. Soares MQS, Castro RC, Santos PSS, Capelozza ALA, Fischer Bullen IRR. Contribuição da radiografia panorâmica no diagnóstico de calcificação de ateroma de carótida: relato de caso e revisão da literatura. *Rev Port Estomatol Cir Maxilofac.* 2015. Abril-Jun 56(2):127-31. <https://doi.org/10.1016/j.rpemd.2015.04.011>.
19. Bienstock D, Goodenough M, Silva C et al. Is diagonal ear lobe crease associated with carotid calcifications on panoramic radiograph or cone beam computed tomography? *J Oral Maxillofac Surg.* 2016;74(9):63.
20. Damaskos S, Aartman IHA, Tsiklakis K, van der Stelt P, Berkhout WER. (2015). Association between extra- and intracranial calcifications of the internal carotid artery: a CBCT imaging study. *Dentomaxillofac Radiol.* 2015;44(5):20140432. doi:10.1259/dmfr.20140432.
21. Abdelkarim AZ, Lozanoff S, Abu El Sadat SM, Syed AZ. Osteoma cutis and tonsillolith: a cone beam computed tomography study. *Cureus.* 2018;10(7):e3003. doi:10.7759/cureus.3003.

**Elaine Cristina de Carvalho Beda Corrêa de Araújo
(Corresponding address)**

Av. Eng. Francisco José Longo, 777- Jd. São Dimas 12245-000
São José dos Campos/SP
E-mail: Elaine.araujo@unesp.br

Date submitted: 2019 Sep 12

Accept submission: 2019 Nov 26