



Atrophic jaw fracture and predictability in oral rehabilitation: case report

Fratura de mandíbula atrófica e previsibilidade na reabilitação oral: relato de caso

João Pedro Miola Siqueira de OLIVEIRA¹, Gilson Cristiano de OLIVEIRA¹, Paola CORSO¹, Rafaela SCARIOT¹, Davani Latarullo COSTA¹

1 - School of Health Science – Department of Dentistry – Positivo University – Curitiba – Parana – Brazil.

ABSTRACT

Introduction: The treatment of atrophic jaw fractures requires extensive knowledge by the maxillofacial surgeon. The correct diagnosis and planning optimize the possibility of oral rehabilitation towards many possible alternatives. The difficulty in repairing these fractures makes the treatment complex, in which normally invasive techniques are used. However; which give us satisfactory and predictable aesthetic-functional results. **Objective:** The objective of this work is to report an atrophic jaw fracture and posterior dental implants re-habilitation. **Case report:** A 53 years old female patient, victim of in face aggression referred to the emergency care. At the clinical examination, the patient had laceration in the upper lip region and the left side of the mandibular area, with bilateral mobility and paresis. In the oral examination, total lower and partial upper edentulism. After tomographic evaluation, a bilateral fracture of the mandibular body was confirmed, with significant bone fragments uneven. Surgery was performed with total transcervical access and use of reconstruction plate. After 90 days of follow-up, the oral rehabilitation with osseointegrated implants was performed. **Conclusion:** Complex atrophic mandible fractures in total edentulous patients can be treated with open reduction and stable fixation, allowing a faster return to normal function, improve of quality of life and assists in increasing safety for implant installation.

KEYWORDS

Edentulous jaw; Jaw fixation techniques; Dental implants.

RESUMO

Introdução: O tratamento de fraturas em mandíbula atrófica requer amplo conhecimento por parte da cirurgião bucomaxilofacial. O correto diagnóstico e planejamento otimizam a possibilidade de reabilitação, diante das muitas alternativas possíveis. A dificuldade em reparar essas fraturas torna o tratamento complexo, no qual normalmente técnicas invasivas são usadas. Entretanto, é possível alcançar resultados funcionais e estéticos satisfatórios e previsíveis. **Objetivo:** O objetivo de este trabalho é relatar uma fratura em mandíbula atrófica seguida de reabilitação com implantes dentários em região posterior. **Relato de caso:** Paciente do sexo feminino, 53 anos, vítima de agressão em face buscou o serviço de emergência. No exame clínico, observou-se laceração na região do lábio superior esquerdo com mobilidade bilateral e paralisia em região mandibular. No exame intra-oral, edentulismo total inferior e parcial superior. Após avaliação tomográfica, a fratura bilateral do corpo mandibular foi confirmada, com presença de significativos fragmentos ósseos. A cirurgia foi realizada com acesso transcervical total e uso de placa de reconstrução. Após 90 dias de acompanhamento foi iniciada a etapa de reabilitação oral com implantes osseointegrados. **Conclusão:** Fraturas atróficas complexas da mandíbula em pacientes desdentados totais podem ser tratados com redução e fixação estável, permitindo um rápido retorno da função, melhora da qualidade de vida, além de auxiliar no aumento da segurança no momento da instalação dos implantes.

PALAVRAS-CHAVE

Arcada edêntula; Técnicas de fixação da arcada osseodentária; Implantes dentários.

INTRODUCTION

Jaw fractures occur mainly in the region of the mandibular body and branch, in addition to the condylar area [1]. Mandibular atrophy caused by edentulism represents a greater risk of fractures in the mandibular bone due to a decrease of bone mass associated with lower resistance and resilience [2].

Early loss of dental elements, agenesis or previous surgeries due to tumor lesions are causes of bone resorption leading to mandibular atrophy [2]. Atrophic jaw fractures present a challenge for the surgeon because there is a need to promote osteosynthesis with reduction and bone immobilization in areas of small volume [2]. This type of fracture often occurs in elderly edentulous patients, in whom anatomical and physiological changes affect the prognosis negatively [2,3]. In last few years there has been a great evolution in the surgical approaches, in which we observe gradual substitutions of closed techniques by open techniques [3,4].

The jaw should be classified as atrophic when its height is equal or less than 20 mm. Among the atrophic mandibles are identified 3 different classes: Class I with height between 20 and 16 mm, Class II with 15 to 11 mm and Class III with height less than 10 mm [2]. Treatment methods available for this type of fracture include open reduction and rigid internal fixation using mini-plates and reconstruction plates applied with or without simultaneous bone grafting. However, the literature has shown better results when more aggressive approaches are chosen [5,6].

After the restoration of the mandibular fracture, the new challenge presents itself in the dental rehabilitation of the atrophic jaws; since most of these patients have a total lack of teeth. Rehabilitation with dental implants becomes a complex and limited procedure. Among the options most discussed in the literature, two treatment options can be highlighted: the short implants or conventional implants associated with the installation of a reconstruction plate for mandibular reinforcement [7,8].

The objective of this work is to present a case report of complex atrophic jaw fracture with total functional rehabilitation with dental implants.

CASE REPORT

A female patient, 53 years old, victim of aggression in the face, attended in the Emergency Room of Angelina Caron Hospital due to extensive laceration in the mental region and possible diagnosis of mandibular fracture.

In the clinical evaluation the patient presented laceration in the region of the upper lip and the left side of the chin area, with bilateral mandibular body mobility. In the oral examination, she presented lower total, partial upper edentulism and complaint of paresthesia in the anterior area of the mandible.

After a tomographic evaluation (Figure 1), the diagnosis of bilateral complex fracture of the mandibular body was confirmed, with significant irregularity of bone fragments and severe atrophy. Given this situation our treatment plan was to medicate the patient with analgesic and anti-inflammatory and waited a period of 07 days for improvement of the initial edema condition and printing the stereolithographic model for the surgical planning. The patient was clinically stable and was medicated by Dipyrone 01 g every 6 hours and Ceto-profen 100 mg every 12 hours by mouth. The patient was oriented to maintain liquid-pasty and cold food, rest and hygiene care, in addition to routine pre-operative laboratory tests and electrocardiogram. Thus, no need for immediate surgical intervention once there was any exposed area.

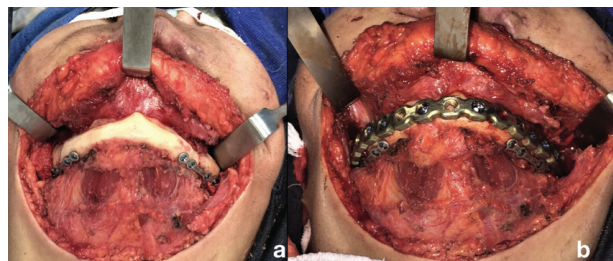

Figure 1- Coronal view (a) and three-dimensional reconstruction of preoperative computed tomography, evidencing mandibular fracture (b).

Surgical planning by printing the stereolithographic model of the mandible to optimize pre-molding of the reconstruction plate was performed. This work routine allows greater predictability in the positioning of the bone fragments in the transoperative and shorter surgical time, besides greater fidelity in the reestablishment of the mandibular contour and good postoperative recovery (Figure 2).

The access was the total transcervical, with subcutaneous tissue divulsion by planes, ligation of the arterial and facial vein and posterior access to the fracture (Figure 3). The repositioning of the fractured fragments were simplified with the installation of 02 plates of 2.0 mm system (Tóride®, Campinas, SP, Brazil) (Figure 6). After resting the functional contour of the mandibular arch, the stabilization of the preformed 2.4 mm (Tóride-Campinas, SP, Brazil) reconstruction plate was performed (Figure 4). There was no need of maxillo-mandibular fixation due to upper and lower total partial edentulism.

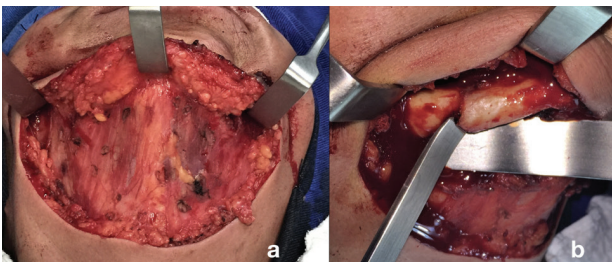


Figure 2 - Biomodel for pre-bending the rebuilding plate in a frontal view.

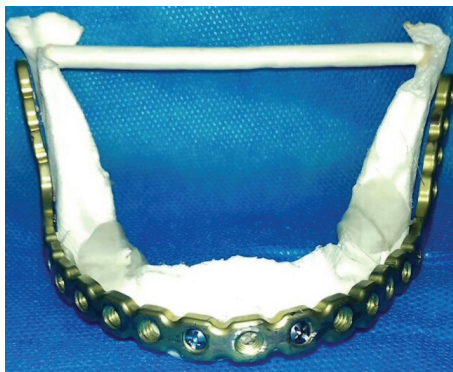

Figure 3 - Trans-operative with extra-buccal access for exposure of the surgical site (a) and repositioning of the bone fragments (b).

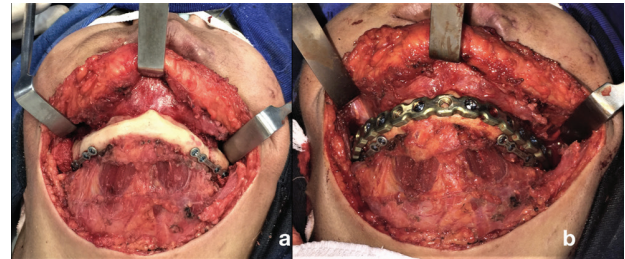


Figure 4 - Trans-operative with fixation of the base of the mandible (a) and adaptation of the reconstruction plate (b).

Three links of the reconstruction plate were maintained without screws of fixation aiming the posterior installation of the dental implants. It is worth remembering that the surgical reduction in this case obeyed the anatomical criteria for restoration of the facial contour and the mandibular anatomy.

After complete fixation of the reconstruction plate, hemostasis was verified, sutured by planes with polyglactin 910 (VICRYL®, Ethicon, Sao Paulo, SP, Brazil) and nylon 3-0 and 5.0 (Nylon®, Ethicon, Sao Paulo, SP, Brazil).

The patient remained hospitalized to maintain hydration, pain and inflammatory process control for 48 hours. During this period the patient received Cefazo-line 1 g every 8 hours associated with dipirona 01 g every 6 hours, Cetoprofen 100 mg diluted in saline 0.9% every 12 hours and ranitidine 150 mg once a day intravenously. Computed Tomography Scan and postoperative radiographs were performed after 12 hours of the procedure. The images evaluation was possible to evidence the correct replacement of the fractured bone fragments, mandibular condyles within the joint cavity and resumption of the mandibular contour. (Figure 5). The patient was discharged under bland diet and cold therapy instructions, and the same pre-operative medication protocol analgesia and anti-inflammatory associated with antibiotic, being Amoxicilina 875 mg every 12 hours for 10 days.

Postoperative 7 days of the procedure with surgical wound still in healing process, moderate limitation of buccal opening, no pain, compatible edema and paresthesia.

After 90 days of surgical, planning for functional rehabilitation surgery was performed with 04 morse taper implants (Neodent®, Curitiba, PR, Brazil) in the anterior area of the mandible. It is important to emphasize that the installation of implants sought to respect the space already prepared in the act of mandibular osteosynthesis (Figures 6 and 7).

The inferior prosthesis over the osseointegrated implants was installed after 90 days to the implant surgery, and her upper partial removal denture was adapted (Figure 8). The total time to rehabilitation after mandibular fracture surgery was 06 months.

Currently the patient presents a follow-up of 18 months with stable occlusion, satisfactory mouth opening, facial symmetry and no aesthetic-functional complaints (Figure 9). Post treatment paresthesia showed improve-ment after vitamin B complex medication, however, the patient was orientated that this would be a sequel due to the degree of the trauma and has no complaints in relation to this.

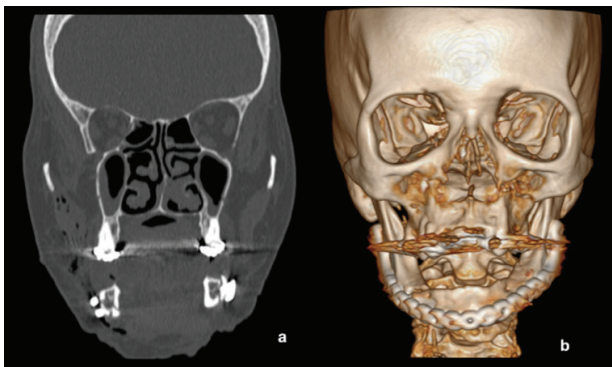


Figure 5 - Coronal view (a) and three-dimensional reconstruction of postoperative computed tomography (b).

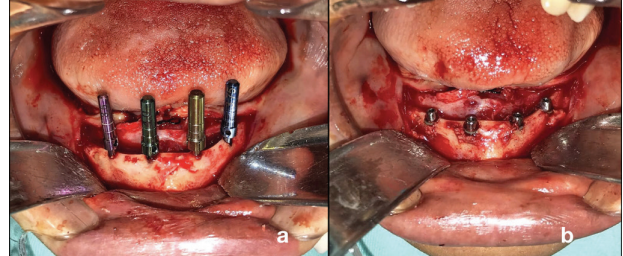


Figure 6 - Surgical stage for oral rehabilitation with 5 implants inferior, showing correct three-dimensional positioning (a) and installation (b) of the implants.

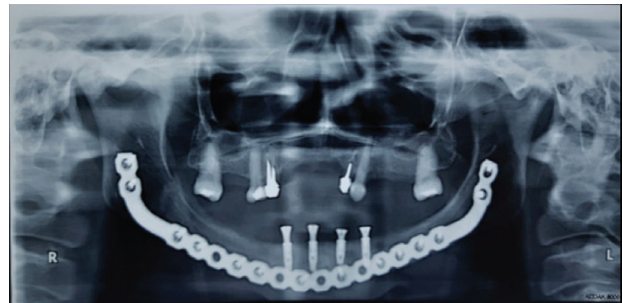


Figure 7 - Panoramic radiography of the immediate postoperative period after implant installation.

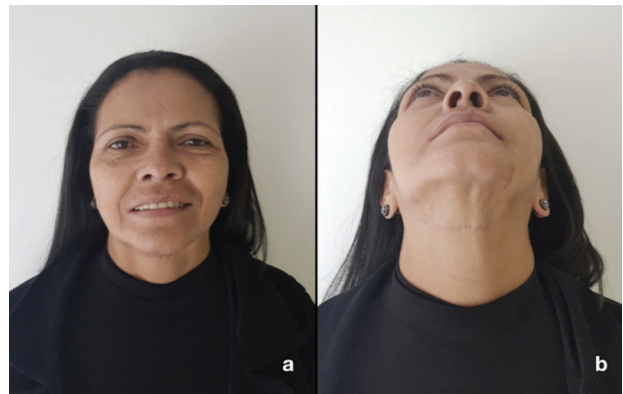

Figure 8 - Inferior prosthesis over the osseointegrated implants (a) and satisfactory opening mouth after 90 days of follow-up (b).

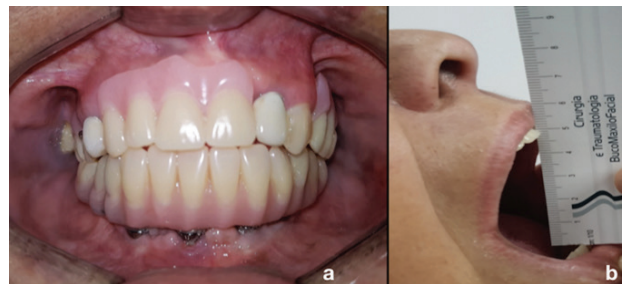


Figure 9 - Eighteen months of follow-up, showing a satisfactory facial contour in a frontal (a) and inferior-superior (b) view.

DISCUSSION

Maxillofacial fractures occur in a considerable number of patients who experience trauma to the face region. Despite being one of the largest and most robust bone tissues, the mandible presents a tendency to fractures due to its positioning, projection and mobility. As the atrophic mandible, weakening of the bone structure and decreased vascularization represent additional challenge in relation to the success of the treatment [6,9].

Clinical and imaging evaluation of the patient during initial care is indispensable. Imaging is fundamental for the correct diagnosis and evaluation of mandibular fractures in at least two planes. However, images in two dimensions can lead to errors of diagnosis and consequently errors in the surgical planning. Thus, computed tomography is the best option to assist the diagnosis of mandibular fractures [5]. In this way, besides being the examination of choice for the evaluation of patients with facial trauma in our service, this exam also allows the planning and printing of sterolithographic models.

In this described procedure the choice of the sterolithographic model decreased the time of the surgical procedure by optimizing the conformation of the reconstruction plate and allowing us to predict aesthetic-functional out-comes, besides facilitating the interaction between professional patient as demonstrated in the literature [10,11].

Regarding the choice of extra-oral access, in edentulous patients with bone atrophy, the process of physiological resorption of the alveolar bone and the use of muco-supported prostheses may lead to an intrabuccal exposure of the fixation material [12]. The extra-oral approach considerably reduces this possible postoperative complication [6].

As a treatment of complex fractures in atrophic mandibles, the conservative approach

with intermaxillary fixation is not usually the best option when associated with edentulism because it presents a small area of bone contact. In this way, open reduction and stable internal fixation is presented as the treatment of choice whenever the clinical condition of the patient allows the surgical approach [6,13,14].

Also, in fractures of the atrophic jaw it is possible to use or not graft in the lines of fracture [6]. However, when using the 2.4 mm system reconstruction plates, the graft becomes an option, not being extremely necessary [7,8]. In this case, the good stability and the good surface bone contact obtained in the fractured with the reconstruction plate, allows to don't use the bone grafts.

Increased bone stress is considered a problematic issue in atrophic jaws. Locking plates reduce this effect because they are able to absorb load and provide stability to the patient who will undergo mandibular rehabilitation after fracture [6]. Therefore, reconstruction plates are usually not removed in the atrophic jaw, as they provide stability and reduce the possibility of a new fracture [15].

The functional oral rehabilitation of patients with atrophic jaw is one of the greatest difficulties in dentistry, since the low bone quality and volume limitation observed are obstacles to the retention of conventional prostheses and also to the use of osseointegrated implants [16]. The reconstruction of atrophic jaws with plates of the 2.4 mm system allows the restoration of immediate function, besides optimizing the installation of implants with greater safety, independent of the risk of associated bone fracture.

CONCLUSION

Complex atrophic mandible fractures in total edentulous patients can be treated with open reduction and rigid fixation, allowing a faster return to normal function, improve of quality of life and assists in increasing safety for implant installation.

REFERENCES

1. Van den Bergh B, van Es C, Forouzanfar T. Analysis of Mandibular Fractures. *J Craniofac Surg* 2011; 22(5):1631-4. doi: 10.1097/SCS.0b013e31822e5f20.
2. Luhr HG, Reidick T, Merten HA. Results of treatment of fractures of the atrophic edentulous mandible by compression plating: A retrospective evaluation of 84 consecutive cases. *J Oral Maxillofac Surg* 1996; 54(3):250-4.
3. Brucoli M, Boffano P, Romeo I, Corio C, Benech A, Ruslin M et al. The epidemiology of edentulous atrophic mandibular fractures in Europe. *J Cranio-maxillofac Surg* 2019 Dec;47(12):1929-1934. doi: 10.1016/j.jcms.2019.11.021.
4. Castro-Núñez J, Cunningham LL, Van Sickels JE. Atrophic Mandible Fractures: Are Bone Grafts Necessary? An Update. *J Oral Maxillofac Surg* 2017 Nov;75(11):2391-2398. doi: 10.1016/j.joms.2017.06.023.
5. Castro-Núñez J, Shelton JM, Snyder S, Van Sickels J. Virtual Surgical Planning for the Management of Severe Atrophic Mandible Fractures. *Cranio-maxillofac Trauma Reconstr* 2018 Jun;11(2):150-156. doi: 10.1055/s-0037-1601865.
6. Ellis E 3rd, Price C. Treatment Protocol for Fractures of the Atrophic Mandible. *J Oral Maxillofac Surg* 2008; 66:421-435. doi: 10.1016/j.joms.2007.08.042.
7. Romeo E, Ghisolfi M, Rozza R, Chiapasco M, Lops D. Short(8-mm) dental implants in the rehabilitation of partial and complete edentulism: A 3- to 14-year longitudinal study. *Int J Prosthodont* 2006; 9:586-92.
8. Ayali A, Bilginaylar K. Evaluating the biomechanical effects of implant diameter in case of facial trauma to an edentulous atrophic mandible: a 3D finite element analysis. *Head Face Med*. 2017 May 2;13(1):5. doi: 10.1186/s13005-017-0139-z.
9. Novelli G, Sconza C, Ardito E, Bozzetti A. Surgical Treatment of the Atrophic Mandibular Fractures by Locked Plates Systems: Our Experience and a Literature Review. *Cranio-maxillofac Trauma Reconstr* 2012; 5(2):65-74. doi: 10.1055/s-0031-1300961.
10. Jardini A, Maciel R, Scarparo M, Andrade S, Moura L. Improvement of the spatial resolution of prototypes using infrared laser stereolithography on thermosensitive resins. *J Mater Process Technol* 2006; 172(1):104-9.
11. Winder J, Bibb R. Medical Rapid Prototyping Technologies: State of the Art and Current Limitations for Application in Oral and Maxillofacial Surgery. *J Oral Maxillofac Surg* 2005; 63(7):1006-15.
12. Pereira A, Gondim D, Júnior E, Filho F. Remoção de miniplacas e parafusos na região bucomaxilo-facial: revisão de literatura. *Rev Cir Traumatol Buco-Maxilo-Fac* 2005; 5(3):17-26.
13. Castro-Núñez J, Cunningham L, Van Sickels J. A historical perspective with current opinion on the management of atrophic mandibular fractures. *Oral Surg Oral Med Oral Pathol Oral Radiol* 2017; 124(6):276-82. doi: 10.1016/j.oooo.2017.09.007.
14. Kunz C, Hammer B, Prein J. Frakturen des zahnlosen atrophischen Unterkiefers. *Mund Kiefer GesichtsChir* 2001; 5(4):227-32. <https://doi.org/10.1007/s100060100304>.
15. Franciosi E, Mazzaro E, Larranaga J, Rios A, Picco P, Figari M. Treatment of edentulous mandibular fractures with rigid internal fixation: case series and literature review. *Cranio-maxillofac Trauma Reconstr* 2014; 7(1):35-42. doi: 10.1055/s-0033-1364195.
16. Nakai H, Niimi A, Ueda M. Osseous proliferation of the mandible after placement of endosseous implants. *Int J Oral Maxillofac Implants* 2000; 15(3):419-24.

Paola Corso
(Corresponding address)

Positivo University
Professor Pedro Viriato Parigot de Souza Street, 5300
ZIPCODE 81280-330
E-mail: paolafcorso@gmail.com

Date submitted: 2019 Oct 23

Accept submission: 2020 Apr 16