



Clinical assessment of two inlay-retained bridge designs in missing posterior teeth cases: a Randomized Clinical Trial

Avaliação clínica de dois modelos de ponte fixa inlay (forma de caixa proximal e em forma de inlay) em casos de dentes posteriores ausentes. (Ensaio clínico randomizado)

Gomaa A. SOLIMAN¹, Omaima S. MAHALLAWI¹, Iman S. HAMDY¹

1 - Cairo University, Faculty of Dentistry. Cairo, Egypt.

ABSTRACT

Objective: This study aimed to evaluate the clinical performance of two inlay-retained bridge designs (proximal shaped and inlay shaped) in single missing posterior teeth cases. **Material and Methods:** A total of 70 cases with missing single posterior teeth were included in this study and divided into two groups with a 1:1 allocation ratio (n = 35 for each group). Group 1 (the control group): this group received an inlay retained bridge with inlay design on both abutments. Group 2 (the intervention group): this group received an inlay retained bridge with a proximal box on both abutments. PMMA resin (YAMAHACHI PMMA) was used for the try-in stage and monolithic zirconia (Katana, Kuraray) was used for the final restorations. The restoration surfaces were treated using sandblasting and Z-prime S (Bisco) and the cementation was done by using self-adhesive resin cement (Bisco). Fracture, marginal adaptation, postoperative sensitivity, caries, and gingivitis were assessed using the modified United States Public Health Service for restoration clinical assessments (MUSPHS standards) over 12 months of follow-up. **Results:** The results show there was no significant difference between the two groups. Kaplan-Meier survival curve was constructed to calculate the mean survival estimates of the two groups and we found that the two groups were clinically successful during a one-year follow-up. **Conclusion:** Both designs of inlay retained fixed dental prostheses revealed successful clinical performance in terms of Fracture, marginal adaptation, postoperative sensitivity, caries, and gingivitis.

KEYWORDS

Fracture; Inlay-retained fixed dental prosthesis; PMMA; Resin cement; Zirconia.

RESUMO

Objetivo: O objetivo deste estudo foi avaliar o desempenho clínico de dois modelos de ponte fixa por inlay (formato proximal e formato inlay) em casos de dentes posteriores perdidos. **Material e Métodos:** Um total de 70 casos com perda de um único dente posterior foi incluído neste estudo e dividido em dois grupos com uma razão de alocação de 1: 1 (n = 35 para cada grupo). Grupo 1 (grupo controle): Este grupo recebeu uma ponte fixa por inlay com desecho de inlay em ambos os pilares. Grupo 2 (grupo intervenção): Este grupo recebeu uma ponte fixa inlay com uma caixa proximal em ambos os pilares. Resina de PMMA (YAMAHACHI PMMA) foi usada para a etapa de try-in e a zircônia monolítica (Katana, Kuraray) foi utilizada para as restaurações finais. As superfícies das restaurações foram jateadas com Z-prime S (Bisco) e a cimentação realizada com cimento resinoso autoadesivo (Bisco). Fratura, adaptação marginal, sensibilidade pós-operatória, cárie e gengivite foram avaliadas usando o Serviço de Saúde Pública dos Estados Unidos modificado para avaliações clínicas de restauração (padrões MUSPHS) ao longo de 12 meses de acompanhamento. **Resultados:** Os resultados mostraram que não houve diferença significativa entre os dois grupos. A curva de sobrevivência de Kaplan-Meier foi construída para calcular as estimativas de sobrevivência média dos dois grupos e foi concluído que os dois grupos foram clinicamente bem sucedidos durante um acompanhamento de um ano.

Conclusão: Ambos os modelos de próteses dentárias fixas de inlay revelaram desempenho clínico bem-sucedido em termos de fratura, adaptação marginal, sensibilidade pós-operatória, cárie e gengivite.

PALAVRAS-CHAVE

Fratura; Prótese fixa inlay; PMMA; Cimento resinoso; Zircônia.

INTRODUCTION

There are several treatment modalities in the posterior region of the mouth to restore a missing tooth. Inlay retained fixed dental prosthesis (IRFDP) is one of the minimally invasive procedures. Inlay-shaped design is the traditional bridge design of defined dimensions [1]. During the preparation of full coverage restorations, with accompanying problems such as pain and postoperative sensitivity, there is more tooth loss reach to the two-third compared to that with the inlay retained bridge tooth reduction [2].

One of the tooth-colored restorative materials, monolithic zirconia, has become an important part of modern dentistry with high esthetics, wear resistance, precise contacts, contour, and biocompatibility to surrounding soft and hard tissues. With developing a computer-aided design and Computer-aided manufacturing (CAD/CAM) technology and zirconia materials, monolithic zirconia restoration has become popular [3]. The in vitro investigations have shown that monolithic zirconia single crowns can withstand fracture loads higher than those of layered zirconia restorations. As a result of their fracture resistance, monolithic zirconia crowns are resistant to the forces of mastication in the molar region. These high-strength materials require less tooth reduction, leading to less risk of pulpal damage, and are suitable for an inlay-retained fixed dental prosthesis [4].

The innovations in restorative materials and construction techniques which aim to enhance the clinical success keep going and this clinical study would provide benefits for practitioners and clinicians by guiding them to choose a more conservative treatment plan with a better marginal fit, clinical performance, and satisfaction for the patients in the long term rather than other benefits like less chair time, less risk for pulp injury, less time, and cost.

The null hypothesis of this research would be no difference in the clinical performance regarding fracture, marginal adaptation, postoperative

sensitivity, caries, and gingivitis of proximal box design compared to inlay shaped design of monolithic Zirconia inlay-retained bridge.

MATERIALS AND METHODS

Study design

This study was a double-blind randomized controlled clinical trial with a 1:1 allocation ratio.

Independent researchers made a random allocation for the patients in this clinical trial by using computer-generated random numbers. Type of randomization was simple by using (random.org) as my colleague entered the 70 cases and divided them into two groups according to intervention or control (for example, 2 columns each one contain 35 as one column for intervention and the other for the control). this number arranged randomly from 1 to 70 and this randomization was not be known for the main researcher and the patients. Participants were allocated in two different groups with a 1:1 allocation ratio by using computerized sequence generation (www.randomizer.org).

Sample size estimation

Based on previous papers by Harder et al. [5] indicate that the fracture rate among controls is 45%. If the true fracture rate for experimental subjects is 15%, we will need to study 35 in each group to be able to reject the null hypothesis that the failure rates for experimental and control subjects are equal with probability (power) 0.8. The Type I error probability associated with this test of this null hypothesis is 0.05. The sample size was calculated by PS: Power and Sample Size Calculation software Version 3.1.2 (Vanderbilt University, Nashville, Tennessee, USA).

Participant's selection

A total of 70 inlay retained restorations were placed in patients who fulfilled the following inclusion criteria, the patients in this study

would be in the range of 18-51 years, absence of periapical or periodontal diseases, absence of parafunctional habits, sufficient occlusal-gingival tooth height (not less than 5mm), mesiodistal edentulous space preferred not to exceed 12mm and good alignment of abutment teeth. Each participant received inlay retained restoration for replacement of a single missing posterior tooth. Their chief complaint was to enhance chewing efficiency and esthetics. Information was given to each patient regarding the alternative treatment options. The treatment plan was explained for each patient. Then, they agreed to sign the informed consent before proceeding to clinical work. They were able and willing to maintain good oral hygiene measures. They were recruited during the time from November 2018 till June 2019 from the outpatient clinic of Fixed Prosthodontics Department, Faculty of Dentistry, Cairo University, Cairo, Egypt. Screenings of patients were carried out until the target number was reached. This study was completed by July 2020.

The clinical study

It started with an extraoral, intraoral examination, and radiographic examination pre-operative photographs for each patient were taken using a Canon 650D DSLR camera (Nikon D7100 DSLR camera, Japan). Full mouth scaling, primary and shade selection were made before teeth preparation.

Teeth preparations phase

Group 1 (control group): inlay preparation (occlusion -proximal box) was with rounded internal line angles, smooth rounded edges, and rectangular floor with no bevels at the occlusal or gingival margin. The occlusal cavity preparation with 2 mm depth, isthmus width 1.5-2 mm for premolars and 2.5-3 mm for molars, 2 mm proximal box, 6° occlusal divergences of the axial walls. The occlusal preparation extended 4 or 6 mm mesiodistally for the premolar or molar, respectively. The preparations corresponded to a proximal connector area of at least 3 mm × 3 mm for molars and premolars [6-8].

Group 2 (intervention group): The proximal box design with 1.5-2 mm width for premolar, 2.5-3 mm for molars, has 6° divergences, and extends at least 2 mm apical to the isthmus floor [9].

The preparations were done using an inlay and crown preparation kit (Diatech, Switzerland)

by the same operator for both designs and were finished and smoothed so that no sharp angles were left (Figure 1).

After the preparation was finished, the final impression was made using a fast set addition silicone impression material (Express™ Impression Material, 3M ESPE, U.S.) and perforated stock tray (double mix one-step impression technique) [10]. Polyvinyl siloxane bite registration material (Occlufast. Zhermack, Italy) was used to obtain the interocclusal records from the patient. The final impressions were poured using type IV stone (Elite, Zhermack, Italy) according to the manufacturer's instructions with using vacuum mixing to avoid voids formation. the master cast was mounted on a simple hinge articulator with the aid of the interocclusal record.

Eugenol-free self-curing provisional filling material (Coltosol F, Coltene, Switzerland) was used to preserve the abutment cavities and protect the dental pulp from external detrimental effects during the laboratory procedures [10].

Bridge fabrication

For the scanning process, Activity 885 (Bochum, Germany) was used. Smart optics software has been used. Both the arches were scanned separately and in occlusion.

The Milling process for the try-in phase by using CAD/CAM PMMA discs

The selected PMMA resin disk of the required size was inserted into the Roland DWX-50 milling machine (Roland DGA Corporation, California) and the spindle was fastened with the set screw [11]. The resin restoration was checked

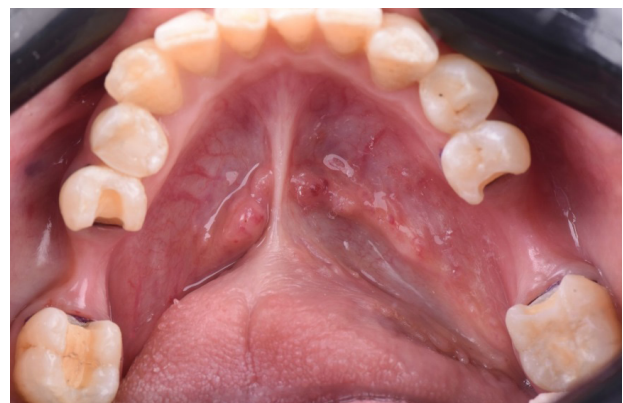

Figure 1 - Representative preparation photo of both groups, a proximal box design (left side) and inlay shaped design (right side).

first on the master cast for the seating, occlusion, and marginal fitting then the temporary filling was removed and the abutment teeth were cleaned with pumice paste. After completion of the try-in stage, the PMMA resin is used as provisional restoration.

The milling process for the final restoration

We used SumD3 software to start the milling procedure, after that the bridges were put in an ultrasonic cleaner with ethyl alcohol for 1 minute, then dried completely before sintering. Sintering was performed using a Mihm Vogt Tabeo sintering furnace (Panadent, Kent BR5 3AQ, UK) The Vita Akzent plus staining kit was used to stain all the bridges. This was done using the ceramic furnace Programat CS3 (Ivoclar Vivadent) at 850 °C firing Cycling. The final restoration was checked for seating, stability, marginal adaptation, retention, occlusion, and connectors.

Monolithic zirconia surface treatment

1-Cleaning the zirconia surface from saliva remnants with ZirClean

Once the restorations have been checked, they have been completely rinsed with water, and have been dried out with air, then all bonded areas of the restoration have been covered by a layer of ZirClean (Bisco, Schaumburg, USA) and left for 20 seconds for the cleaning measures to be carried out. then the restorations were rinsed thoroughly with water spray and dried with air [12].

2-Micromechanical surface treatment for monolithic zirconia

The inner side of the IRFDP was sandblasted with Al₂O₃ particles (50µm, 2.8 bar, 1 cm), washed with 60s water spray, and ultrasonically cleaned with 95% ethyl alcohol for 10 minutes [1]. To ensure a 1cm distance between the inner surface and the nozzle of sandblasting machine (Basic co, Renfert, Germany) a specially designed 3D printed template was constructed (Figure 2). The bridges were fitted in place, with the fitting surface faced towards the nozzle opening. using unset putty impression material and the fitting surface of the pontic was protected with cellophane paper. The assembly was inserted into the sandblasting machine and the sandblasting procedure was commenced.




Figure 2 - 3D template and sandblasting nozzle.

3-Chemical surface treatment for monolithic zirconia

An MDP containing primer (Z prime plus, Bisco) was applied to the monolithic zirconia surface as recommended by the manufacturer for 1 minute then rinsing and dryness.

Final cementation of the restoration

A rubber dam was placed, isolating the preparations from the oral cavity. Abutments were cleaned using a pumice paste over a rotating brush. The selective etching was used as 37% phosphoric acid gel (Fine etch, Spident) was applied to the cavity margins of the exposed enamel and left in place for 20 s, the dentin was etched for 10 s, followed by water spray cleaning for 20 s and gentle air drying [10]. Enamel and dentin were treated with an adhesive bonding agent (All bond universal, Bisco), and light-curing was done for at least 10 seconds in compliance with the manufacturer's instructions. A self-adhesive resin cement (Theracem, Bisco) was dispensed on the fitting surfaces of the monolithic zirconia and within the preparation cavities. Glycerine gel was applied at the margins to prevent an oxygen inhibition layer at the interface; subsequently, a prolonged light-curing was performed for 20 seconds for each surface (Elipar deep cure S, 3M). Margins were finished and polished with diamond burs, rubber points, and diamond polishing paste (Intensive SA, Montagnola, Switzerland) (Figure 3).

Follow up procedure

Evaluation of the restoration fracture, marginal adaptation, sensitivity, recurrent

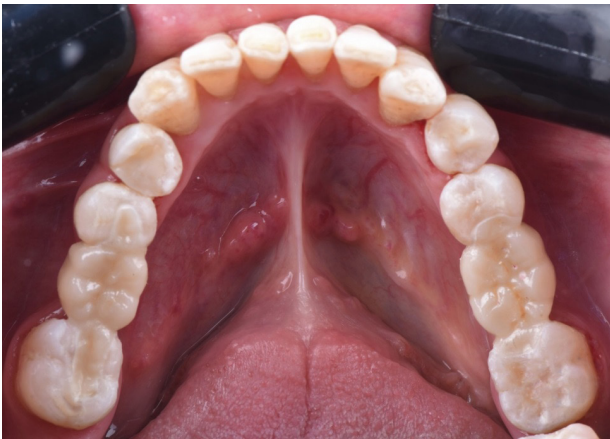

Figure 3 - Inlay retained bridges after the final cementation.

caries, and gingivitis was done immediately after cementation, one month, three months, six months, nine months, and twelve months. This was done by using the MUSPHS criteria [13].

Fracture: evaluation of fracture determined if the restoration was intact or not

Marginal adaptation: evaluation was done by sharp explorer

caries: evaluation of recurrent caries was done visually

Postoperative sensitivity: by evaluating patient symptoms and bypassing air spray on the margins.

Gingivitis: by evaluating the gingival condition at four sites (mesial, distal, buccal, and lingual)

Statistical analysis

Chi-square test and Fisher's Exact test were used to compare between the two groups. Friedman's test was used to study the changes by time within each group. Kaplan-Meier survival curve was constructed to calculate the mean survival estimates of the two groups. The significance level was set at $P \leq 0.05$. Statistical analysis was performed with IBM SPSS Statistics for Windows, Version 23.0. Armonk, NY: IBM Corp.).

RESULTS

Regarding fracture

All restorations in the two groups showed no fractures through all follow-up periods; so no statistical comparison was performed

Regarding marginal adaptation

After 12 months; 97.1% of restorations in the Inlay-shaped group showed (Alpha) score and 2.9% showed (Bravo) score. In the Proximal box group; 94.3% of restorations showed (Alpha) score and 5.7% showed (Charlie) score. There was no statistically significant difference between the two groups (P -value = 0.493, Effect size = 0.208).

Regarding postoperative sensitivity

After 12 months; all restorations in the Inlay-shaped group showed (Alpha) score. In the Proximal box group; 94.3% of restorations showed (Alpha) score, 2.9% showed (Bravo) score and 2.9% showed (Charlie) score. There was no statistically significant difference between the two groups (P -value = 0.493, Effect size = 0.171).

Regarding caries

All restorations in the two groups showed no caries through all follow-up periods; so no statistical comparison was performed.

Regarding gingivitis

After 12 months; 91.4% of restorations in the Inlay-shaped group showed (Alpha) score and 8.6% showed (Bravo) score. In the Proximal box group; 91.4% of restorations showed (Alpha) score, 2.9% showed (Bravo) score and 5.7% showed (Charlie) score. There was no statistically significant difference between the two groups (P -value = 0.360, Effect size = 0.207).

Regarding survival analysis

Survival analysis was performed considering (Charlie) score as a failure. Mean survival times could not be computed because all cases in the Inlay-shaped group were successful. However; there was no statistically significant difference between the survival of the two groups (P -value = 0.154) (Figure 4).

DISCUSSION

Today, the need for the inlay retained bridges to preserve the tooth structure and to minimize abutment teeth preparation has increased. Pulpitis and long-term pulpal reactions seem to be considerable risks of crown preparations. In a recent trial, irreversible Pulpitis and pulpal

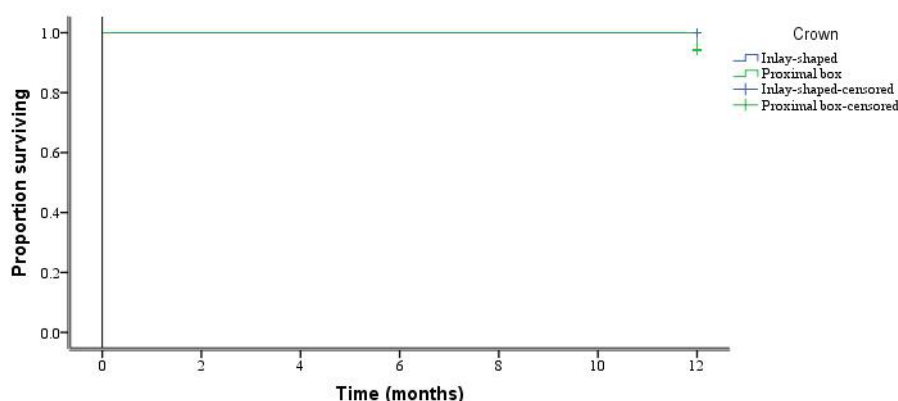


Figure 4 - Kaplan-Meier survival curve for the success of the two groups.

necrosis had occurred after 10 years in 15.6% of the teeth restored with single crowns and in 32.5% of teeth restored with bridge restorations respectively. Approximately 63-73% of coronal tooth structure was needed to be removed when teeth are prepared for all-ceramic restorations [2].

Following a general trend towards better esthetic restorations and increased biocompatibility, metal-free (fiber-reinforced composite resin or ceramic) resin-bonded fixed dental prosthesis have been developed [14].

Although initially successful, the low (73% to 78%) 5-year survival of posterior fiber-reinforced composite resin-bonded fixed dental prostheses gave rise to doubts regarding the long-term success of the treatment [15].

For inlay retained restorations fabricated from heat-pressed lithium disilicate glass-ceramic, a survival rate of 38% after 8 years contraindicated their use [5].

Recently, new materials and techniques have been introduced to create all-ceramic fixed partial dentures that are esthetically suitable for the rehabilitation of many cases with a wide range of indications, especially all zirconia-based ceramic materials that show significant improvements in esthetic parameters, biological compatibility, and superior mechanical characteristics [16].

In a study by Chaar and Kern [17], encouraging a cumulative 5-year survival rate of 94.5% was observed for zirconia-based inlay retained restorations with a modified, more retentive framework design with additional lingual and buccal retainer wings.

To overcome the problems of veneering zirconia, full-contoured, monolithic zirconia

restorations without veneering porcelain have become increasingly popular. Translucent monolithic cubic zirconia, due to its increased translucency, provides a new restorative option that combines strength with enhanced esthetics [18].

Monolithic zirconia became popular due to its high flexural strength; less wear on the antagonists and need minimal preparation of the tooth. Monolithic zirconia crowns can be manufactured for patients with compromised occlusion or parafunction with an occlusal reduction of as little as 0.5 mm. The material can also be shaped and polished easily with a special polishing kit [19].

There are different inlay designs, such as grooves, tub, proximal box-shaped preparations, and occlusal-proximal preparations. The size of these preparation features would depend on the tooth size. the most common designs for inlay retained restorations are (inlay-shaped, tub-shaped, and proximal box-formed [20].

Air abrasion with 50 μm Al_2O_3 for 15 seconds at 2.5 bars and 1 cm with custom made 3D printed template was used and it was found that air abrasion able to create irregularities on the surface of zirconia, in combination with phosphate ester monomer (MDP) containing primer (Z prime plus) and luting agents results in high, durable bond strengths because the phosphate ester group chemically bonds to metal oxides such as zirconium dioxide [21].

Theracem™, a self-adhesive dual-cure resin cement, was used for the final cementation of the inlay retained restoration. In a study by Mahrous et al. [22], they reveal that Using

MDP-containing calcium-fluoride-releasing self-adhesive resin cement (TheraCem) improves bond strength to all tested substrates (enamel, dentin, and zirconia) and can be considered a promising cement for many clinicians.

The MUSPHS criteria have provided a practical and logical approach to the assessment of the clinical performance of the restorations, are also widely used for the long-term assessment of the restorations and are considered to be valid for comparison purposes at different observation periods and provide a systematic approach that is now known to be universally accepted [23,24].

Fracture

Many factors control the fracture resistance of ceramic materials such as the composition, microstructure, fabrication technique, and surface finish [25].

New high strength Monolithic zirconia, with their stiffness and high mechanical properties (i.e: resistance to fracture and/or fatigue), could be considered the right choice in an IRFDP [26]. In our study, it was shown that there was no difference in the occurrence of fracture of the inlay retained bridge with inlay shaped design and the proximal box-shaped design and was statistically insignificant immediately, after 1 month, after 3 months, after 6 months, after 9 months and after 12 months of cementation. This may be related to the better strength of the translucent monolithic zirconia (Katana) which is less than the opaque zirconia but still above the biting force and the use of a total-etch technique with self-adhesive resin cement for bonding of zirconia [27].

The results of this study were in agreement with Abou Tara et al. [28] who conducted a study to evaluate the clinical outcome of inlay-retained fixed dental prostheses (IRFDPs) made from a zirconia ceramic and found that there was no framework fracture during the observation period of 20 months. They conducted that the CAD/CAM-manufactured zirconia ceramic framework was used because of the significantly higher static and fatigue fracture strength as compared to other ceramic materials.

The results of this study were not in agreement with Ohlmann et al. [20] who conducted a study to evaluate the clinical performance of zirconia-based all-ceramic fixed partial dentures anchored

by inlays and found high clinical failure with framework fracture after an observation period of 12 months. The framework fractures which occurred in their study were observed after premature loss of retention of one inlay retainer. This loss of retention would result in the mobility of the retainer followed by unfavorable stresses and strains, and thus framework fracture.

Marginal adaptation

It is shown that after one year, the inlay shaped design showed the best marginal adaptation and the proximal box showed clinically accepted results except for two cases which showed during the examination by explorer negative step, that would be repaired by composite filling but the restorations were not mobile and in function. These clinical accepted results may be related to an accurate impression using the addition silicon, scanning the master cast rather than the impression, utilizing a scanner with blue light technology, milling the zirconia at its pre-sintered stage, the absence of any veneering materials, and the short length of the span [29,30].

In a study by Wolfart et al. [31], they found that inlay-retained fixed partial dentures (IRFPDs) were made from a new lithium-disilicate glass-ceramic (IPS e.max Press, Ivoclar Vivadent) showed good marginal adaptation.

On the other hand, Rathmann et al. [32] conflicting with our findings and stated that poor marginal adaptation during the observation period. This contradiction may be related to the difference in the observation period, bonding protocol, and material difference which may lead to micromovement of the restoration with loss of marginal fit.

Postoperative sensitivity

All abutments were initially diagnosed as vital and remained vital after 1 year. At the baseline examination, three cases reported postoperative increased sensitivity in the inlay shaped designs which vanished within few days which explained by using the total-etch technique and polishing of the margins while in proximal box sensitivity increased in 2 cases after 12 months with improper marginal adaptation but after a repair, this sensitivity diminished and, there was no significant difference between the two designs regarding postoperative sensitivity.

Al-Moaleem [33] found similar results with post-operative sensitivity reported only during the third-month evaluation of IRFPDs and mentioned this could be explained by the use of glycerin gel which inhibits the oxidation of cement, the polishing of the margins, and the following of the instructions that recommended by the manufacture during and after the final cementation of IFPDs.

Caries

In our study, there was no difference in the results of secondary caries in the two designs and all restorations in the two groups showed no caries through all follow-up periods; immediately, after 1 month, 3 months, 6 months, 9 months, and 12 months of cementation so no statistical comparison was performed. This may be related to the better marginal fit of the inlay bridges, fluoride, and calcium release from Theracem resin cement [22].

Izgi et al. [10] conducted a study to evaluate the outcomes of cast-metal slot-retained resin-bonded fixed dental prostheses and found no incidence of secondary caries during the follow-up of 7.5 years. Jevremović et al. [34] found similar results.

Gingivitis

The dental prosthesis can increase the risk of gingival inflammation due to direct mechanical tissue injury (during abutment preparation, impression taking) and/or through plaque attachment (poor hygiene) and preventing the prosthesis in the oral cavity from self-cleaning possibilities [35]. It is shown that the overall gingival inflammation during the one-year evaluation period was 17.2% for inlay design and 14.3% for proximal box design with no significant difference and the signs mainly were mild inflammation related to improper tooth brushing with plaque accumulation. Rathmann et al. [32] found 3.3% of cases showed severe chronic periodontitis with zirconia IRFPDs.

Survival analysis

It was shown in our study the inlay-shaped design was with the best survival results and the proximal box showed favorable results with no statistically significant difference between the survival of the two groups.

In a systematic review by Chen et al. [36] they estimated that the 5- and 8-year survival rates of zirconia IRFPDs were 92.6% and 87.9% respectively[while Harder et al. [5] found that the 3- and 5-year survival rates of zirconia IRFPDs were 57% and 38% respectively.

Finally, the null hypothesis was accepted as the two groups showed successful clinical results regarding fracture resistance, marginal adaptation, postoperative sensitivity, caries, and gingivitis with no significant difference during the follow-up period.

Limitation of the study

Furthermore, studies with a longer follow-up period are required to evaluate the clinical performance of IRFDP with monolithic zirconia and compared it with other materials.

CONCLUSION

Within limitations of this study, the following conclusion could be drawn as follows: Up to one year clinical observation period, inlay retained fixed dental prostheses made from monolithic zirconia with two designs (inlay shaped and proximal box-shaped) revealed successful clinical performance in terms of fracture, marginal adaptation, postoperative sensitivity, caries, and gingival inflammation.

Clinical recommendation

Whenever the clinical situation permits, the conservative design of inlay retained fixed dental prostheses with proximal box design is recommended.

Ethical considerations and approval

This randomized clinical trial was conducted in the Department of Fixed Prosthodontics in the Faculty of Dentistry, Cairo University. The ethical approval for the study was obtained from the Ethics Committee of Scientific Research - Faculty of Dentistry – Cairo University (approval no: 179020). Participation in the study was voluntary and informed consent was obtained from all of them before starting the treatment regarding treatment sequence, publishing of their images, and results.

Consent for publication

I declare that the article is original and has not been published in any other journal.

Acknowledgments

I am grateful to *Professor Omaina Salah El Dein El Mahallawi* and *Professor Iman Salah El Dein Hamdy* for their continuous support.

Author Contributions

GAS: main researcher, responsible for collecting patients, making clinical work, and writing.

OSM: main supervisor, supported the clinical work of our trial and gave the final acceptance in sharing with the EBD committee.

ISH: co-supervisor, supported the clinical work of our trial and gave the final acceptance in sharing with the EBD committee.

Conflict of Interest

The authors have no proprietary, financial, or other personal interest of any nature or kind in any product, service, and/or company that is presented in this article.

Funding

This study was self-funded.

Regulatory Statement

This study was conducted in accordance with all the provisions of the local human subject's oversight committee guidelines and policies of: the Ethics Committee of Scientific Research - Faculty of Dentistry – Cairo University. The approval code for this study is: 179020.

REFERENCES

- Augusti D, Augusti G, Borgonovo A, Amato M, Re D. Inlay-retained fixed dental prosthesis: a clinical option using monolithic zirconia. *Case Rep Dent.* 2014;2014:629786. <http://dx.doi.org/10.1155/2014/629786>. PMID:24963420.
- Castillo-Oyagüe R, Sancho-Esper R, Lynch CD, Suárez-García MJ. All-ceramic inlay-retained fixed dental prostheses for replacing posterior missing teeth: a systematic review. *J Prosthodont Res.* 2018;62(1):10-23. <http://dx.doi.org/10.1016/j.jpor.2017.06.007>. PMID:28735678.
- Nistor L, Grădinaru M, Rică R, Mărășescu P, Stan M, Manolea H, et al. Zirconia use in dentistry - manufacturing and properties. *Curr Health Sci J.* 2019;45(1):28-35. <http://dx.doi.org/10.12865/CHSJ.45.01.03>. PMID:31297259.
- Kontonasaki E, Giasimakopoulos P, Rigos AE. Strength and aging resistance of monolithic zirconia: an update to current knowledge. *Jpn Dent Sci Rev.* 2020;56(1):1-23. <http://dx.doi.org/10.1016/j.jdsr.2019.09.002>. PMID:31768195.
- Harder S, Wolfart S, Eschbach S, Kern M. Eight-year outcome of posterior inlay-retained all-ceramic fixed dental prostheses. *J Dent.* 2010;38(11):875-81. <http://dx.doi.org/10.1016/j.jdent.2010.07.012>. PMID:20691750.
- Edelhoff D, Spiekermann H, Yildirim M. Metal-free inlay-retained fixed partial dentures. *Quintessence Int.* 2001;32(4):269-81. PMID:12066646.
- Mohsen CA. Fracture resistance of three ceramic inlay-retained fixed partial denture designs: an in vitro comparative study. *J Prosthodont.* 2010;19(7):531-5. <http://dx.doi.org/10.1111/j.1532-849X.2010.00621.x>. PMID:20561160.
- Song HY, Yi YJ, Cho LR, Park DY. Effects of two preparation designs and pontic distance on bending and fracture strength of fiber-reinforced composite inlay fixed partial dentures. *J Prosthet Dent.* 2003;90(4):347-53. [http://dx.doi.org/10.1016/S0022-3913\(03\)00434-7](http://dx.doi.org/10.1016/S0022-3913(03)00434-7). PMID:14564289.
- El Halawani M, Aboushady YS, Kader SM, Solimei L, Morfi B, Benedicenti S. Marginal penetration in zirconia inlay-retained fixed partial dentures: an in-vitro study. *Alexandria Dent J.* 2020;45(3):7-11. <http://dx.doi.org/10.21608/adjalexu.2020.82697>.
- Izgi AD, Kale E, Eskimez S. A prospective cohort study on cast-metal slot-retained resin-bonded fixed dental prostheses in single missing first molar cases: results after up to 7.5 years. *J Adhes Dent.* 2013;15(1):73-84. <http://dx.doi.org/10.3290/jjad.a29010>. PMID:23534027.
- Jeong KW, Kim SH. Influence of surface treatments and repair materials on the shear bond strength of CAD/CAM provisional restorations. *J Adv Prosthodont.* 2019;11(2):95-104. <http://dx.doi.org/10.4047/jap.2019.11.2.95>. PMID:31080570.
- Negreiros WM, Ambrosano GMB, Giannini M. Effect of cleaning agent, primer application and their combination on the bond strength of a resin cement to two yttrium-tetragonal zirconia polycrystal zirconia ceramics. *Eur J Dent.* 2017;11(1):6-11. http://dx.doi.org/10.4103/ejd.ejd_276_16. PMID:28435358.
- Schmalz G, Ryge G. Reprint of criteria for the clinical evaluation of dental restorative materials. *Clin Oral Investig.* 2005;9(4):215-32. <http://dx.doi.org/10.1007/s00784-005-0018-z>. PMID:16315023.
- Ayna E, Celenk S. Polyethylene fiber-reinforced composite inlay fixed partial dentures: two-year preliminary results. *J Adhes Dent.* 2005;7(4):337-42. PMID:16430016.
- Göhring TN, Roos M. Inlay-fixed partial dentures adhesively retained and reinforced by glass fibers: clinical and scanning electron microscopy analysis after five years. *Eur J Oral Sci.* 2005;113(1):60-9. <http://dx.doi.org/10.1111/j.1600-0722.2005.00182.x>. PMID:15693831.
- Silva LH, Lima E, Miranda RBP, Favero SS, Lohbauer U, Cesar PF. Dental ceramics: a review of new materials and processing methods. *Braz Oral Res.* 2017;31(Suppl. 1):e58. <http://dx.doi.org/10.1590/1807-3107bor-2017.vol31.0058>. PMID:28902238.
- Chaar MS, Kern M. Five-year clinical outcome of posterior zirconia ceramic inlay-retained FDPs with a modified design. *J Dent.* 2015;43(12):1411-5. <http://dx.doi.org/10.1016/j.jdent.2015.11.001>. PMID:26561926.
- Özkurt-Kayahan Z. Monolithic zirconia: a review of the literature. *Biomed Res.* 2016;27(4):1427-36.
- Kontonasaki E, Rigos AE, Ilia C, Istantos T. Monolithic zirconia: an update to current knowledge. optical properties, wear, and clinical performance. *Dent J.* 2019;7(3):90. <http://dx.doi.org/10.3390/dj7030090>. PMID:31480688.
- Ohlmann B, Rammelsberg P, Schmitter M, Schwarz S, Gabbert O. All-ceramic inlay-retained fixed partial dentures: preliminary results from a clinical study. *J Dent.* 2008;36(9):692-6. <http://dx.doi.org/10.1016/j.jdent.2008.04.017>. PMID:18550253.

21. Mattiello RDL, Coelho TMK, Insaurralde E, Coelho AAK, Terra GP, Kasuya AVB, et al. A review of surface treatment methods to improve the adhesive cementation of zirconia-based ceramics. *ISRN Biomater.* 2013;2013:185376.
22. Mahrous A, Radwan MM, Kamel SM. Micro-shear bond strength of novel mdp calcium-fluoride-releasing self-adhesive resin cement after thermocycling. *Int J Periodontics Restorative Dent.* 2020;40(3):445-55. <http://dx.doi.org/10.11607/prd.3992>. PMID:32233200.
23. Moncada G, Silva F, Angel P, Oliveira OB Jr, Fresno MC, Cisternas P, et al. Evaluation of dental restorations: a comparative study between clinical and digital photographic assessments. *Oper Dent.* 2014;39(2):E45-56. <http://dx.doi.org/10.2341/12-339-C>. PMID:23937403.
24. Hickel R, Peschke A, Tyas M, Mjör I, Bayne S, Peters M, et al. FDI World Dental Federation - clinical criteria for the evaluation of direct and indirect restorations. Update and clinical examples. *J Adhes Dent.* 2010;12(4):259-72. <http://dx.doi.org/10.1007/s00784-010-0432-8>. PMID:20847997.
25. Cavalcanti AN, Pilecki P, Foxton RM, Watson TF, Oliveira MT, Gianinni M, et al. Evaluation of the surface roughness and morphologic features of Y-TZP ceramics after different surface treatments. *Photomed Laser Surg.* 2009;27(3):473-9. <http://dx.doi.org/10.1089/pho.2008.2293>. PMID:19405819.
26. Zhang Y, Lee JJ, Srikanth R, Lawn BR. Edge chipping and flexural resistance of monolithic ceramics. *Dent Mater.* 2013;29(12):1201-8. <http://dx.doi.org/10.1016/j.dental.2013.09.004>. PMID:24139756.
27. Ha SR. Biomechanical three-dimensional finite element analysis of monolithic zirconia crown with different cement type. *J Adv Prosthodont.* 2015;7(6):475-83. <http://dx.doi.org/10.4047/jap.2015.7.6.475>. PMID:26816578.
28. Abou Tara M, Eschbach S, Wolfart S, Kern M. Zirconia ceramic inlay-retained fixed dental prostheses: first clinical results with a new design. *J Dent.* 2011;39(3):208-11. <http://dx.doi.org/10.1016/j.jdent.2010.12.005>. PMID:21185905.
29. Kohorst P, Brinkmann H, Li J, Borchers L, Stiesch M. Marginal accuracy of four-unit zirconia fixed dental prostheses fabricated using different computer-aided design/computer-aided manufacturing systems. *Eur J Oral Sci.* 2009;117(3):319-25. <http://dx.doi.org/10.1111/j.1600-0722.2009.00622.x>. PMID:19583762.
30. Yue X, Hou X, Gao J, Bao P, Shen J. Effects of MDP-based primers on shear bond strength between resin cement and zirconia. *Exp Ther Med.* 2019;17(5):3564-72. <http://dx.doi.org/10.3892/etm.2019.7382>. PMID:30988738.
31. Wolfart S, Bohlens F, Wegner SM, Kern M. A preliminary prospective evaluation of all-ceramic crown-retained and inlay-retained fixed partial dentures. *Int J Prosthodont.* 2005;18(6):497-505. PMID:16335169.
32. Rathmann F, Bömicke W, Rammelsberg P, Ohlmann B. Veneered zirconia inlay-retained fixed dental prostheses: 10-Year results from a prospective clinical study. *J Dent.* 2017;64:68-72. <http://dx.doi.org/10.1016/j.jdent.2017.06.008>. PMID:28647157.
33. Al-Moaleem M. Clinical evaluation of porcelain fused to metal inlay-retained bridges. *IOSR J Dent Med Sci.* 2014;13(9):129-33. <http://dx.doi.org/10.9790/0853-1396129133>.
34. Jevremović DP, Bošković MV, Puskar T, Williams R, Trifković B, Eggbeer D. A clinical evaluation of inlay-retained fixed partial dentures after a two-year observation period. *Acta Stomatol Naissi.* 2010;26(62):997-1006.
35. Bluma E, Vidzis A, Zigurs G. The influence of fixed prostheses on periodontal health. *Stomatologija.* 2016;18(4):112-21. PMID:28980541.
36. Chen J, Cai H, Suo L, Xue Y, Wang J, Wan Q. A systematic review of the survival and complication rates of inlay-retained fixed dental prostheses. *J Dent.* 2017;59:2-10. <http://dx.doi.org/10.1016/j.jdent.2017.02.006>. PMID:28212978.

Gomaa A. Soliman

(Corresponding address)

Cairo University, Faculty of Dentistry, Cairo, Egypt.

Email: Gomaasoliman@dentistry.cu.edu.eg

Date submitted: 2021 Jan 06

Accept submission: 2021 Feb 25