



## Amalgam allergy and Burning Mouth Syndrome: treatment and 25 years recall

Sérgio Eduardo de Paiva GONÇALVES<sup>1</sup> , Regina Célia Santos Pinto SILVA<sup>1</sup> , Ana Paula Martins GOMES<sup>1</sup> ,  
Karen Cristina Kazue YUI<sup>1</sup> , Daphne Camara BARCELLOS<sup>2</sup> , Eduardo BRESCIANI<sup>1</sup> , Mutlu ÖZCAN<sup>3</sup> 

1 - Universidade Estadual Paulista, Department of Restorative Dentistry, Institute of Science and Technology. São José dos Campos, SP, Brazil.

2 - Universidade Federal do Espírito Santo, Department of Prosthodontics. Vitória, ES, Brazil.

3 - University of Zurich, Department of Prosthetic Dentistry. Zurich, Switzerland.

### ABSTRACT

**Background:** Burning mouth syndrome (BMS) is a non-neuropathic chronic orofacial pain condition, characterized by the presence of burning/warm sensation without specific mucosal lesions. **Objective:** The aim of the present clinical case report is to describe the positive outcome of dental treatment of a patient with BMS and followed up for 25 years. **Data Treatment:** This report describes the case of a 50-year-old black woman sought treatment for burning, and persistent swelling of tongue (24h/day) occurring over years. Clinical evaluation of the oral environment revealed the tongue with cracking, darkened points areas, surrounded by whitish areas. Twelve teeth presented extensive amalgam restorations. Patch testing revealed a very strong hypersensitivity to Amalgam. All amalgam restorations were substituted by composite resin restorations. **Results and Conclusion:** Burning sensation disappeared completely after these restorations had been changed. After 25-year follow-up period, it was observed that burning sensation has never been felt anymore. **Clinical Significance:** Burning mouth syndrome is a chronic orofacial pain, usually without specific mucosal lesions. The etiology is complex and multifactorial and the treatment should be made specifically for each patient.

### KEYWORDS

Burning mouth syndrome; Composite resin; Dental amalgam.

### RESUMO

**Introdução:** A síndrome de ardência bucal (SAB) é uma condição de dor orofacial crônica não neuropática, caracterizada pela presença de sensação de queimação/calor sem lesões específicas da mucosa. **Objetivo:** O objetivo do presente relato de caso clínico é descrever a evolução positiva do tratamento odontológico de uma paciente com SAB e o retorno após 25 anos. **Tratamento dos Dados:** Este relato descreve o caso de uma mulher negra de 50 anos que buscou tratamento por queimadura e edema persistente da língua (24h/dia) ocorrendo ao longo dos anos. A avaliação clínica da cavidade bucal revelou a língua com áreas fissuradas e áreas com pontos escurecidos circundadas por áreas esbranquiçadas. Doze dentes apresentavam restaurações extensas de amálgama de prata. O teste de contato revelou hipersensibilidade muito forte ao amálgama de prata. Todas as restaurações de amálgama de prata foram substituídas por restaurações de resina composta. **Resultados e Conclusão:** A sensação de queimação desapareceu completamente após a substituição das restaurações. Após um período de 25 anos, observou-se que a sensação de queimação nunca foi mais relatada. **Significado Clínico:** a síndrome da ardência bucal é uma dor orofacial crônica, geralmente sem lesões específicas da mucosa. A etiologia é complexa e multifatorial e o tratamento deve ser feito especificamente para cada paciente.

### PALAVRAS-CHAVE

Síndrome da ardência bucal; Resina composta; Amálgama dentário.

## INTRODUCTION

Dental amalgam has been widely used as a restorative material for more than 120 years. Dental amalgam is composed approximately of 50% mercury, 22–32% silver, 14% tin, 8% copper and other metals. Allergic reactions to dental amalgam restorations have been related in literature, such as oral lichenoid reactions/lesions, toxic reactions, generalized sensitivity or a phenomenon called burning mouth syndrome (BMS) [1-4].

BMS is a non-neuropathic chronic orofacial pain condition, that occurs in intraoral cavity [2,4,5], and usually the patients complained of moderate to severe pain and can last for days or years, according to the International Association for the Study of Pain [2]. Patients usually relate the follow symptoms: a burning sensation in the mouth or tongue, such as partboil or on fire, been this feeling continuous and spontaneous. Clinically, BMS can be unaccompanied by mucosal and tongue injuries/lesions [2,4]. This chronic orofacial pain mainly affects middle-aged/old women, probably due to hormonal changes or psychological disorders [1] and has multifactorial and complex etiology, often idiopathic, with local, systemic and/or psychogenic factors. BMS occurs in a proportion of 1.5-5.5% of the population, and can be triggered by different dental materials such as metals (nickel, palladium, gold, mercury, cobalt) and acrylates [6]. The differential diagnosis, according to Scala et al. [1], is 'based on the exclusion of both other orofacial chronic pain conditions and painful oral diseases exhibiting mucosal lesions'.

The association of contact allergy with BMS has been reported between 13% and 65% [4,7] and this association was clinically confirmed by pain remission and patients were cured of the symptoms of BMS when the allergen is eliminated of the intraoral cavity, such as amalgam and resin direct restorations and indirect restorations [4,7]. Therefore, allergen skin patch testing is an important diagnostic tool to evaluate patients with BMS [4].

BMS can be classified into primary or idiopathic BMS, which is related to a neuropathic background and therapeutic resistance; and secondary BMS, caused by an underlying medical condition (such as xerostomia, nutritional deficiencies, medications, oral habits, endocrine disorders) which is developed by local and

systemic precipitating factors. The correct treatment has the objective of completely eliminate the pain [1,4]. Another possible classification of BMS is based on variations of pain: type 1 - spontaneous pain, and the symptoms occurs during the day; type 2 - constant pain during all day and Type 3 - intermittent symptoms [7].

Treatment strategy should be made according to each patient and diagnosis. For secondary BMS treatment should include replacement of teeth restorations using different materials. For chronic BMS, treatment can be made by corticosteroids and immunomodulatory agents. It is important to make a regular follow-up and psychological support to relieve the psychogenic component of the pain if the BMS patient has therapeutic resistance.

In the present publication, it is reported 1 case of 25 years follow-up of BMS patient, who was associated to hypersensitivity to dental amalgam.

## CASE REPORT

A 50-year-old black woman sought treatment for burning, and persistent swelling of tongue occurring over 15 years (Figure 1). The patient described the swelling as permanent and pronounced on the right and left sides of the tongue with warm sensations. She also revealed that burning sensation was felt 24h/day worsening during food intake, especially the spicy ones.

The patient sought a variety of specialists describing her burning sensation. Prescriptions involved some medications as analgesic and antacids, but without symptom relief.

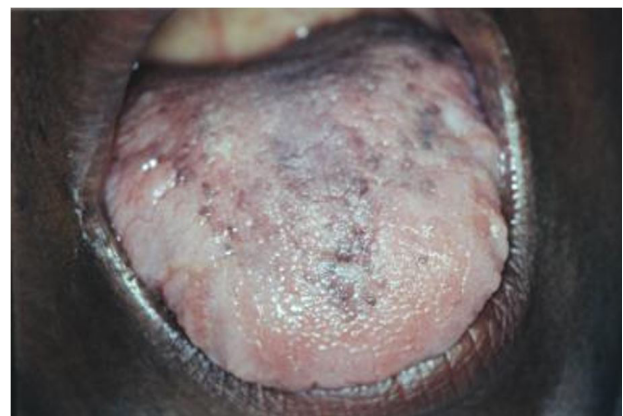


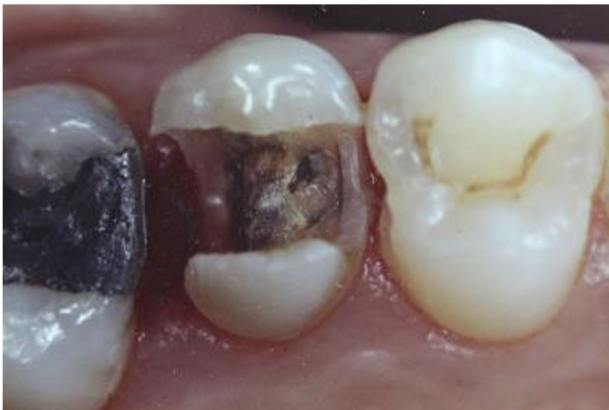Figure 1 - Clinical features of tongue with burning sensation.

Clinical evaluation of the oral environment revealed the tongue with cracking, darkened points areas, surrounded by whitish areas. Twelve teeth presented extensive amalgam restorations, some of them with secondary decay, marginal failure, new caries lesions (Figure 2) and the presence of calculus in some areas.

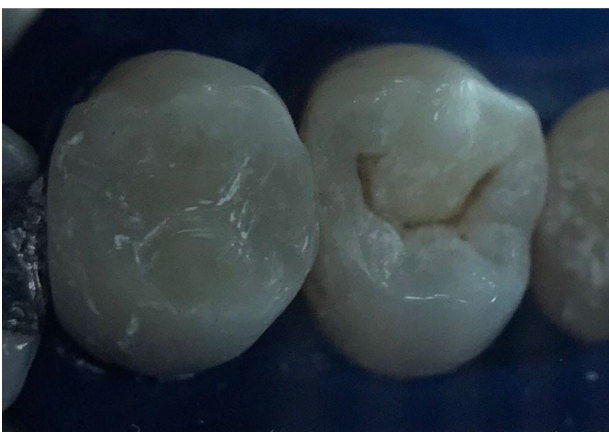She was asked to investigate hypersensitivity reactions by using patch testing. Patch testing was carried out in a specialized center in 1995. This test revealed a very strong hypersensitivity to Amalgam after 72h. The following symptoms was considered evidence of sensitization: erythema, infiltration (popular reaction), edema/erythema vesicles.

Blood exam did not reveal significant changes, with the presence of defense cells and absence of bacteria.

After this patch test's result and with the patient's consent, all restorations were changed and composite resin restorations were performed. The material chosen for replacement of the



**Figure 2** - Amalgam restoration on tooth 26; replacement of amalgam restoration with composite being performed on tooth 25; caries lesion on the distal of tooth 24.



**Figure 3** - Clinical features immediately after restorations on teeth 24 and 25.

restorations was the composite resin Z100 (3M) (Figure 3, 4).

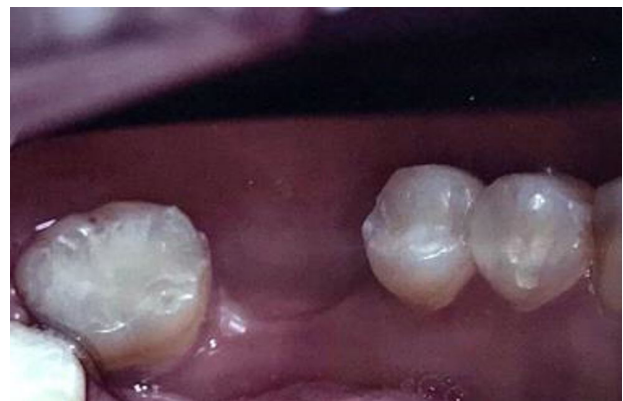Amalgam removal had strong effect on tongue lesions and burning sensation disappeared completely after these restorations had been changed.

Unfortunately the contact with the patient was lost, but her medical records were kept with our group for future attempts to contact.

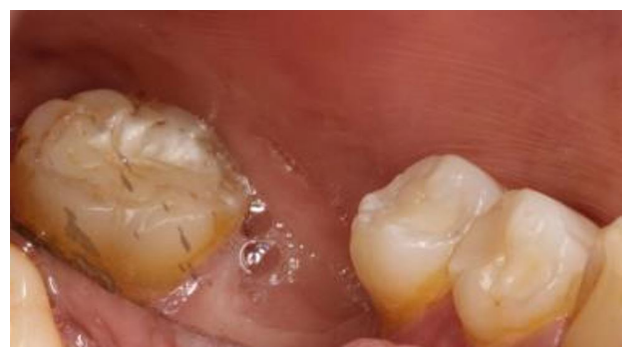Finally the contact attempts were successful. The patient returned for analysis after 25 years and revealed a person with some serious systemic problems such as: thyroid cancer and suspected breast cancer. In addition, high pressure, obesity and menopause have been described.

In her dental historic after 25 years, it was observed some resin restorations with 25 years of longevity (Figures 5) showing satisfactory performance. However, it was observed some periodontal problems, teeth fractured, teeth loss and new caries lesions (Figure 6).

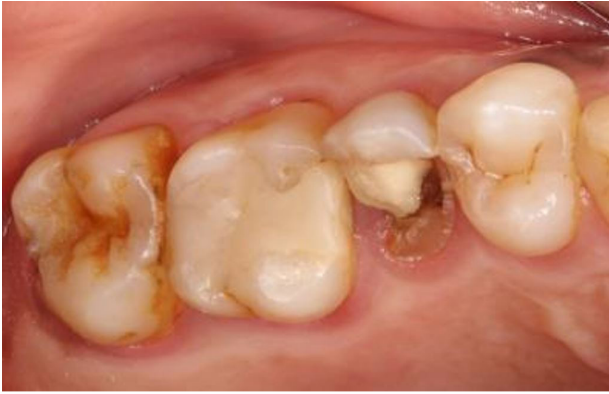Nevertheless, after 25 years of follow-up it was observed that burning sensation has never been felt anymore (Figure 7).



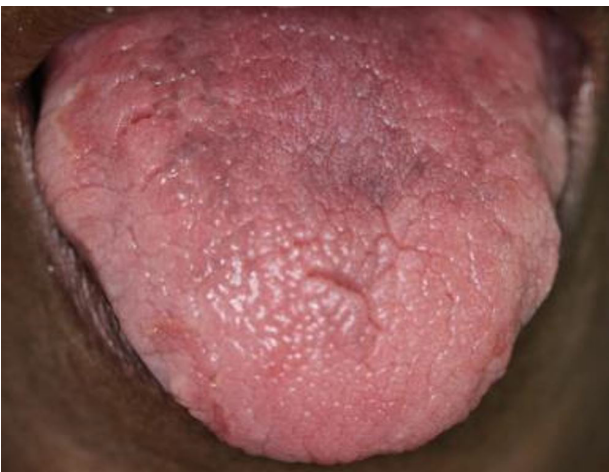**Figure 4** - Clinical features immediately after replacement of the restorations.



**Figure 5** - Clinical features of resin restorations after 25 years of longevity.



**Figure 6** - Clinical features after 25 years (teeth 24, 25): some periodontal problems, teeth fractured, caries lesions.



**Figure 7** - Clinical features of tongue after 25 years: burning sensation has never been felt anymore.

## DISCUSSION

Although BMS has been described for many years, it still poses a problem during diagnosis and treatment.

The BMS promoted by amalgam is closely related to amount of mercury released by dental amalgam restorations in the mouth and health problems reported by patients [8].

The International Association for the Study of Pain has identified BMS as a “distinctive nosological entity” described by continuously burning sensation in the intraoral cavity or similar pain without visually oral mucosa changes [7,9].

In this case report it was possible to observe some oral mucosa changes (over the tongue), but at the beginning, not directly related to the BMS. Due to being a meloderma patient, black spots surrounded by whitish areas were initially treated as a normal mucosa related to some hygienic problems.

It is extremely important to make the correct diagnosis, differing primary BMS from secondary BMS [1]. The primary BMS seems related to a neuropathic background and therapeutic resistance; secondary BMS is related by favoring by local and systemic precipitating factors. The etiology agent must be carefully analyzed, and the treatment should eliminate pain. BMS is commonly idiopathic, however, multifactorial local and systemic causes have been studied, such as contact hypersensitivity to allergens in the intraoral cavity; been this hypersensitivity mostly associated to secondary BMS. Apparently is what the reported case suggests. After amalgam removal, BM symptoms were totally eliminated.

Allergen skin patch testing is a very useful diagnostic means of evaluating patients with BMS [4]. However, it is very difficult to determine the clinical relevance of the positive reactions. They recommended to include hypersensitivity to dental components as a predisposing factor when intermittent or secondary BMS is being evaluated. In this specific case report, symptoms only got relief after amalgam removal. Any changes in terms of symptoms relief were not obtained by medicines.

Frequently, patients that show intraoral symptoms associated with amalgam dental restorations also reported physical symptoms everywhere in the body. These symptoms are resembling to patients that present multiple chemical sensitivity syndrome. These patients also presented mental problems [10]. Lygre et al. [11] believe that the differences between patients that search for treatment (experimental group) and patients that only answer a questionnaire about subjective health (reference group of general population) in intensity of symptoms is most obvious in terms of intraoral and orofacial symptoms. This maybe explains the reason of the patients associate general symptoms with intraoral symptoms due to dental materials. It was not observed in this specific case. BM symptom was felt by the patient but not correlated by her to dental materials or other health problem.

Eggleston [12] suggested a possibility of amalgam restoration opposite affect the quantity of T lymphocytes. In humans, metal-induced hypersensitivity occurs due to the reaction of the allergen with the memory surface of T lymphocytes, which were previously sensitized to a specific allergen. Memory cells can be activated

on contact with the allergen and start to produce lymphokines. The immunological diagnosis for delayed-type hypersensitivity occurs through antigen interaction with memory cells. The tests used for diagnosis are the correction and MELISA tests [13], as in this case.

According with Berlund [14], the levels of mercury vapor released in the oral environment for a period of 24 hours released in patients with at least 9 amalgam restorations, present daily levels lower than the limit value established by the WHO. However, true allergy to mercury is rare and mostly observed in feminine gender [15,16]. This occurs due the women seek medical and oral care more frequently compared to men and because of the occurrence of oral lichen planus more prevalent in the female gender. Studies show that gender hormones are associated with exacerbation of autoimmune diseases and allergies [16]. In patients with lichen planus the frequency of mercury hypersensitivity may vary 16 to 62% [13,17,18]. Ahlgren et al. [19] found more positive patch reactions to carvone and mercury in patients with oral lichenoid than in patients with dermatitis. However, the rate of positive patch test varies dramatically among the studies. Often, a higher frequency is observed in a study population that is suspected of being allergic to contact with dental materials or hygiene products [16].

The high percentage of patients sensitized to dental material and the presence of intraoral clinical symptoms (hypersensitivity) cannot be correlated [20]. This suggests the role of the oral mucosa as an important sensitization route, however, showing a high level of tolerance. Some patients can present contact dermatitis and none intra-oral lesions during examination.

Saliva has an important role of protection of oral environment, by washing and diluting allergenic substances. However, on the other hand, saliva can contribute to antigen presentation by providing molecules to sensitization [19]. It appears that saliva mercury levels are higher in individuals affected by multiple chemical sensitivity as compared with others [21].

Many researchers concluded that there is no scientific evidence of any adverse health effects promoted by dental amalgam, except to the sensitization with a positive patch test, which is rare [8,18].

Age is also correlated to the gender hormones in the development of the pathogenesis through immunological and endocrinological modifications affecting the intraoral mucosa making it more susceptible to oral diseases [16].

Patients who have high levels of mercury in their blood, however, have normal levels of urinary mercury, indicating that high levels of organic mercury originate from food, such as fish [22]. No changes in blood were observed in this specific case report.

The lack of information about the composition of dental materials is a very detrimental problem during the evaluation [22]. The manufacturers are not required to reveal detailed composition of their materials.

Correct diagnosis is extremely important because replacement of dental restorations is expensive and time consuming, causing discomfort, excessive loss of teeth structure, and sometimes pulp complications [23]. On this way, we also agree with Tomka et al. [24] that detailed allergy testing may help to identify a group of patients who may benefit from the allergen elimination. This was exactly what happened in our study.

This case report is in agreement with the findings of Raap et al. [3], who related that the highest number of positive patch test reactions was found in patients with lichen planus and BMS. The biopsy procedure was not necessary in the first instance from the positive result for amalgam obtained in the patch test.

No correlation between the time of presence or permanence of the dental amalgam and the systemic diseases developed by the patient over these 25 years can be established.

## CONCLUSION

The phenomenon of burning sensation disappeared completely after these restorations had been changed. After 25-year follow-up period, it was observed that burning sensation has never been felt anymore.

## Acknowledgments

The authors would like to thank retired professor Maria Amélia Máximo Araújo for coordinating patient care at 25 years ago.

## Conflict of Interest

The authors do not have any financial interest in the companies whose materials are included in this article.

## Funding

The work was supported by the Department Restorative Dentistry, Institute of Science and technology. UNESP - Univ Estadual Paulista, São José dos Campos, SP, Brazil.

## Regulatory Statement

The patient signed an informed consent form authorizing the treatment, which did not involve any experimentation in terms of restorative material or technique, and the use of images for teaching and dissemination purposes.

## REFERENCES

- Scala A, Checchi L, Montevicchi M, Marini I, Giamberardino MA. Update on burning mouth syndrome: overview and patient management. *Crit Rev Oral Biol Med*. 2003;14(4):275-91. <http://dx.doi.org/10.1177/154411130301400405>. PMID:12907696.
- Bender SD. Burning Mouth Syndrome. *Dent Clin North Am*. 2018;62(4):585-96. <http://dx.doi.org/10.1016/j.cden.2018.05.006>. PMID:30189984.
- Raap U, Stiesch M, Reh H, Kapp A, Werfel T. Investigation of contact allergy to dental metals in 206 patients. *Contact Dermat*. 2009;60(6):339-43. <http://dx.doi.org/10.1111/j.1600-0536.2009.01524.x>. PMID:19489970.
- Marino R, Capaccio P, Pignataro L, Spadari F. Burning mouth syndrome: the role of contact hypersensitivity. *Oral Dis*. 2009;15(4):255-8. <http://dx.doi.org/10.1111/j.1601-0825.2009.01515.x>. PMID:19302167.
- Oliveira FE, Almeida JD, Koga-Itao CY. Participation of microorganisms of dental interest in the etiology of Burning Mouth Syndrome: literature review. *Braz Dent J*. 2013;16(2):6-12. <http://dx.doi.org/10.14295/bds.2013.v16i2.864>.
- Dal Sacco D, Gibelli D, Gallo R. Contact allergy in the burning mouth syndrome: a retrospective study on 38 patients. *Acta Derm Venereol*. 2005;85(1):63-4. <http://dx.doi.org/10.1080/000155550410021457>. PMID:15858863.
- Klasser GD, Grushka M, Su N. Burning Mouth Syndrome. *Oral Maxillofac Surg Clin North Am*. 2016;28(3):381-96. <http://dx.doi.org/10.1016/j.j.coms.2016.03.005>. PMID:27475513.
- Weidenhammer W, Hausteiner C, Zilker T, Melchart D, Bornschein S. Does a specific dental amalgam syndrome exist? A comparative study. *Acta Odontol Scand*. 2009;67(4):233-9. <http://dx.doi.org/10.1080/00016350902915348>. PMID:19391051.
- Zakrzewska J, Buchanan JA. Burning mouth syndrome. *BMJ Clin Evid*. 2016;2016:1301. PMID:26745781.
- Feller L, Fourie J, Bouckaert M, Khammissa RAG, Ballyram R, Lemmer J. Burning Mouth Syndrome: aetiopathogenesis and principles of management. *Pain Res Manag*. 2017;2017:1926269. <http://dx.doi.org/10.1155/2017/1926269>. PMID:29180911.
- Lygre GB, Sjurson TT, Svahn J, Helland V, Lundekvam BF, Dalen K, et al. Characterization of health complaints before and after removal of amalgam fillings--3-year follow-up. *Acta Odontol Scand*. 2013;71(3-4):560-9. <http://dx.doi.org/10.3109/00016357.2012.697577>. PMID:22746255.
- Eggleston DW. Effect of dental amalgam and nickelalloys on T-lymphocytes: preliminary report. *J Prosthet Dent*. 1984;51(5):617-23. [http://dx.doi.org/10.1016/0022-3913\(84\)90404-9](http://dx.doi.org/10.1016/0022-3913(84)90404-9). PMID:6610046.
- Bains VK, Loomba K, Loomba A, Bains R. Mercury sensitization: review, relevance and clinical report. *Br Dent J*. 2008;205(7):373-8. <http://dx.doi.org/10.1038/sj.bdj.2008.843>. PMID:18849934.
- Berglund A. Estimation by a 24-hour study of the daily dose of intra-oral mercury vapour inhaled after release from dental amalgam. *J Dent Res*. 1990;69(10):1646-51. <http://dx.doi.org/10.1177/00220345900690100401>. PMID:2212208.
- Duxbury AJ, Watts DC, Ead RD. Allergy to dental amalgam. *Br Dent J*. 1982;152(10):344-6. <http://dx.doi.org/10.1038/sj.bdj.4804815>. PMID:7046771.
- Larsen KR, Johansen JD, Reibel J, Zachariae C, Pedersen AML. Symptomatic oral lesions may be associated with contact allergy to substances in oral hygiene products. *Clin Oral Investig*. 2017;21(8):2543-51. <http://dx.doi.org/10.1007/s00784-017-2053-y>. PMID:28084550.
- Bolewska J, Hansen HJ, Holmstrup P, Pindborg JJ, Stangerup M. Oral mucosal lesions related to silver amalgam restorations. *Oral Surg Oral Med Oral Pathol*. 1990;70(1):55-8. [http://dx.doi.org/10.1016/0030-4220\(90\)90178-U](http://dx.doi.org/10.1016/0030-4220(90)90178-U). PMID:2371051.
- McParland H, Warnakulasuriya S. Oral lichenoid contact lesions to mercury and dental amalgam: a review. *J Biomed Biotechnol*. 2012;2012:589569. <http://dx.doi.org/10.1155/2012/589569>. PMID:22888200.
- Ahlgren C, Axéll T, Möller H, Isaksson M, Liedholm R, Bruze M. Contact allergies to potential allergens in patients with oral lichen lesions. *Clin Oral Investig*. 2014;18(1):227-37. <http://dx.doi.org/10.1007/s00784-013-0950-2>. PMID:23455574.
- Rojas-Alcayaga G, Carrasco-Labra A, Danús P, Guzmán MA, Morales-Bozo I, Urzúa B, et al. Determination of susceptibility to sensitization to dental materials in atopic and non-atopic patients. *Med Oral Patol Oral Cir Bucal*. 2012;17(2):e320-4. <http://dx.doi.org/10.4317/medoral.17424>. PMID:22143693.
- Pigatto PD, Minoia C, Ronchi A, Brambilla L, Ferrucci SM, Spadari F, et al. Allergological and Toxicological aspects in a multiple chemical sensitivity cohort. *Oxid Med Cell Longev*. 2013;2013:356235. <http://dx.doi.org/10.1155/2013/356235>. PMID:24367721.
- Vamnes JS, Lygre GB, Grønningsaeter AG, Gjerdet NR. Four years of clinical experience with an adverse reaction unit for dental biomaterials. *Community Dent Oral Epidemiol*. 2004;32(2):150-7. <http://dx.doi.org/10.1111/j.0301-5661.2004.00148.x>. PMID:15061864.
- Liu YF, Kim Y, Yoo T, Han P, Inman JC. Burning mouth syndrome: a systematic review of treatments. *Oral Dis*. 2018;24(3):325-34. <http://dx.doi.org/10.1111/odi.12660>. PMID:28247977.
- Tomka M, Machovcová A, Pelclová D, Petanová J, Arenbergerová M, Procházková J. Orofacial granulomatosis associated with hypersensitivity to dental amalgam. *Oral Surg Oral Med Oral Pathol Oral Radiol Endod*. 2011;112(3):335-41. <http://dx.doi.org/10.1016/j.tripleo.2011.03.030>. PMID:21684771.

**Sérgio Eduardo de Paiva Gonçalves**

**(Corresponding address)**

Universidade Estadual Paulista, Institute of Science and Technology, Department of  
Restorative Dentistry, São José dos Campos, SP, Brazil.

Email: sergio.e.goncalves@unesp.br

Date submitted: 2021 Feb 22

Accept submission: 2021 Apr 06