



Assessment of satisfaction of patients submitted to bichectomy

Avaliação da satisfação dos pacientes submetidos à bichectomia

Emerson Filipe de Carvalho NOGUEIRA¹ , Juliana Ferreira Gomes de OLIVEIRA¹ , Fabrício Souza LANDIM¹ ,
Pamella Robertha Rosselinne Paixão CELERINO¹ , Bruno Luiz Menezes de SOUZA² , Ivson Souza CATUNDA¹ ,
Ricardo José de Holanda VASCONCELLOS¹

1 - Universidade de Pernambuco, Faculdade de Odontologia de Pernambuco, Departamento de Cirurgia Oral e MaxiloFacial, Hospital Oswaldo Cruz, Recife, PE, Brazil.

2 - Universidade Federal do Rio Grande do Norte, Natal, RN, Brazil.

ABSTRACT

Objective: The aim this research was assess the level of satisfaction of patients undergoing bichectomy and its repercussions. **Material and Methods:** A cross-sectional and qualitative study, under protocol number 20707519.5.0000.5207, was carried out by applying a questionnaire to patients undergoing bichectomy, which made it possible to assess complaints, degree of postoperative satisfaction, satisfaction of family members, time required to perceive results, complications and adverse effects, intensity of postoperative pain, and possibility of being submitted to a new intervention. **Results:** The sample consisted of 30 patients, among them, 82% sought surgery for aesthetic reasons. Regarding the degree of satisfaction, the majority (70%) were very satisfied, followed by 13.3% who were satisfied, 10% considered normal, 3.3% were dissatisfied and 3.3% very dissatisfied. Regarding the opinion of friends and family, the majority were very satisfied with the result. The adverse effects found were mild, no permanent injury happened, and the pain was mild in the most majority of the sample. **Conclusion:** Thus, the most majority of patients were satisfied with the results, as well as their family and friends. The results were more evident between the second and third months. No major or permanent damage was observed, suggesting that it is a safe technique when performed well.

KEYWORDS

Adipose tissue; Aesthetics; Mastication; Patient satisfaction.

RESUMO

Objetivo: Avaliar o nível de satisfação dos pacientes submetidos à bichectomia, bem como correlacionar os resultados com algumas características clínicas. **Material e Métodos:** Foi realizado um estudo transversal e qualitativo, sob protocolo número 20707519.5.0000.5207, através da aplicação de um questionário a pacientes submetidos à bichectomia, o qual foi possível avaliar as queixas, o grau de satisfação pós-operatório, a satisfação dos familiares, o tempo para percepção dos resultados, as complicações e efeitos adversos, intensidade da dor pós-operatória, e a possibilidade de ser submetido a nova intervenção. Além disso, as características demográficas da amostra (como sexo e idade) também foi registrada na ficha de avaliação. **Resultados:** A amostra foi composta por 30 pacientes, e desses, 82% buscaram a cirurgia por motivos estéticos. Sobre o grau de satisfação, a maioria (70%) ficou muito satisfeitos, seguidos por 13,3% que ficaram satisfeitos, 10% consideraram normal, 3,3% insatisfeitos e 3,3% muito insatisfeitos. Sobre a opinião dos amigos e familiares, a maioria ficou muito satisfeitos com o resultado. Os efeitos adversos encontrados foram leves, nenhuma lesão permanente foi encontrada, e a dor foi discreta na grande maioria da amostra. Com base na possibilidade de submeter-se a uma nova cirurgia, 70% ficaram satisfeitos e não fariam novamente. **Conclusão:** A grande maioria dos pacientes demonstrou-se satisfeitos com os resultados, bem como seus familiares e amigos. Os resultados foram mais evidentes entre o segundo e terceiro mês. Não foi observado qualquer dano importante ou permanente, sugerindo ser uma técnica segura quando bem executada.

PALAVRAS-CHAVE

Tecido adiposo; Estética; Mastigação; Satisfação do paciente.

INTRODUCTION

Currently, the search for aesthetic procedures on the face has become more common, since the standards of beauty required by society are increasingly frequent [1]. The reasons that lead patients to seek facial aesthetics procedures are connected to self-image, vanity, insecurity, intellectual and social acceptance [2]. Since the face is the most representative and valued body segment of the human being, it is natural that efforts to promote and conserve aesthetics and beauty are concentrated on it [3].

Bichectomy, a surgical procedure that aims to refine and outline the face, consists of removing the buccal extension of the adipose tissue from the cheeks, seeking to promote an outline of the lateral region of the face and show the malar prominence [4]. This structure is covered by a thin fibrous capsule, which delimits it in its entirety, being provided with a central body and four processes: buccal, pterygoid, deep temporal and pterygomaxillary. The technique only removes the buccal extension [4].

Several studies have found that aesthetic treatments have positive influences both on body image and on patients' quality of life [4]. Stevao (2015) [5] states that this procedure will give the face a marking in the middle third and the zygoma will be more evident, giving a younger and more aesthetic appearance, within a harmonious balance. The literature has demonstrated technical descriptions and case series of bichectomy, however there is still a great shortage of prospective studies with more in-depth analysis, including the assessment of the degree of satisfaction, which is the main objective when the technique is performed.

Therefore, the objective of this study was to assess the level of satisfaction of patients undergoing bichectomy, as well as to correlate the results with some clinical characteristics.

MATERIALS AND METHODS

A cross-sectional and qualitative study was carried out through the application of a questionnaire, which made it possible to assess complaints, the degree of postoperative satisfaction, the satisfaction of family members, the time to perceive results, complications and adverse effects, intensity of postoperative pain,

and the possibility of being submitted to a new intervention. In addition, the demographic characteristics of the sample (such as gender and age) were also recorded in the evaluation form. The respondent answered the questionnaire in an isolated place, as well as having his name hidden, and all signed the Informed Consent Form. The Research Ethics Committee of the University of Pernambuco approved the study under protocol number 20707519.5.0000.5207.

Patients who agreed to participate in this study underwent bichectomy at the Center for Clinical Research of Maxillofacial Surgery and Traumatology at the Faculty of Dentistry of Pernambuco at University of Pernambuco.

Patients with aesthetic or functional complaints in the cheek region, aged between 18 and 40 years, were included. As exclusion criteria, patients would be excluded: 1) with decompensated comorbidities that contraindicated surgery; 2) with acute or chronic parotitis; 3) with limited mouth opening that made the procedure impossible; and 4) who have answered the questionnaire incompletely were excluded.

The assessment was carried out using a questionnaire (modified Alsarraf satisfaction questionnaire) [4]. Patients were asked about the reason for undergoing the surgery. The digital questionnaire was applied via electronic message (e-mail or SMS), using the Google Form (Google®), and filled in at least 6 months after the surgery.

Regarding the degree of satisfaction after the procedure, the modified Alsarraf satisfaction questionnaire [4] was used and patients had to classify it as: very satisfied; satisfied; normal; dissatisfied; or very dissatisfied. Patients were also asked what impression family members had of the surgery.

The pain variable was analyzed using the visual analogue scale (0-100) and applied at the return visit, 7 days after the procedure. Measurements from 0 to 3 were considered as absence of pain or mild discomfort; 3 to 5, mild pain; 6 to 8, moderate pain; above 8, severe pain.

Regarding the time they noticed the results of the surgery, the patients were asked about when the aesthetic change was noticeable.

Possible complications were also evaluated, such as pain, infection, edema, difficulty to

open the mouth, numbness, hemorrhage, facial paralysis, and others. Pain assessment was also performed using the Visual Analogue Scale.

In the data analysis, for the description of the study population, the frequency distribution of all variables was used, pre-categorized and arranged in the EXCEL® program, which made it possible to organize the descriptive data, make the results of the graphs available and fill in the tables. The number were presented using absolute numbers and percentages.

RESULTS

The total sample of respondents was composed of 30 patients undergoing bichectomy, in which three (10%) were male and 27 (70%) female.

When asked about how long since when they had undergone bichectomy, 13 patients (43.33%) had it from 3 to 6 months ago; 8 (26.66%) from 6 to 9 months ago; 2 (6.6%) from 10 to 12 months ago; and 7 (23.33%) over 12 months ago.

Regarding the reason why they underwent bichectomy, 23 patients had only aesthetic reasons, six had trauma to the cheek mucosa and one had both. None of them had complaints of difficulty to speak, chew or local pain (Figure 1).

Regarding the degree of satisfaction after the procedure, 70% were very satisfied, 13.3% were satisfied, 10% found it normal, 3.3% were dissatisfied and 3.3% very dissatisfied (Figure 2). The degree of satisfaction of their friends and family is shown in Figure 3.

Regarding how long after the surgery it was possible to notice the aesthetic difference, one patient (3.3%) noticed it in the immediate postoperative period, nine patients (30%) in the first month, 10 patients (33.3%) in the second month, eight patients (26.6%) in the third month, three patients (10%) in the fourth month and one patient (3.3%) had not noticed the difference until that moment.

Regarding post-surgical complications, Table I shows the results found and Figure 4 shows the intensity of postoperative pain according to the Visual Analogue Scale.

Based on the possibility of undergoing a new surgery, the following results were obtained: 70% (21) would not undergo a new procedure; 23.3%

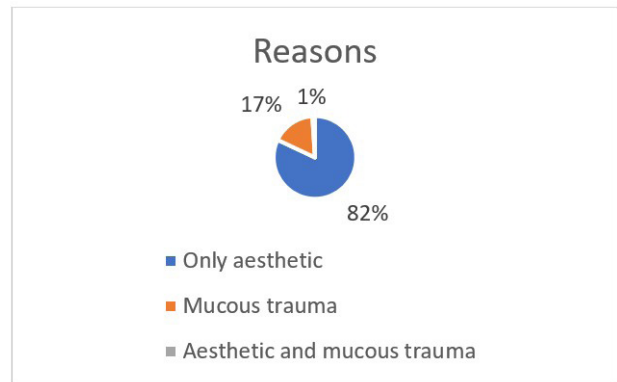


Figure 1 - Reasons why respondents underwent bichectomy.

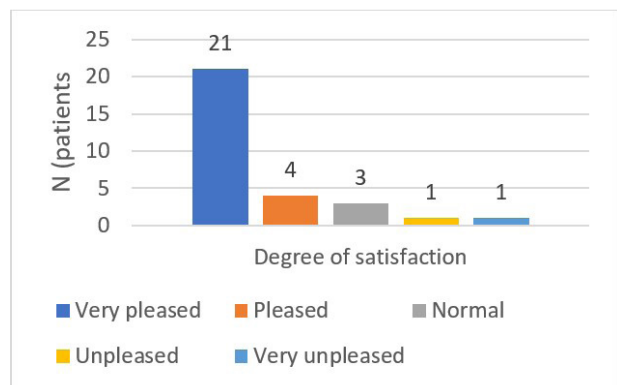


Figure 2 - Evaluation of the degree of satisfaction of patients undergoing bichectomy.

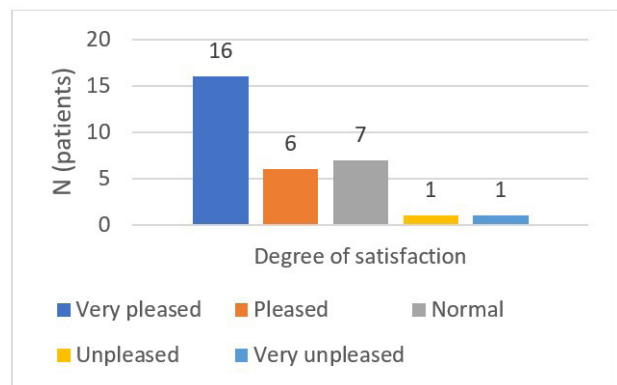


Figure 3 - Assessment of the degree of satisfaction of friends and family members of patients undergoing bichectomy.

Table I - Complications found in the postoperative period of patients undergoing bichectomy

ADVERSE EFFECTS	YES	NO
	N (%)	N (%)
Pain	8 (26.67)	22 (73.33)
Infection	0 (0)	30 (100)
Edema	17 (56.7)	13 (43.3)
Difficulty opening your mouth	17 (56.7)	13 (43.3)
Bleeding	0 (0)	30 (100)
Paresthesia	4 (13.3)	26 (86.7)
Paralysis	1 (3.3)	29 (96.7)
Bruise	1 (3.3)	29 (96.7)

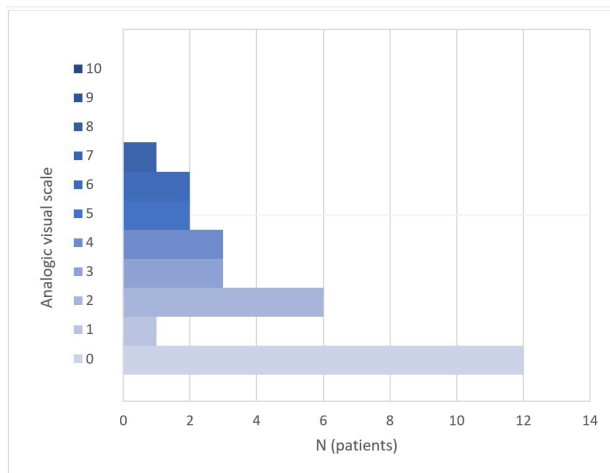


Figure 4 - Intensity of postoperative pain in the interviewed patients.

(7) would like to change the appearance of their cheek with a new surgery; 3.3% (1) perhaps would undergo a bichectomy again; and 3.3% (1) patient reports that one facial side was more outlined than the other and would like to redo the surgery to fix it.

DISCUSSION

Bichectomy consists of the removal of the Adipose Body from the Cheek, or also called Bichat fat, and has been a success in the scope of facial surgical interventions. It is generally indicated for patients who essentially want to have a more defined facial shape or improve masticatory comfort, particularly patients who had trauma in the cheek mucosa while chewing [5].

Stevao [5] concluded that this surgery has several advantages, such as: improved facial appearance, outlined cheeks, increased patient self-esteem and increased confidence regarding his physical appearance. In the study, it was possible to observe that almost all (90%) were female patients and 82% sought surgery for aesthetic purposes in order to acquire a better contour of the cheeks and, consequently, an improved facial harmony.

Aesthetics appears as an extremely important value in our society [6]. In the West, female aesthetics function as an important social mark in the classification and hierarchy of lifestyles, as well as social and affective ascension. For Capozzoli [7], women have much higher levels of body dissatisfaction than men, resulting in the constant search for medical plastic surgeries

that lead to their physical and mental well-being, reducing anxiety and improving their self-esteem [8]. These data were also observed in the present research, where women sought surgery more than men did.

The literature states that the results of bichectomy are noticed in the period that varies from days to approximately 6 months after the surgery, during which the soft tissue edema is definitely reabsorbed [9]. In the present research, it was observed that more than 2/3 of the interviewees noticed the improvement of the facial contour until the 3rd month of surgery, which suggests that this is an important information given even in the preoperative period, thus avoiding high expectations in the first weeks.

Approximately 84% of patients were very satisfied or satisfied with the result of the procedure. People seek aesthetic surgery not only to change their appearance, but also to transform psychological aspects related to the body or parts of it. A result similar to that published by Silva et al. [1], in which they evaluated 16 patients who underwent bichectomy, and were assessed about the degree of satisfaction based on a scale from 0 to 10. They obtained an average score of nine, demonstrating a high degree of satisfaction.

The patient satisfaction index and psychological tests for personality assessment were more productive. There are, in general, main reasons for the patient to seek plastic surgery, such as gaining more self-confidence. The investigation of the results of surgical treatment should also be done based on the psychological gain achieved after surgery [10]. The results of this study were considered satisfactory, stating that it was possible to observe a significant difference in facial contour and in patients' self-esteem as well.

Regarding the opinion of friends and family, the most majority (73.3%) also found the appearance of the cheek satisfactory after removing the Bichat fat, thus contributing to the strengthening of the patient's psychosocial well-being and elevation of your self-esteem. However, there are still no studies that demonstrate the degree of impact that the satisfaction of family and friends will have on the lives of the interviewees.

Based on the possibility of undergoing a new intervention, only two patients would think about the possibility of performing it. In one of these patients, it was not possible to locate Bichat's fat in one side, and in the other patient, less fatty material was removed. In addition, some authors claim that excessive fat removal during the bichectomy procedure may result in the need for facial filling with a fat graft. Thus, the careful removal of the projected fat is of great importance, during the procedure, without excessive traction, and with delicate movements [9].

Understanding the distribution of facial fat and its changes according to facial shape, gender, weight, height, BMI, weight and removed adipose volume is essential to obtain facial rejuvenation. Several previous studies have shown that facial fat is highly compartmentalized. It is not yet clear whether the compartments gain or lose volume or if they change their shape over time. In addition, when the volume of the structure is small, the surgeon can discuss with the patient, at the end of the procedure, about the subtle results that are likely to occur, since through clinical examination it is not possible to pre-determine the total volume of fat to be removed [11].

It is worth mentioning that no patient had a serious or permanent complication in the postoperative period. Approximately half of the patients had edema and trismus, symptoms consistent with the surgical procedure, and the most majority reported only mild local discomfort. After the procedure, four patients reported temporary numbness in the face lasting 5 days, but it is suggested that it was during the maximum edema phase, and one patient had temporary paralysis with 3 days of evolution. It is extremely important to emphasize that only one patient had a mild hematoma at the site without any other associated symptoms. According to the literature, some complications of important complexity can occur, such as parotid duct stenosis, a consequence of a wrong incision causing salivary fistulas [12]. No patient in the study had an alteration in the parotid duct. Facial nerve damage can also occur and manifest through temporary or permanent paresthesia, depending on the severity of the injury. Just over half of the patients presented difficulty to open mouth after the procedure. On the other hand, none of the interviewees had an oral infection. These results were similar to the study by Alvarez

and Siqueira [13] in which they performed bichectomy in 27 patients and no permanent and important complications were found. Among a series of cases published by Silva et al. [1], two cases evolved with postoperative infection and were treated with antibiotics.

Most patients reported no discomfort or mild discomfort, indicating that bichectomy is usually a surgery that does not cause major inconveniences.

Another finding was that approximately $\frac{1}{4}$ of the interviewees would undergo a new procedure to improve their results. As the aesthetic evaluation is subjective, some patients choose the more evident demarcation expected by the bichectomy.

Both Matarasso [14] and Brasil et al. [15] argue that knowledge of the anatomy of this structure and its surroundings becomes crucial for a correct diagnosis and implementation of an excellent treatment plan, as well as taking into account the patient's face and possible facial asymmetries.

CONCLUSIONS

The results found in the present research demonstrate that women sought more to perform bichectomy than men did and the main reason was the improvement in facial aesthetics. The most majority of patients were satisfied with the results, as well as their family and friends. The results were more evident between the second and third months.

No major or permanent damage was observed, suggesting that it is a safe technique when performed well.

Author Contributions

EFCN: setting up the experiment and collecting data/tabulation, statistical analysis of data and creation of tables and figures/identification of species and standardization of scientific names with their respective authors/revision of the text and addition of significant parts. JFGO: setting up the experiment and collecting data/Tabulation, statistical analysis of data and creation of tables and figures/Identification of species and standardization of scientific names with their respective authors/Writing of the text and standardization of the

rules according to the magazine. FSL: Setting up the experiment and collecting data. PRRPC: writing of the text and standardization of the rules according to the magazine. BLMS: setting up the experiment and collecting data. ISC: Tabulation, statistical analysis of data and creation of tables and figures. RJHV: identification of species and standardization of scientific names with their respective authors/Revision of the text and addition of significant parts.

Conflict of Interest

No conflicts of interest declared concerning the publication of this article.

Funding

The authors declare that no financial support was received.

Regulatory Statement

The Research Ethics Committee of the University of Pernambuco approved the study under protocol number 20707519.5.0000.5207.

REFERENCES

1. Silva RD, Leite LDF, Cavalcante WC, Cerqueira A. Bichectomy as facial aesthetic procedure: prospective observational study. *J Braz Coll Oral Maxillofac Surg*. 2019;5(3):17-23. <http://dx.doi.org/10.14436/2358-2782.5.3.017-023.oar>.
2. Ferreira JB, Lemos LMA, Silva TR. Qualidade de vida, imagem corporal e satisfação nos tratamentos estéticos. *Revista Pesquisa em Fisioterapia*. 2016;6(4):402-10. <http://dx.doi.org/10.17267/2238-2704rpf.v6i4.1080>.
3. Feitosa DAS, Dantas DCRE, Guenes GMT, Ribeiro AIAM, Cavalcanti AL, Braz R. Percepção de pacientes e acadêmicos de Odontologia sobre estética facial e dentária. *Rev Fac Odontol Univ Nac*. 2009;14(1):23-6.
4. Kahn JL, Wolfram-Gabel R, Bourjat P. Anatomy and imaging of the deep fat of the face. *Clin Anat*. 2000;13(5):373-82. [http://dx.doi.org/10.1002/1098-2353\(2000\)13:5<373::AID-CA7>3.0.CO;2-W](http://dx.doi.org/10.1002/1098-2353(2000)13:5<373::AID-CA7>3.0.CO;2-W). PMID:10982997.
5. Stevao ELL. Bichectomy or bichatectomy-a small and simple intraoral surgical procedure with great facial results. *Adv Dent & Oral Health*. 2015;1(1):1-4.
6. Garcia RP, Lemos KM. A Estética como um valor na Educação Física. *Rev Paul Educ Fis*. 2003;17(1):32-40. <http://dx.doi.org/10.11606/issn.2594-5904.rpef.2003.138841>.
7. Capozzoli CJ. Motivação à prática regular de atividades físicas: um estudo com praticantes em academias de ginástica de Porto Alegre (Dissertação de Mestrado em Ciências do Movimento Humano). Escola de Educação Física, UFRGS, Porto Alegre, 2006.
8. Juchem L, Balbinotti CAA, Balbinotti MAA, Barbosa MLL, Saldanha RP. A motivação para a prática regular de atividades físicas: um estudo descritivo-exploratório com tenistas do sexo masculino de 13 à 16 anos. *Coleç Pesqui Educ Fís*. 2007;6(2):19-24.
9. Moreira Junior R, Peralta FS, Moreira R, Gonticho G, Máximo PM, Scherma AP. Bichectomia: aspectos relevantes e relato de caso clínico. *Clínica e Pesquisa em Odontologia*. 2018;9(1):37-43.
10. Ferreira MC. Cirurgia plástica estética: avaliação dos resultados. *Ver Soc Bras Cir Plást*. 2000;15(1):55-66.
11. Faria CADC, Dias RCS, Campos AC, Daher JC, Costa RSC, Barcelos LDP. Bichectomia e sua contribuição para harmonia facial. *Rev Bras Cir Plast*. 2018;446-52.
12. Almeida AVVA, Alvary PHG. A bichectomia como procedimento facial. *Bus Tech J*. 2018;1(7):3-14.
13. Alvarez GS, Siqueira EJ. Bichectomia: sistematização técnica aplicada a 27 casos consecutivos. *Rev Bras Cir Plast*. 2018;33(1):74-81.
14. Matarasso A. Managing the buccal fat pad. *Aesthet Surg J*. 2006;26(3):330-6. <http://dx.doi.org/10.1016/j.asj.2006.03.009>. PMID:19338917.
15. Brasil LFM, Polo TOB, Momesso GAC, Santos GM, Lima VN, Faverani LP. Reparos anatômicos para cirurgia de bichectomia. *Arch Health Invest*. 2016;5(1):359.

Juliana Ferreira Gomes de Oliveira
(Corresponding address)

Universidade de Pernambuco, Faculdade de Odontologia de Pernambuco,
Departamento de Cirurgia Oral e MaxiloFacial, Hospital Oswaldo Cruz, Recife, PE,
Brazil.
Email: julianafgolv@gmail.com

Date submitted: 2021 Apr 28
Accept submission: 2021 July 12