



## Reference standard thickness for bone plates of upper teeth: an ultra-high-resolution study using tomographic mapping

Padrão de referência de espessura para cristas ósseas de dentes superiores: um estudo de ultra-alta resolução usando mapeamento tomográfico

ANA CARLA RAPHAELLI NAHÁS-SCOCATE<sup>1</sup> , Sílvia NEGRISOLI<sup>1</sup> , Lucas Domingos LABEGALINI<sup>1</sup> , Murilo MATIAS<sup>1</sup> , Michel Eli LIPIEC-XIMENEZ<sup>2</sup> , Israel CHILVARQUER<sup>3</sup> , Jamil Awad SHIBLI<sup>1</sup>

1 - Universidade Guarulhos (UNG), Faculdade de Odontologia, Departamento de Ortodontia. Guarulhos, SP, Brazil.

2 - Instituto de Documentação Ortodôntica e Radiodiagnóstico (INDOR). São Paulo, SP, Brazil.

3 - Universidade de São Paulo (USP), Faculdade de Odontologia, Departamento de Radiologia. São Paulo, Brazil.

### ABSTRACT

**Objective:** it is important to know the thicknesses of the alveolar bone plates (ABPs) based on the current literature for the planning and success of orthodontic treatment. However, studies have scientific limitations regarding ABPs as the image resolution is not adequate and is restricted to a few teeth or buccal face only. This study was aimed at reporting a reference standard for bone plates of upper teeth, in which 15 patients (mean age of 21.79 years) with balanced occlusion and a harmonious facial profile were evaluated using cone-beam computed tomography at a voxel size of 0.1 mm. **Material and Methods:** bone tissues of the cervical, middle, and apical thirds of the root (buccal and palatal), the distance between cement-enamel junction (CEJ) and alveolar bone crest (ABC), and inclination of the teeth to the palatal plane were evaluated. Paired t-test, Spearman's correlation tests, and linear regression tests were used ( $P < 0.05$ ). **Results:** the buccal distance between the CEJ and ABC was greater than the palatal one in all pairs of teeth. Most of the bone tissues had a thickness  $\leq 1$  mm in the buccal face, whereas in the cervical-apical direction, the thickness was  $\geq 2$  mm. There is no equivalence between genders in the sample. **Conclusion:** the reduced buccal bone architecture around the first premolars was indicative of local gingival recessions, and the lack of gender uniformity was suggestive of individual evaluation. References of normal bone tissue determining the orthodontic limits were provided to assist in the treatment planning.

### KEYWORDS

Bone tissue; Cone-beam computed tomography; Alveolar process; Orthodontics; Diagnosis.

### RESUMO

**Objetivo:** é importante conhecer as espessuras das cristas ósseas alveolares (COAs) com base na literatura atual para o planejamento e sucesso do tratamento ortodôntico. No entanto, os estudos apresentam limitações científicas em relação às COAs, pois a resolução da imagem não é adequada e está restrita apenas a alguns dentes ou face vestibular. Este estudo teve como objetivo descrever um padrão de referência para corticais ósseas de dentes superiores, no qual 15 pacientes (idade média de 21,79 anos) com oclusão equilibrada e perfil facial harmonioso foram avaliados por meio de tomografia computadorizada de feixe cônico no tamanho de voxel de 0,1 mm. **Material e Métodos:** os tecidos ósseos dos terços cervical, médio e apical da raiz (vestibular e palatina), a distância entre a junção cimento-esmalte (JCE) e a crista óssea alveolar (COA) e a inclinação dos dentes ao plano palatino foram avaliados. Foram utilizados o teste t pareado, os testes de correlação de Spearman e os testes de regressão linear ( $P < 0,05$ ). **Resultados:** a distância vestibular entre a JEC e a COA foi maior que a palatina em todos os pares de dentes. A maioria dos tecidos ósseos apresentou espessura  $\leq 1$  mm na face vestibular, enquanto no sentido cérvico-apical a espessura foi  $\geq 2$  mm. Não há equivalência entre os gêneros na amostra. **Conclusão:**

a arquitetura óssea vestibular reduzida ao redor dos primeiros pré-molares foi indicativa de recessões gengivais locais, e a falta de uniformidade de gênero foi sugestiva de avaliação individual. Referências de tecido ósseo normal determinando os limites ortodônticos foram fornecidas para auxiliar no planejamento do tratamento.

## PALAVRAS-CHAVE

Tecido ósseo; Tomografia computadorizada de feixe cônico; Processo alveolar; Ortodontia; Diagnóstico.

## INTRODUCTION

Assessment of alveolar bone thicknesses is extremely important in the orthodontic treatment as tilting movements of the teeth, mainly buccally, should respect the biological limitations of the bone plates in order to avoid unfavourable repercussions to the supportive and protective periodontal tissues. Bone dehiscences and fenestrations may develop or even worsen when iatrogenic orthodontic treatment is performed in the presence of periodontal inflammation [1-6]. Amount of bone density around the dental root as well as the position of the root apex are major anatomical landmarks in the planning of root torque movements [1,3,7-12].

Nowadays, because of the high number of adult patients with periodontal problems who seek orthodontic treatment for aesthetics, self-esteem and social interaction [9,13,14], the integration between periodontics and orthodontics has been valued by the rehabilitating benefits achieved in the long term. In this scenario, orthodontic aligners have been chosen by part of the patients and practitioners to replace the conventional fixed appliances as they apply mild forces [9,15,16] and provide comfort and biomechanical effectiveness, besides allowing to be personalised, aesthetical and removable. Application of mild forces is an important characteristic in the treatment of patients with thin bone plates, mainly in the buccal face [7,12].

Many scientific studies emphasise the measurement of bone plate thickness in the anterior and buccal faces before and after treatment, but no thickness pattern has been reported by using tomographic images acquired with adequate voxel size [12,17-20]. Periodontal diagnosis has become more precise when made together with three-dimensional images obtained with cone beam computed tomography (CBCT) without magnification (exact linear measurements 1:1) [17], thus allowing to obtain reliable measurements of the bone structures [18,21]. There

are several studies reporting the importance of this resource [4,13,14,22-24], but reservations should be made regarding the image resolution at voxel sizes ranging from 0.25 to 0.3 mm [19,20,24-26]. Bone plates have more precise and reliable measurements when scanned at high resolution (e.g., a small voxel size of 0.1 mm) because of their thin anatomical structures, mainly in the buccal face.

The provision of a standard of bone plate thicknesses, with new reference values based on a population with static dental occlusion and ideal facial pattern, can assist in the indication of root torques in the pre-treatment phase in order to preserve healthy periodontal structures or even improve them as well as to identify alveolar bone levels impeding or limiting certain types of orthodontic movements, which can decrease the longevity of the supportive and protective periodontal tissues [3,4,14,17]. In this way, the practitioner could feel more confident when performing the procedures, mainly regarding expansive movements of the dental arches.

In view of the importance of evaluating the alveolar bone plates before, during and after treatment, this study has established a reference standard for bone plates of upper teeth in patients with harmonious facial profile and balanced occlusion who had never been orthodontically treated. High resolution CBCT was used with a voxel size of 0.1 mm for a precise diagnosis and treatment planning.

## MATERIAL AND METHODS

This study was approved by the Research Ethics Committee of the University of Guarulhos (UNG) according to protocol number CAAE 89786318-8-0000-5506.

### Sample

The sample consisted of tomographic records provided by the Oral Radiology and Orthodontic Documentation Institute (*INDOR*), São Paulo, Brazil,

and which were previously obtained for diagnosis of the intra-osseous position of third molars. Tomographic images were selected according to the following inclusion criteria: patients presenting Class I skeletal malocclusion, normal occlusion, harmonious facial profile and no previous history of orthodontic treatment (data from digital files) and whose tomographic images were acquired with voxel size of 0.1 mm. The exclusion criteria were the following: patients with missing upper teeth, agenesis, dental anomalies of shape and number or bone pathologies; patients wearing prosthesis; patients endodontically or orthodontically treated; patients younger than 14 or older than 35 years old; and patients with periodontal disease. From the 249 patients, only 15 individuals were selected for study, in which 11 were female and four male aged between 14 and 32 years old (mean age of 21.79 years).

The teeth were the following: upper central incisors (teeth #11 and #21), upper lateral incisors (teeth #12 and #22), upper canines (teeth #13 and #23), upper first molars (teeth #14 and #24) and upper second premolars (teeth #15 and #25). Molars were not included in the sample because their bone plates could not be accurately visualised as a whole. Therefore, a total of 150 teeth were evaluated, yielding 1,200 linear and 150 angular measurements. Sample power was 99% and alpha value was 0.05.

### Image acquisition

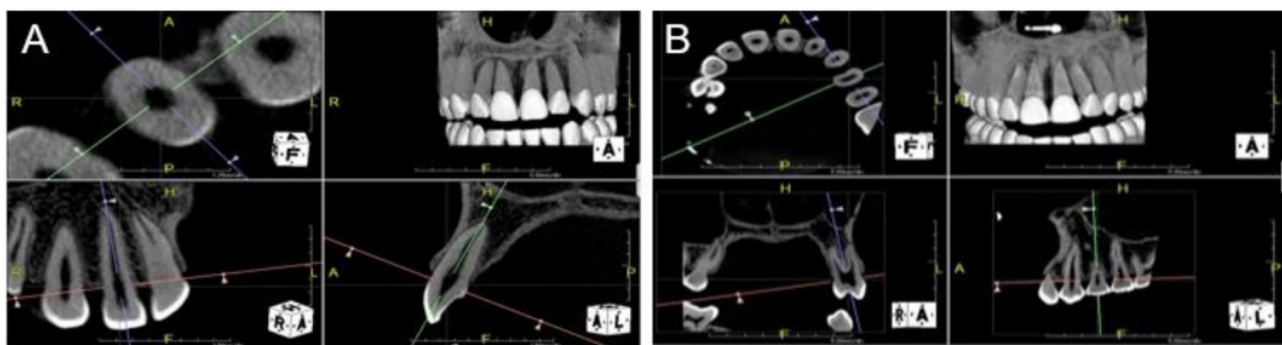
CBCT images published in this article were obtained from PreXion3D tomography (PreXion 3D, Inc., San Mateo, CA, USA) operating at 90 kV, 4 mA, exposure time of 37 seconds, voxel size of

0.1 mm, and field of view of 5 x 5 (56 cm diameter) was used for acquisition of the images, which were processed in DICOM format and analysed with a conventional computer. Volumetric reconstructions of the maxilla were carried out using the software PrexViewer (PreXion, Inc., San Mateo, CA, USA), version 2.2.1.1. Each patient was seated in an erect position, with the Frankfort plane being in parallel to the floor during the scanning process. All tomographic images were assessed, and measurements were made by only one examiner (L.D.L.) for calculation of intra-rater error and by another examiner (S.N.) for inter-rater calculation.

### Anterior and posterior teeth

A methodological sequence was used to assess linear and angular measurements based on a protocol set by Nahás-Scocate, Scocate (2014); Nahás-Scocate et al. (2014) [13,27]. In the coronal view, the software's horizontal line was positioned to obtain the best axial section of the pulp chamber, whereas in the axial view, the horizontal and vertical lines of the software were positioned at the centre of the pulp chamber to be observed. Next, in the sagittal and coronal views, the software's vertical line was positioned on the long axis of the root. The sagittal view of the anterior teeth and coronal view of the posterior ones were maintained on a single screen to allow a better visualisation of the section to be measured (Figure 1A-1B).

A line was traced on the cement-enamel junction (CEJ) by using the software's distance tool and setting the magnitude between 7 and 8 mm/div. All the measurements were obtained by using the software's configuration Tooth2 for



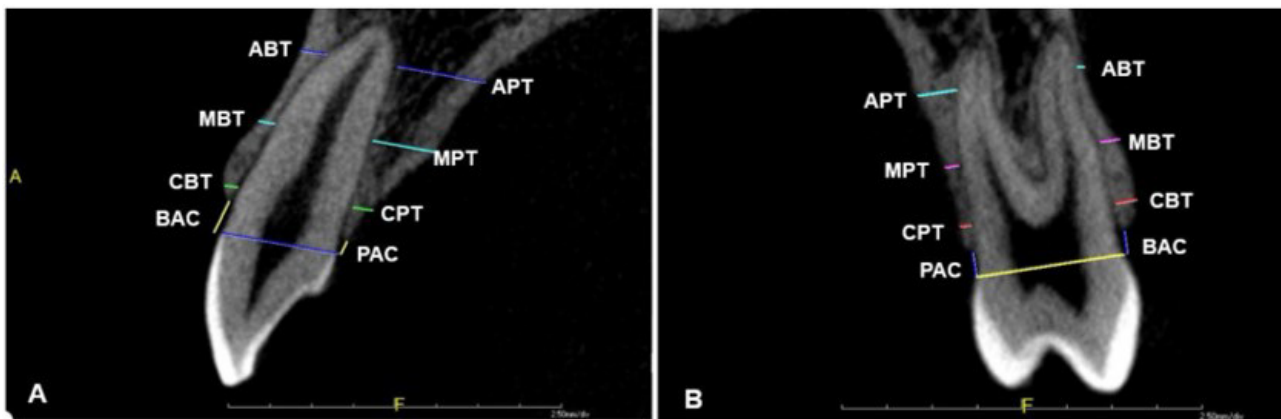
**Figure 1** - Three-dimensional multiplanar reconstructions. (A) selection of section for measurement of anterior teeth and (B) selection of section for posterior teeth.

multiplanar re-construction. The distance from the buccal face to the palatal face on the CEJ was measured (x) and divided into half (y) in order to draw the long axis of the root in relation to the apex. Long axes of the buccal and palatal roots were traced for measurement of the bone plates of the posterior teeth, in which a line passed through the half of the distance “y” and apex of each root, with the buccal bone plate corresponding to the buccal root and palatal bone plate corresponding the palatal root.

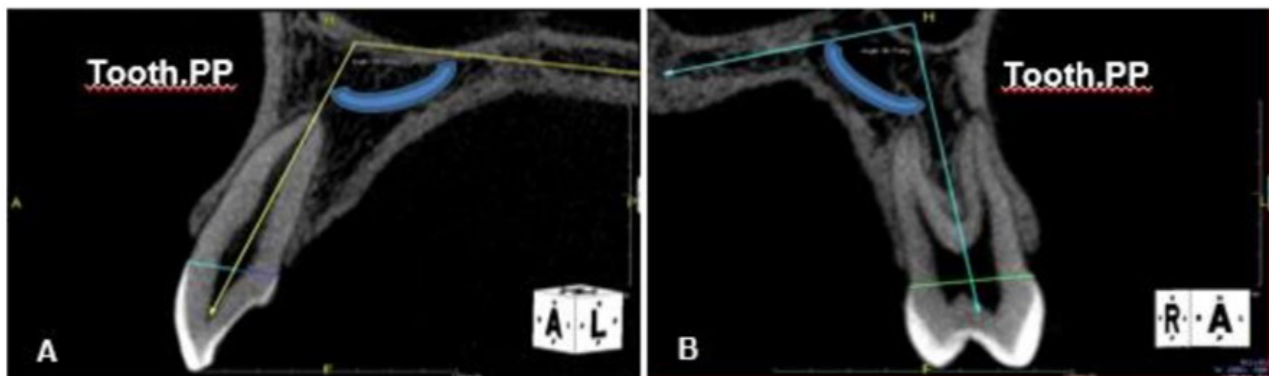
The root length was obtained and divided into three equal thirds as follows: cervical (C), middle (M) and apical (A) thirds. The amount of bone tissue in the cervical third was measured in parallel to the CEJ line, that is, at 3.0 mm from the CEJ. The amount of bone tissue in the middle and apical thirds was measured at the half of the third. The periodontal ligament space was not

considered. The following abbreviations were used: CBT for cervical buccal thickness, MBT for middle buccal thickness, ABT for apical buccal thickness, CPT for cervical palatal thickness, MPT for middle palatal thickness, and APT for apical palatal thickness. To determine the height of alveolar bone crest, the CEJ was measured in the buccal (from the buccal alveolar crest - BAC) and palatal faces (from the palatal alveolar crest - PAC) in parallel to the long axis of the root (Figure 2A-2B).

Measurement of the angle Tooth.PP, which is the long axis of the root in relation to the palatal plane, was obtained for all teeth by tracing a longitudinal line through the region of the furca. The distance PP was obtained by drawing a line between palatal cortical bone and nasal cortical bone on an equidistant basis (Figure 3A-3B).



**Figure 2** - Measurement of the bone plates in anterior (A) and posterior (B) teeth. Abbreviations: CBT (cervical buccal thickness), MBT (middle buccal thickness), ABT (apical buccal thickness), CPT (cervical palatal thickness), MPT (middle palatal thickness), APT (apical palatal thickness), BAC (buccal alveolar crest), and PAC (palatal alveolar crest).



**Figure 3** - Tooth.PP angle for anterior (A) and posterior (B) teeth.

## Statistical analysis

After 30 days, thirty per cent of the tomographic images were randomly selected for calculation of intra-rater (L.D.L.) and inter-rater (L.D.L and S.N.) errors. Bland-Altman method and paired t-test were used ( $P < 0.05$ ).

Statistical analyses were performed by using the BioStat software for Windows (version 5.8.3.0, AnalystSoft Inc.). Means and standard deviations (SD) were calculated for all measurements, in which paired t-test was used to determine the differences in the thickness of buccal and palatal bone plates between sides and between genders. ANOVA test was used for comparisons between variables analysed, whereas Tukey's test was used for *post-hoc* comparisons. Spearman's correlation was used for comparison of the bone thickness with angle Tooth.PP and age. Models of multiple linear regressions were used to assess the joint action of factors on the variable's responses. All statistical tests were performed a significant level of 0.05 ( $P < 0.05$ ).

## RESULTS

There was a high degree of concordance in the intra- and inter-rater assessments (0.95), which evidences the high reliability of the method, and no proportion bias was identified by using the Bland-Altman method. The mean of differences between the measurements replicated were 0.0053 (-0.4035 to 0.4140) and 0.0052 (-0.2652 to 0.2755) (Table 1) regarding intra-rater and inter-rater errors, respectively.

The present study assessed the difference in the measurements (CBT, MBT, ABT, CPT, MPT, APT, BAC, PAC, Tooth.PP) between the right and left sides by using paired t-test. The measurements between sides had no significant differences, except CBT for central incisors ( $P = 0.007$ ) and Tooth.PP for canines ( $P = 0.035$ ). Therefore, we decided to obtain the mean of the measurements between sides for pairs of teeth (11/21, 12/22, 13/23, 14/24 and 15/25). Table 2 shows the means and standard deviations of the values

**Table 1** - Intra-rater error for paired t-tests and Inter-rater error for paired t-tests, respectively ( $P < 0.05$ )

Measurements (mm)	First measurement	Second measurement	P-value
	Mean $\pm$ SD**	Mean $\pm$ SD	
ABT	1.3 $\pm$ 0.8	1.3 $\pm$ 0.8	1.000
MBT	1.0 $\pm$ 0.8	1.0 $\pm$ 0.7	0.343
CBT	0.8 $\pm$ 0.7	0.8 $\pm$ 0.6	0.092
APT	5.8 $\pm$ 3.3	5.9 $\pm$ 3.2	0.703
MPT	2.5 $\pm$ 1.1	2.5 $\pm$ 1.1	0.252
CPT	0.8 $\pm$ 0.4	0.8 $\pm$ 0.4	0.815
BAC	1.6 $\pm$ 0.8	1.6 $\pm$ 0.8	0.832
PAC	2.2 $\pm$ 0.8	2.1 $\pm$ 0.7	0.109
Tooth.PP	100.6 $\pm$ 11.9	100.4 $\pm$ 12.0	0.348
	First measurement	Second measurement	
	(Examiner #1)	(Examiner #2)	
ABT	1.3 $\pm$ 0.9	1.3 $\pm$ 0.9	0.307
MBT	1.2 $\pm$ 0.9	1.2 $\pm$ 0.9	0.634
CBT	1.0 $\pm$ 0.7	1.0 $\pm$ 0.7	0.524
APT	6.0 $\pm$ 2.8	6.1 $\pm$ 2.8	0.270
MPT	2.9 $\pm$ 1.3	2.9 $\pm$ 1.3	0.121
CPT	1.0 $\pm$ 0.5	1.0 $\pm$ 0.5	0.367
BAC	1.4 $\pm$ 0.6	1.5 $\pm$ 0.5	0.334
PAC	1.0 $\pm$ 0.5	1.0 $\pm$ 0.5	0.751
Tooth.PP (°)	99.6 $\pm$ 11.5	99.7 $\pm$ 11.4	0.861

\*\*SD = standard deviation. Abbreviations: ABT = apical buccal thickness; MBT = middle buccal thickness; CBT = cervical buccal thickness; APT = apical palatal thickness; MPT = middle palatal thickness; CPT = cervical palatal thickness; BAC = buccal alveolar crest; PAC = palatal alveolar crest; Tooth PP = long axis of the root in relation to the palatal plane.

**Table 2** - Means  $\pm$  SD\*\* of the values of bone plate thickness for each variable studied by pair of teeth

Measurements (mm)	Pair of Teeth				
	11/21	12/22	13/23	14/24	15/25
ABT	1.1 $\pm$ 0.5	1.1 $\pm$ 0.7	1.1 $\pm$ 0.6	0.6 $\pm$ 0.4	1.9 $\pm$ 1.1
MBT	0.6 $\pm$ 0.3	0.6 $\pm$ 0.5	0.6 $\pm$ 0.4	0.9 $\pm$ 0.6	1.7 $\pm$ 1.0
CBT	0.6 $\pm$ 0.3	0.5 $\pm$ 0.3	0.6 $\pm$ 0.3	0.8 $\pm$ 0.5	1.6 $\pm$ 0.8
APT	5.6 $\pm$ 1.3	4.0 $\pm$ 1.0	8.0 $\pm$ 3.6	4.8 $\pm$ 2.1	6.0 $\pm$ 2.3
MPT	3.0 $\pm$ 1.1	2.3 $\pm$ 0.7	3.5 $\pm$ 0.9	2.1 $\pm$ 0.9	2.5 $\pm$ 1.2
CPT	1.3 $\pm$ 0.5	1.0 $\pm$ 0.4	0.7 $\pm$ 0.3	0.7 $\pm$ 0.3	1.0 $\pm$ 0.5
BAC	1.7 $\pm$ 0.6	1.8 $\pm$ 0.6	2.0 $\pm$ 1.0	2.0 $\pm$ 0.8	1.5 $\pm$ 0.6
PAC	1.0 $\pm$ 0.3	0.9 $\pm$ 0.4	1.4 $\pm$ 0.7	1.6 $\pm$ 0.5	1.5 $\pm$ 0.5
Tooth.PP (°)	112.3 $\pm$ 9.1	117.5 $\pm$ 7.9	107.4 $\pm$ 8.0	93.5 $\pm$ 9.4	93.5 $\pm$ 7.0

\*\*SD = standard deviation. Abbreviations: ABT = apical buccal thickness; MBT = middle buccal thickness; CBT = cervical buccal thickness; APT = apical palatal thickness; MPT = middle palatal thickness; CPT = cervical palatal thickness; BAC = buccal alveolar crest; PAC = palatal alveolar crest; Tooth PP = long axis of the root in relation to the palatal plane.

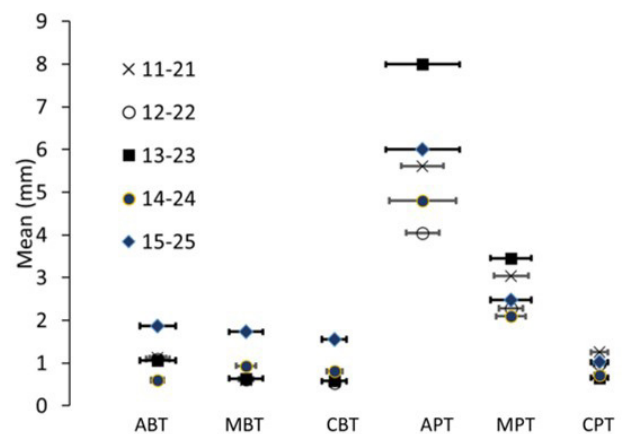
of bone plate thickness for each pair of teeth regarding all variables studied.

An ANOVA test was used for comparisons between the variables studied, whereas Tukey's test was used for *post-hoc* comparisons (Figure 4). In all pairs of teeth, the thickness of the palatal bone was found to be greater in the apical third than in the middle third. On the other hand, the thickness of the buccal bone was thinner in the cervical third of incisors and canines as well as in the apical third of first premolars. The thickness of the palatal bone was also thinner in the cervical third of second premolars.

The distance from CEJ to the buccal alveolar crest (BAC) is longer than to the palatal alveolar crest (PAC) in all pairs of teeth, being statistically significant.

Regarding sexual dimorphism, the variables APT, MPT and CPT were greater in males for the pair of teeth #11/21, whereas BAC was statistically significant greater in females. There was difference in the measurement MBT for the pair of teeth #12/22, which was greater in males. There was also difference in the measurement PAC for the pair of teeth #15/25, which was greater in females. The other pairs of teeth (#13/23 and #14/24) showed no statistically significant differences between genders (Table 3).

Table 4 lists the percentage of the sample with bone plate thickness  $\leq$  1mm, between 1 and 2 mm, and  $\geq$  2 mm. In the buccal face, the majority of the bone plates had a thickness  $\leq$  1 mm, whereas those  $\geq$  2 mm were found in the



**Figure 4** - Comparisons between the variables studied. Abbreviations: CBT (cervical buccal thickness), MBT (middle buccal thickness), ABT (apical buccal thickness), CPT (cervical palatal thickness), MPT (middle palatal thickness), APT (apical palatal thickness).

pair of teeth #15/25 for variables CBT (33%), MBT (37%) and ABT (43%); in the pair of teeth #14/24 for MBT (7%), and in the pairs of teeth #11/21 (3%), #12/22 (17%), #13/23 (10%) for ABT only. On the other hand, in the palatal face, the bone thickness was found to be increased in the cervico-apical direction.

The percentage of bone thickness  $\leq$  1 mm in the cervico-palatal region was higher compared to that of thicknesses of 1-2 mm and  $\geq$  2 mm in all teeth evaluated (50% to 83%), except for central incisors (40%). In the mid-palatal region, the percentage of bone thickness  $\geq$  2 mm was higher in all pairs of teeth (50% to 93%) compared to that of thicknesses  $\leq$  1 mm (0% to 7%) and between 1 mm and 2 mm (7% to

**Table 3** - Mean  $\pm$  SD\*\* of the thickness of the bone plates by pairs of teeth for females and males

Pair of teeth	Measurements (mm)	Female	Male	P-value (t-test)
11/21	ABT	1.2 $\pm$ 0.5	0.8 $\pm$ 0.6	0.071
	MBT	0.6 $\pm$ 0.2	0.6 $\pm$ 0.3	0.956
	CBT	0.5 $\pm$ 0.3	0.7 $\pm$ 0.2	0.071
	APT	5.1 $\pm$ 1.0	6.9 $\pm$ 1.1	0.000
	MPT	2.7 $\pm$ 0.8	4.0 $\pm$ 1.2	0.001
	CPT	1.1 $\pm$ 0.4	1.7 $\pm$ 0.5	0.007
	BAC	1.8 $\pm$ 0.6	1.6 $\pm$ 0.6	0.447
	PAC	1.1 $\pm$ 0.3	0.8 $\pm$ 0.3	0.028
	Tooth.PP (°)	113.9 $\pm$ 9.5	107.9 $\pm$ 6.4	0.113
12/22	ABT	1.0 $\pm$ 0.7	1.2 $\pm$ 0.8	0.564
	MBT	0.5 $\pm$ 0.3	1.1 $\pm$ 0.6	0.000
	CBT	0.5 $\pm$ 0.2	0.6 $\pm$ 0.4	0.573
	APT	3.9 $\pm$ 0.9	4.4 $\pm$ 1.2	0.222
	MPT	2.2 $\pm$ 0.6	2.6 $\pm$ 1.0	0.213
	CPT	1.0 $\pm$ 0.3	1.0 $\pm$ 0.5	0.885
	BAC	1.7 $\pm$ 0.5	2.1 $\pm$ 0.9	0.208
	PAC	0.9 $\pm$ 0.4	0.9 $\pm$ 0.5	0.637
	Tooth.PP (°)	118.9 $\pm$ 8.3	113.9 $\pm$ 5.6	0.125
13/23	ABT	1.0 $\pm$ 0.5	1.2 $\pm$ 0.9	0.631
	MBT	0.7 $\pm$ 0.4	0.6 $\pm$ 0.4	0.722
	CBT	0.6 $\pm$ 0.4	0.6 $\pm$ 0.1	0.851
	APT	7.7 $\pm$ 3.3	8.9 $\pm$ 4.2	0.411
	MPT	3.3 $\pm$ 0.9	3.8 $\pm$ 0.8	0.263
	CPT	0.6 $\pm$ 0.4	0.7 $\pm$ 0.2	0.471
	BAC	2.0 $\pm$ 1.1	1.8 $\pm$ 0.5	0.559
	PAC	1.4 $\pm$ 0.7	1.2 $\pm$ 0.8	0.347
	Tooth.PP (°)	106.9 $\pm$ 8.8	108.8 $\pm$ 5.2	0.566
14/24	ABT	0.6 $\pm$ 0.4	0.7 $\pm$ 0.4	0.408
	MBT	0.9 $\pm$ 0.6	1.1 $\pm$ 0.5	0.469
	CBT	0.8 $\pm$ 0.4	0.9 $\pm$ 0.7	0.507
	APT	4.4 $\pm$ 1.9	5.8 $\pm$ 2.4	0.112
	MPT	2.0 $\pm$ 1.0	2.2 $\pm$ 0.8	0.678
	CPT	0.7 $\pm$ 0.3	0.8 $\pm$ 0.3	0.529
	BAC	2.0 $\pm$ 0.6	2.1 $\pm$ 1.1	0.821
	PAC	1.7 $\pm$ 0.5	1.3 $\pm$ 0.7	0.150
	Tooth.PP (°)	93.8 $\pm$ 10.4	92.8 $\pm$ 6.2	0.788
15/25	ABT	1.7 $\pm$ 1.0	2.2 $\pm$ 1.3	0.293
	MBT	1.6 $\pm$ 1.0	2.0 $\pm$ 1.1	0.432
	CBT	1.5 $\pm$ 0.7	1.6 $\pm$ 0.9	0.921
	APT	6.0 $\pm$ 2.0	5.9 $\pm$ 3.1	0.892
	MPT	2.5 $\pm$ 1.3	2.3 $\pm$ 1.0	0.654
	CPT	1.0 $\pm$ 0.6	1.0 $\pm$ 0.3	0.702
	BAC	1.5 $\pm$ 0.6	1.6 $\pm$ 0.8	0.606
	PAC	1.6 $\pm$ 0.5	1.2 $\pm$ 0.2	0.032
	Tooth.PP (°)	92.7 $\pm$ 6.3	95.6 $\pm$ 8.7	0.326

\*\*SD = standard deviation. Abbreviations: ABT = apical buccal thickness; MBT = middle buccal thickness; CBT = cervical buccal thickness; APT = apical palatal thickness; MPT = middle palatal thickness; CPT = cervical palatal thickness; BAC = buccal alveolar crest; PAC = palatal alveolar crest; Tooth PP = long axis of the root in relation to the palatal plane.

**Table 4** - Percentage of the sample with bone plate thickness  $\leq 1$ mm, between 1 and 2 mm, and  $\geq 2$  mm

	Category (mm)	11/21	12/22	13/23	14/24	15/25
CBT	$\leq 1$	28 (93%)	29 (97%)	27 (90%)	19 (63%)	9 (30%)
	1 and 2	2 (7%)	1 (3%)	3 (10%)	11 (37%)	11 (37%)
	$\geq 2$	0 (0%)	0 (0%)	0 (0%)	0 (0%)	10 (33%)
MBT	$\leq 1$	27 (90%)	25 (83%)	24 (80%)	20 (67%)	9 (30%)
	1 and 2	3 (10%)	5 (17%)	6 (20%)	8 (27%)	10 (33%)
	$\geq 2$	0 (0%)	0 (0%)	0 (0%)	2 (7%)	11 (37%)
ABT	$\leq 1$	14 (47%)	17 (57%)	17 (57%)	25 (83%)	8 (27%)
	1 and 2	15 (50%)	8 (27%)	10 (33%)	5 (17%)	9 (30%)
	$\geq 2$	1 (3%)	5 (17%)	3 (10%)	0 (0%)	13 (43%)
CPT	$\leq 1$	12 (40%)	17 (57%)	25 (83%)	24 (80%)	15 (50%)
	1 and 2	15 (50%)	13 (43%)	5 (17%)	6 (20%)	13 (43%)
	$\geq 2$	3 (10%)	0 (0%)	0 (0%)	0 (0%)	2 (7%)
MPT	$\leq 1$	0 (0%)	0 (0%)	0 (0%)	2 (7%)	1 (3%)
	1 and 2	5 (17%)	11 (37%)	2 (7%)	13 (43%)	14 (47%)
	$\geq 2$	25 (83%)	19 (63%)	28 (93%)	15 (50%)	15 (50%)
APT	$\leq 1$	0 (0%)	0 (0%)	0 (0%)	0 (0%)	0 (0%)
	1 and 2	0 (0%)	0 (0%)	0 (0%)	3 (10%)	0 (0%)
	$\geq 2$	30 (100%)	30 (100%)	30 (100%)	27 (90%)	30 (100%)

Abbreviations: ABT = apical buccal thickness; MBT = middle buccal thickness; CBT = cervical buccal thickness; APT = apical palatal thickness; MPT = middle palatal thickness; CPT = cervical palatal thickness; PAC = palatal alveolar crest; Tooth PP = long axis of the root in relation to the palatal plane; mm = millimeter.

47%). In the apical region of the palatal face, the thickness  $\geq 2$  mm was predominantly found in all pairs of teeth (100%), except for the pair of teeth #14/24 (90%), in which 10% had thickness between 1 mm and 2 mm.

Table 5 lists Spearman's correlation values between bone thicknesses and angle Tooth.PP, with significant results as follows: in the pair of teeth #11/21, a positive correlation was found for the variable MBT only; in the pair of teeth #12/22, negative correlations were found for variables CBT, APT and MPT as well as in the pair of teeth #13/23 for variable APT only; in the pair of teeth #14/24, a negative correlation was found for variables ABT and MBT. Additionally, multiple linear regression analysis was used to assess the joint action of factors on the variables responses, in which significant results were positive in teeth #15/25 for the variable BAC, negative in teeth #11/21 and #13/23 for the variable APT, and negative in teeth #12/22 for the variance MPT.

Table 6 lists Spearman's correlation between bone thicknesses and age. In the pair of teeth #11/21, the correlation was positive for the variable BAC and negative for the variable CBT;

in the pair of teeth #12/22, the correlation was positive for the variable PAC and negative for the variables ABT and CPT; in the pair of teeth #13/23, the correlation was positive for Tooth.PP, CPT, BAC and PAC and negative for the variables ABT, MPT, APT MPT and CBT. In order to assess the joint action of factors on the variables responses, models of multiple linear regression were used and the following results were found: in the pairs of teeth #11/21, #14/24 and #15/25, the variable CBT was negative, whereas in the pair of teeth #13/23 it was positive; in the pair of teeth #12/22, the variable MBT was negative; in the pair of teeth #14/24, the variable APT was negative; in the pair of teeth #13/23, the variable MBT was negative; in the pair of teeth #15/25, the variable BAC was positive; and in the pair of teeth #12/22, the variable PAC was positive.

In the linear regression analysis of each bone variable in function of the angle Tooth.PP, neither age nor gender had statistical significance, except for the variable CBT in the pair of teeth #11/12 regarding gender.



**Table 5** - Spearman's correlation values between angle Tooth.PP and measurements of the bone plate thickness

	Measurements (mm)	11/21	P-value	12/22	P-value	13/23	P-value	14/24	P-value	15/25	P-value
Spearman	ABT	0.29	0.12	0.08	0.69	0.11	0.57	-0.48	0.01	-0.25	0.19
	MBT	0.36	0.05	-0.19	0.33	0.08	0.67	-0.42	0.02	-0.31	0.10
	CBT	-0.24	0.19	-0.39	0.03	-0.02	0.94	-0.26	0.16	-0.34	0.06
	APT	-0.33	0.08	-0.56	0.00	-0.36	0.05	-0.04	0.84	-0.26	0.17
	MPT	-0.14	0.46	-0.53	0.00	-0.25	0.18	-0.17	0.38	-0.13	0.50
	CPT	-0.19	0.32	-0.25	0.18	-0.24	0.20	-0.11	0.57	-0.06	0.75
	BAC	-0.08	0.66	0.12	0.51	0.21	0.27	0.14	0.46	0.44	0.01
	PAC	0.20	0.30	0.37	0.04	0.01	0.94	0.32	0.09	-0.21	0.20

Abbreviations: ABT = apical buccal thickness; MBT = middle buccal thickness; CBT = cervical buccal thickness; APT = apical palatal thickness; MPT = middle palatal thickness; CPT = cervical palatal thickness; BAC = buccal alveolar crest; PAC = palatal alveolar crest; Tooth PP = long axis of the root in relation to the palatal plane.

**Table 6** - Spearman's correlation values between age and bone plate thickness

	Measurements (mm)	11/21	P-value	12/22	P-value	13/23	P-value	14/24	P-value	15/25	P-value
Spearman's correlation	PP	0.28	0,13	0.21	0.26	0.41	0.02	0.42	0.02	0.35	0.06
	ABT	-0.15	0.41	-0.39	0.03	-0.07	0.73	-0.52	0.00	-0.20	0.28
	MBT	0.04	0.84	-0.34	0.06	0.16	0.41	-0.40	0.03	-0.25	0.17
	CBT	-0.39	0.03	-0.33	0.07	0.28	0.12	-0.36	0.05	-0.42	0.02
	APT	-0.31	0.09	-0.18	0.33	-0.43	0.01	-0.45	0.01	-0.21	0.25
	MPT	-0.15	0.41	-0.26	0.17	-0.42	0.02	-0.44	0.01	0.17	0.35
	CPT	-0.25	0.18	-0.42	0.02	-0.27	0.14	0.11	0.55	0.03	0.87
	BAC	0.28	0.12	0.40	0.02	0.22	0.24	0.47	0.00	0.51	0.00
	PAC	0.37	0.04	0.45	0.01	0.25	0.18	0.09	0.65	0.24	0.20

Abbreviations: ABT = apical buccal thickness; MBT = middle buccal thickness; CBT = cervical buccal thickness; APT = apical palatal thickness; MPT = middle palatal thickness; CPT = cervical palatal thickness; BAC = buccal alveolar crest; PAC = palatal alveolar crest; PP = palatal plane.

## DISCUSSION

In the present study, the normality standards for bone plate thickness based on simple methodology, which has easy clinical reproducibility, were established by using CBCT images of patients with balanced occlusion and harmonious facial profile. Knowing the biases of these bone normalities contributes to a better planning and execution of orthodontic treatment as the periodontal characteristics of the supportive tissue are preserved, or even improved, which favours the results in the medium and long terms [2,3,14,17]. On the other hand, if the practitioner is unaware of the patient's biological limits, or even exceeds them, iatrogenic side effects such as dehiscences and fenestrations may occur, and depending on the

patient's gingival phenotype, gingival recessions may also develop [5,11,27,28].

Based on the literature investigated, data on bone plate thickness around natural teeth [5,14,17,19,20,22,25,26,29-33] and distance from CEJ to ABC in computed tomographs are highly accurate and reliable [18,21,22,34,35], which urged us to investigate the standards of bone normality in a higher number of teeth measured on CBCT images acquired with voxel size of 0.1 mm, thus differing from previous studies. CBCT uses isotropic voxels which are equal in width, thickness and height, with size usually ranging from 0.1 mm to 0.4 mm [17,32,34]. These images allow 1:1 linear measurements to be accurately made in any plane. To facilitate the image recovery, the set of data should be stored according to legal norms

and should be exportable in formats (e.g., DICOM – Digital Imaging Communication in Medicine) compatible with digital files as recommended by the International Standards Organization (ISO) [18,36].

A common limitation of the previous studies in comparison to the present one is concerned with the CBCT image resolution for assessment of the bone thicknesses, since they had a greater voxel size [19,20,22,24-26,34,37] or no voxel specification [14,30,32]. The alveolar bone plates, mainly the buccal ones, are thin and may not be visible if the spatial resolution of the images is not adequate [21,23]. Previous studies evaluated the alveolar bone levels by using a voxel size ranging from 0.25 mm to 0.3 mm [19,20,22,24-26], but among the results found in our work, it was possible to observe bone thicknesses lower than 1 mm, which would be underestimated with image resolutions higher than 0.1 mm. Our measurements were made on ultra-resolution images (i.e. voxel size of 0.1 mm), thus ensuring greater reliability of the results obtained and consequently providing new reference values for bone plate thicknesses in individuals with static occlusion and facial pattern considered to be ideal.

The results obtained from the current study showed that there was no difference between the left and right sides for all measurements studied (i.e. CBT, MBT, ABT, CPT, MPT, APT, BAC, PAC and Tooth.PP), except between teeth #11 and #21 for the variable CPT as well as between teeth #13 and #23 for the variable Tooth.PP ( $P = 0.035$ ), which allowed mean values of the measurements to be obtained in relation to the sides by pairs of teeth #11/21, #12/22, #13/23, #14/24 and #15/25. AlTarawneh et al. (2018) [32] found no statistical difference in homologous teeth at different sites of measurement, thus corroborating our results.

The comparison between cervical, middle and apical thirds regarding bone thickness, both buccally and palatally, showed a progressive increase in the cervico-apical direction, that is, the greater the distance from the alveolar crest, the higher the values observed. These results are in accordance with the literature [5,26,29]. Only the pair of teeth #14/24 had a greater amount of tissue in the middle third compared to the apical third in the buccal face. Overall, palatal bone thicknesses were statistically

significant greater than the buccal ones in the three thirds evaluated, excepted for the pair of teeth #15/25 as the variable CPT was smaller than CBT. In the literature, corroborating our results, the palatal cortical bone is thicker and denser than the buccal one [22,29,32]. According to Nahás-Scocate, Scocate (2014) [13], all teeth evaluated in the present study were classified as B1L1 despite showing thinner bone thickness in the cervical region of the buccal face.

Analysis of the mean values of the bone thicknesses showed that the majority of the thirds had thinner ones in both buccal and palatal faces, which draws our attention to possible negative clinical repercussions. Orthodontic correction is achieved by means of tooth movement induced by mild forces and adequate biomechanics. Movements towards thin bone plates or cases in which bone dehiscences can be a factor limiting the treatment require the practitioner to know in advance the bone condition of the patient. In order to provide relevant and accurate information for the practitioners, we quantified the thicknesses of the bone plates and calculated the percentages based on tissue references reported in the literature, namely:  $\leq 1$  mm, between 1 and 2 mm, and  $\geq 2$  mm [5,22,29,38].

Evaluation of the buccal bone plates of anterior teeth showed values  $\leq 1$  mm for cervical (above 90%), middle (above 80%) and apical (above 75%) thirds, except for the pair of teeth #11/21, whose values between 1 mm and 2 mm (50%) were higher in the apical third. These teeth were also the only ones with bone tissue above 2 mm (3% to 17%) in the apical third. Overall, the buccal bone plates of anterior teeth are thinner [22,32], which is of concern regarding the orthodontic tooth movement towards the buccal face in the anterior region of the upper arches. With regard to non-biological forces, in association with the presence of dental biofilm and fine gingival phenotype, the development of gingival recession may occur [3,6,9,14-19,39]. That is the reason why orthodontic appliances apply mild, constant and predictable forces, which meets the philosophy of biomechanics for orthodontic aligners despite the need of further scientific grounds in the present days [9,40,41]. Preservation of the alveolar bone tissue in the orthodontic treatment should be a premise for planning a successful treatment, both aesthetically and functionally, and longevity of periodontal structures [1,3,7,28,42].

Evaluation of the buccal cortical bone of the first premolars showed that the majority of the three thirds had values  $\leq 1$  mm (above 63%). Considering the buccal face of second premolars, the middle and apical thirds showed values  $\geq 2$  mm in the majority of the cases (37% and 43%, respectively), whereas the cervical third has a predominance of bone thickness between 1 mm and 2 mm (37%). These results draw attention to the reduction in the buccal bone architecture around the first premolars, thus being a facilitator in the development of gingival recessions in this region [3,4]. In addition, these data warn about the biomechanical care during the dentoalveolar expansion of atresic arches with buccal inclinations of teeth. On the other hand, palatinized premolars with less bone thickness in the buccal face can have an improved bone architecture, provided that they are well positioned in the alveolus and there is no periodontal inflammation [3].

In the palatal face of anterior teeth, the bone thickness  $\leq 1$  mm was more prevalent (above 57%) in the cervical third, followed by bone thickness between 1 mm and 2 mm, which was more prevalent in central incisors (50%). However, middle and apical thirds had predominantly a bone thicknesses  $\geq 2$  mm (above 63%). It is worth highlighting that the bone thickness above 2 mm in the apical third was observed in 100% of the cases for all teeth evaluated. With regard to palatal bone thickness of posterior teeth (i.e. first and second premolars), bone thicknesses  $\leq 1$  mm were predominant in the cervical third (50-80%). In the middle third, there was a predominance of bone thicknesses  $\geq 2$  mm in 50% of the teeth evaluated, whereas this predominance ranged from 90% to 100% in the apical third. Overall, it was observed that the bone tissue in the palatal face of upper teeth had a similar behaviour, that is, there is a greater amount of bone tissue in the middle and apical thirds. Thus, application of root lingual torque is well indicated for both anterior and posterior regions of the arch instead of buccal movements of the crown. These data should be considered in the diagnosis and orthodontic planning in order to prevent the occurrence of periodontal problems in the future [5,14,17,19,29,43].

The comparison of all sites of measurements between males and females showed that there were no uniform results, differently from some studies in the literature in which other authors

support the presence of a greater bone thickness among men [26,32]. On the other hand, other studies highlight that there is no significant difference between men and women [5,29,44]. However, some authors found differences in bone thickness between genders depending on the tooth being evaluated, which corroborates our study. For instance, in the pair of teeth #11/21, males had significantly greater bone thicknesses in the palatal face regarding the three thirds, as well as in the pair of teeth #12/22 regarding the variable MBT. No statistically significant differences were found between genders in canines and first premolars regarding the variable PAC, with females having significantly higher values in central incisors and second premolars. In view of the variability in the amount of bone thickness around upper teeth between men and women, it is indispensable to perform individual evaluation in the pre-treatment phase.

The literature has shown the influence of age on the amount of bone tissue around anterior upper teeth, thus evidencing a tendency of reduction of bone thickness over time [14,38,45]. In our study, age is a factor correlated with the tissue variables, being negative with CBT in central incisors; ABT and CPT in lateral incisors; APT and MPT in canines; ABT, MBT, APT and MPT in first premolars; and CBT in second premolars. Therefore, older individuals have thinner bone thickness in these sites. The distance from alveolar bone crest to cement-enamel junction in the palatal face of lateral incisors was the only measurement being positively correlated with age, which is corroborated by AlTarawneh et al. (2018) [32]. A study by Üner et al. (2019) [26] was similar to ours regarding the lack of correlation between age and the variable BAC in central incisors.

The correlations found between tooth inclination and bone plate thickness, which were confirmed by using the multiple linear regression test, pointed to the evidence of a significantly positive result between variable BAC and tooth inclination in second premolars. This reinforces the concerns the orthodontists should have when the crown of these teeth is to be moved buccally, which might clinically impair the periodontal condition if biomechanical forces are inadequately applied [5,12,43]. Moreover, these results evidence the importance of the torque expression when the orthodontist uses conventional fixed appliances, including the self-ligating system,

or orthodontic aligners [16]. The search for aesthetic aligners is increasing today, both among patients and among practitioners. However, the torque expression is still a challenge in the use of these appliances [15,46,47] and should also be considered as a part of the digital planning. The Invisalign® system introduced the use of power ridges, which are pressure lines close to the gingival margin for increasing the contact pressure on the tooth surface, to control the movement of the tooth around its centre of resistance [16,48]. For the upper central and lateral incisors and canines, the results between dental inclination and palatal bone thickness were significantly negative in the middle and apical thirds, which reflects a reduction of bone tissue in these areas when inclination increases, and vice-versa. However, as these areas have a greater amount of bone tissue, it is assumed that there is lower periodontal risk when root movements occur palatally.

In the present study, care was taken in the preparation of the sample regarding the characteristics of the patient, such as craniofacial growth and ethnics, differently from other studies [29]. Moreover, a total of 150 teeth were evaluated in the present study, all belonging to patients with normal occlusion and harmonious facial profile. Voxel size of 0.1 mm and high image resolution are scientifically relevant aspects of this novel study on imaging diagnosis of alveolar bone plates, in addition to providing clinical guidelines to know reference standards for bone plates in conditions of normality, which makes planning more accurate and treatment safer. It is recommended that further studies should include a larger number of participants in the samples, with equivalence between males and females, to consolidate the results found.

## CONCLUSIONS

- 1) Thin bone thicknesses were observed in most of the root thirds assessed, both in buccal and palatal faces, which draws attention to possible negative repercussions when bone plate measurements are not considered in the orthodontic treatment. Therefore, it is suggested that orthodontic appliances should exert mild, constant, and predictable forces.
- 2) A reduced buccal bone architecture around the first premolars can facilitate the development of gingival recession in this

region, which demands biomechanical care during arch expansion with the buccal inclination of the teeth. On the other hand, palatinized premolars with thinner bone thickness in the buccal face, when well positioned in the alveolus and in the absence of periodontal inflammation, can have their bone architecture improved.

- 3) In the palatal face of the upper teeth, there is a greater amount of bone in the middle and apical thirds. Thus, the application of lingual root torque is well indicated in both anterior and posterior regions of the arch instead of buccal movements of the crown.
- 4) By comparing all the measurements between males and females, there was no homogeneity in the results found. Therefore, it is essential to evaluate patients individually during the pre-treatment phase.

## Acknowledgements

The authors are grateful to the participants in this study.

## Author's Contributions

ACRNS: Conceptualization. SN: Methodology. MM: Formal Analysis. SN, MM, MELX: Investigation. MELX: Resources. ACRNS, LDL, MELX: Data Curation. ACRNS, MM, IC, JAS: Supervision. SN, LDL: Writing – Original Draft Preparation. ACRNS, LDL, MM, IC, JAS: Writing – Review & Editing. IC, JAS: Visualization.

## Conflict of Interest

No conflicts of interest declared concerning the publication of this article.

## Funding

The authors declare that no financial support was received.

## Regulatory Statement

This study was conducted in accordance with all the provisions of the local human subjects oversight committee guidelines and policies of: the Guarulhos University (UNG). The approval code for this study is: 89786318.8.0000.5506.

## REFERENCES

- Evangelista K, Vasconcelos KDF, Bumann A, Hirsch E, Nitka M, Silva MAG. Dehiscence and fenestration in patients with class I and class II division 1 malocclusion assessed with cone-beam computed tomography. *Am J Orthod Dentofacial Orthop.* 2010;138(2):133.E1-7. <http://dx.doi.org/10.1016/j.ajodo.2010.03.018>. PMID:20691344.
- Renkema AM, Fudalej PS, Renkema AAP, Abbas F, Bronkhorst E, Katsaros C. Gingival labial recessions in orthodontically treated and untreated individuals: a case - control study. *J Clin Periodontol.* 2013;40(6):631-7. <http://dx.doi.org/10.1111/jcpe.12105>. PMID:23587032.
- Antoun JS, Mei L, Gibbs K, Farella M. Effect of orthodontic treatment on the periodontal tissues. *Periodontol 2000.* 2017;74(1):140-57. <http://dx.doi.org/10.1111/prd.12194>. PMID:28429487.
- Mandelaris GA, Neiva R, Chambrone L. Cone-beam computed tomography and interdisciplinary dentofacial therapy: an American Academy of Periodontology best evidence review focusing on risk assessment of the dentoalveolar bone changes influenced by tooth movement. *J Periodontol.* 2017;88(10):960-77. <http://dx.doi.org/10.1902/jop.2017.160781>. PMID:28967331.
- Sendyk M, Paiva JB, Abrão J, Rino J No. Correlation between buccolingual tooth inclination and alveolar bone thickness in subjects with Class III dentofacial deformities. *Am J Orthod Dentofacial Orthop.* 2017;152(1):66-79. <http://dx.doi.org/10.1016/j.ajodo.2016.12.014>. PMID:28651770.
- Wang CW, Yu SH, Mandelaris GA, Wang HL. Is periodontal phenotype modification therapy beneficial for patients receiving orthodontic treatment? An American Academy of Periodontology best evidence review. *J Periodontol.* 2020;91(3):299-310. <http://dx.doi.org/10.1002/JPER.19-0037>. PMID:31670836.
- Machado AW, MacGinnis M, Damis L, Moon W. Spontaneous improvement of gingival recession after correction of tooth positioning. *Am J Orthod Dentofacial Orthop.* 2014;145(6):828-35. <http://dx.doi.org/10.1016/j.ajodo.2013.05.012>. PMID:24880854.
- Castro LO, Castro IO, Alencar AHG, Valladares-Neto J, Estrela C. Cone beam computed tomography evaluation of distance from cemento-enamel junction to alveolar crest before and after nonextraction orthodontic treatment. *Angle Orthod.* 2016;86(4):543-9. <http://dx.doi.org/10.2319/040815-235.1>. PMID:26379114.
- Sendyk M, Linhares DS, Pannuti CM, Paiva JB, Rino J No. Effect of orthodontic treatment on alveolar bone thickness in adults: a systematic review. *Dental Press J Orthod.* 2019;24(4):34-45. <http://dx.doi.org/10.1590/2177-6709.24.4.034-045.oar>. PMID:31508705.
- Yeung AWK, Jacobs R, Bornstein MM. Novel low-dose protocols using cone beam computed tomography in dental medicine: a review focusing on indications, limitations, and future possibilities. *Clin Oral Investig.* 2019;23(6):2573-81. <http://dx.doi.org/10.1007/s00784-019-02907-y>. PMID:31025192.
- Bahar BSKB, Alkhalidy SR, Kaklamanos EG, Athanasiou AE. Do orthodontic patients develop more gingival recession in anterior teeth compared to untreated individuals? A systematic review of controlled studies. *Int Orthod.* 2020;18(1):1-9. <http://dx.doi.org/10.1016/j.ortho.2019.08.025>. PMID:31685434.
- Son EJ, Kim SJ, Hong C, Chan V, Sim HY, Ji S, et al. A study on the morphologic change of palatal alveolar bone shape after intrusion and retraction of maxillary incisors. *Sci Rep.* 2020;10(1):14454. <http://dx.doi.org/10.1038/s41598-020-71115-6>. PMID:32879338.
- Nahás-Scocate ACR, Scocate MC. A classification of alveolar bone tissue. *Quintessence Int.* 2014;45(6):515-9. PMID:24618573.
- Wang XM, Ma LZ, Wang J, Xue H. The crown-root morphology of central incisors in different skeletal malocclusions assessed with cone-beam computed tomography. *Prog Orthod.* 2019;20(1):20. <http://dx.doi.org/10.1186/s40510-019-0272-2>. PMID:3111270.
- Zheng M, Liu R, Ni Z, Yu Z. Efficiency, effectiveness and treatment stability of clear aligners: a systematic review and meta-analysis. *Orthod Craniofac Res.* 2017;20(3):127-33. <http://dx.doi.org/10.1111/ocr.12177>. PMID:28547915.
- Sfondrini MF, Gandini P, Castrolforio T, Garino F, Mergati L, D'Anca K, et al. Buccolingual inclination control of upper central incisors of aligners: a comparison with conventional and self-ligating brackets. *BioMed Res Int.* 2018;2018:9341821. <http://dx.doi.org/10.1155/2018/9341821>. PMID:30627583.
- Romero-Delmastro A, Kadioglu O, Currier GF, Cook T. Digital tooth-based superimposition method for assessment of alveolar bone levels on cone-beam computed tomography images. *Am J Orthod Dentofacial Orthop.* 2014;146(2):255-63. <http://dx.doi.org/10.1016/j.ajodo.2014.05.001>. PMID:25085309.
- American Academy of Oral and Maxillofacial Radiology. Clinical recommendations regarding use of cone beam computed tomography in orthodontics. Position statement by the American Academy of Oral and Maxillofacial Radiology. *Oral Surg Oral Med Oral Pathol Oral Radiol.* 2013;116(2):238-57. <http://dx.doi.org/10.1016/j.ooooo.2013.06.002>. PMID:23849378.
- Garlock DT, Buschang PH, Araujo EA, Behrents RG, Kim KB. Evaluation of marginal alveolar bone in the anterior mandible with pretreatment and posttreatment computed tomography in nonextraction patients. *Am J Orthod Dentofacial Orthop.* 2016;149(2):192-201. <http://dx.doi.org/10.1016/j.ajodo.2015.07.034>. PMID:26827975.
- Rinaldi MRL, Azeredo F, Lima EM, Rizzato SMD, Sameshima G, Menezes LM. Cone-beam computed tomography evaluation of bone plate and root length after maxillary expansion using tooth-borne and tooth-tissue-borne banded expanders. *Am J Orthod Dentofacial Orthop.* 2018;154(4):504-16. <http://dx.doi.org/10.1016/j.ajodo.2017.12.018>. PMID:30268261.
- Leonardi R. Cone-beam computed tomography and three-dimensional orthodontics. Where we are and future perspectives. *J Orthod.* 2019;46(Suppl 1):45-8. <http://dx.doi.org/10.1177/1465312519840029>. PMID:31056034.
- Behnia H, Motamedian S, Kiani M, Morad G, Khojasteh A. Accuracy and reliability of cone beam computed tomographic measurements of the bone labial and palatal to the maxillary anterior teeth. *Int J Oral Maxillofac Implants.* 2015;30(6):1249-55. <http://dx.doi.org/10.11607/jomi.3856>. PMID:26478968.
- Yatabe M, Natsumeda GM, Miranda F, Janson G, Garib D. Alveolar bone morphology of maxillary central incisors near grafted alveolar clefts after orthodontic treatment. *Am J Orthod Dentofacial Orthop.* 2017;152(4):501-8.E1. <http://dx.doi.org/10.1016/j.ajodo.2017.01.029>. PMID:28962735.
- Garib D, Massaro C, Yatabe M, Janson G, Lauris JRP. Mesial and distal alveolar bone morphology in maxillary canines moved into the grafted alveolar cleft: computed tomography evaluation. *Am J Orthod Dentofacial Orthop.* 2017;151(5):869-77. <http://dx.doi.org/10.1016/j.ajodo.2016.11.019>. PMID:28457264.
- Kula TJ III, Ghoneima A, Eckert G, Parks ET, Utreja A, Kula K. Two-dimensional vs 3-dimensional comparison of alveolar bone over maxillary incisors with A-point as a reference. *Am J Orthod Dentofacial Orthop.* 2017;152(6):836-47.E2. <http://dx.doi.org/10.1016/j.ajodo.2017.05.030>. PMID:29173863.
- Üner DD, İzol BS, Gorus Z. Correlation between buccal and alveolar bone widths at the central incisors according to cone-beam-computed tomography. *Niger J Clin Pract.* 2019;22(1):79-84. PMID:30666024.
- Nahás-Scocate ACR, Brandão AS, Patel MP, Lipiec-Ximenez ME, Chilvarquer I, Valle-Corotti KM. Bone tissue amount related to

- upper incisors inclination. *Angle Orthod.* 2014;84(2):279-85. <http://dx.doi.org/10.2319/031213-211.1>. PMID:23883305.
28. Chaimongkol P, Thongudomporn U, Lindauer SJ. Alveolar bone response to light-force tipping and bodily movement in maxillary incisor advancement: a prospective randomised clinical trial. *Angle Orthod.* 2018;88(1):58-66. <http://dx.doi.org/10.2319/070717-449.1>. PMID:29083225.
  29. Ohiomoba H, Sonis A, Yansane A, Friedland B. Quantitative evaluation of maxillary alveolar cortical bone thickness and density using computed tomography imaging. *Am J Orthod Dentofacial Orthop.* 2017;151(1):82-91. <http://dx.doi.org/10.1016/j.ajodo.2016.05.015>. PMID:28024789.
  30. Lombardo L, Berveglieri C, Spina R, Siciliani G. Quantitative cone-beam computed tomography evaluation of premaxilla and symphysis in Class I and Class III malocclusions. *Int Orthod.* 2016;14(2):143-60. <http://dx.doi.org/10.1016/j.ortho.2016.03.014>. PMID:27094737.
  31. Haddad R, Saadeh M. Distance to alveolar crestal bone: a critical factor in the success of orthodontic mini-implants. *Prog Orthod.* 2019;20(1):19. PMID:31081528.
  32. AlTarawneh S, AlHadidi A, Hamdan AAS, Shaqman M, Habib E. Assessment of bone dimensions in the anterior maxilla: a cone beam computed tomography study. *J Prosthodont.* 2018;27(4):321-8. <http://dx.doi.org/10.1111/jopr.12675>. PMID:29235201.
  33. Matsumura T, Ishida Y, Kawabe A, Ono T. Quantitative analysis of the relationship between maxillary incisors and the incisive canal by cone-beam computed tomography in an adult Japanese population. *Prog Orthod.* 2017;18(1):24. PMID:28762152.
  34. Güngör E, Doğan MS. Reliability and accuracy of cone-beam computed tomography voxel density and linear distance measurement at different voxel sizes: a study on sheep head cadaver. *J Dent Sci.* 2017;12(2):145-50. <http://dx.doi.org/10.1016/j.jds.2016.11.004>. PMID:30895040.
  35. Abdelkarim A. Cone-beam computed tomography in orthodontics. *Dent J.* 2019;7(3):89. <http://dx.doi.org/10.3390/dj7030089>. PMID:31480667.
  36. Carter L, Farman AG, Geist J, Scarfe WC, Angelopoulos C, Nair MK, et al. American Academy of Oral and Maxillofacial Radiology executive opinion statement on performing and interpreting diagnostic cone beam computed tomography. *Oral Surg Oral Med Oral Pathol Oral Radiol Endod.* 2008;106(4):561-2. <http://dx.doi.org/10.1016/j.tripleo.2008.07.007>. PMID:18928899.
  37. Baumgaertel S. Quantitative investigation of palatal bone depth and cortical bone thickness for mini-implant placement in adults. *Am J Orthod Dentofacial Orthop.* 2009;136(1):104-8. <http://dx.doi.org/10.1016/j.ajodo.2008.11.020>. PMID:19577156.
  38. Nowzari H, Molayem S, Chiu CHK, Rich SK. Cone beam computed tomographic measurement of maxillary central incisors to determine prevalence of facial alveolar bone width  $\geq 2$ mm. *Clin Implant Dent Relat Res.* 2012;14(4):595-602. <http://dx.doi.org/10.1111/j.1708-8208.2010.00287.x>. PMID:20491811.
  39. Haouili N, Kravitz ND, Vaid NR, Ferguson DJ, Makki L. Has Invisalign improved? A prospective follow-up study on the efficacy of tooth movement with Invisalign. *Am J Orthod Dentofacial Orthop.* 2020;158(3):420-5. <http://dx.doi.org/10.1016/j.ajodo.2019.12.015>. PMID:32620479.
  40. Lu H, Tang H, Zhou T, Kang N. Assessment of the periodontal health status in patients undergoing orthodontic treatment with fixed appliances and Invisalign system. *Medicine.* 2018;97(13):e0248. <http://dx.doi.org/10.1097/MD.00000000000010248>. PMID:29595680.
  41. Alajmi S, Shaban A, Al-Azemi R. Comparison of short-term oral impacts experienced by patients treated with Invisalign or conventional fixed orthodontic appliances. *Med Princ Pract.* 2020;29(4):382-8. <http://dx.doi.org/10.1159/000505459>. PMID:31842018.
  42. Barreda GJ, Dzierewianko EA, Mazza V, Muñoz KA, Piccoli GL, Romanelli HJ. Expansion treatment using Invisalign®: periodontal health status and maxillary buccal bone changes. A clinical and tomographic evaluation. *Acta Odontol Latinoam.* 2020;33(2):69-81. <http://dx.doi.org/10.54589/aol.33/2/069>. PMID:32920608.
  43. Guerra ED, Araujo FM Jr, Ferreira CF, Patel MP, Lipiec-Ximenez ME, Chilvarquer I, et al. Correlation between alveolar bone tissue amount and orthodontic movement of the maxillary incisors: a cone-beam computed tomography image assessment. *Int J Orthod.* 2018;29:71-8.
  44. Freitas MPM. Alveolar cortical bone. *Am J Orthod Dentofacial Orthop.* 2018;153(1):4. <http://dx.doi.org/10.1016/j.ajodo.2017.10.012>. PMID:29287647.
  45. Januário AL, Duarte WR, Barriviera M, Mesti JC, Araújo MG, Lindhe J. Dimension of the facial bone wall in the anterior maxilla: a cone-beam computed tomography study. *Clin Oral Implants Res.* 2011;22(10):1168-71. <http://dx.doi.org/10.1111/j.1600-0501.2010.02086.x>. PMID:21320168.
  46. Cheng Y, Gao J, Fang S, Wang W, Ma Y, Jin Z. Torque movement of the upper anterior teeth using a clear aligner in case of extraction: a finite element study. *Prog Orthod.* 2022;23(1):26. PMID:35909188.
  47. Liu L, Song Q, Zhou J, Kuang Q, Yan X, Zhang X, et al. The effects of aligner overtreatment on torque control and intrusion of incisors for anterior retraction with clear aligners: a finite-element study. *Am J Orthod Dentofacial Orthop.* 2022;162(1):33-41. <http://dx.doi.org/10.1016/j.ajodo.2021.02.020>. PMID:35219555.
  48. Figueiredo MA, Romano FL, Feres MFN, Stuani MBS, Nahás-Scocate ACR, Matsumoto MAN. Effectiveness of Invisalign® aligners in the treatment of severe gingival recession: a case report. *Korean J Orthod.* 2021;51(4):293-300. <http://dx.doi.org/10.4041/kjod.2021.51.4.293>. PMID:34275885.

**Murilo Matias****(Corresponding address)**

Universidade Guarulhos (UNG), Faculdade de Odontologia, Departamento de Ortodontia, Guarulhos, SP, Brazil.  
Email: mts78@hotmail.com

Date submitted: 2022 Aug 05

Accept submission: 2022 Oct 06