



## Cherubism in Saudi population: a rare case report

Querubismo na população Saudi: relato de um caso raro

Nezar BOREAK<sup>1</sup> , Bassam Ali HAMDI<sup>2</sup> , Nasser Ali KORERI<sup>2</sup> , Mazen Ahmed QADI<sup>2</sup> , Loay Ebrahim NAJMI<sup>2</sup> , Faisal Hadi KHORMI<sup>2</sup>

1 - Jazan University, Department of Restorative Dental Sciences. Jazan, Saudi Arabia.

2 - Jazan University, School of Dentistry. Jazan, Saudi Arabia.

**How to cite:** Boreak N, Hamdi BA, Koreri NA, Qadi MA, Najmi LE, Khormi FH. Cherubism in Saudi population: a rare case report. *Braz Dent Sci.* 2023;26(2):e3698. <https://doi.org/10.4322/bds.2023.e3698>

### ABSTRACT

Cherubism is a rare hereditary benign fibro-osseous disorder characterised by bilateral swelling of the mandible and/or maxilla with varying severity of involvement. It occurs because of dominant mutations in SH3BP2 gene on the chromosome 4p16.3. On radiography cherubic lesions appear as multilocular cystic radiolucencies in the jaw bones giving a soap bubble appearance. These lesions usually heal by themselves by the time the patient attains puberty. Treatment is necessary only in aggressive cases where there is severe facial deformity or vital functions are hampered. Surgical corrections are preferred when the lesion is in its dormant phase. The aim of the present case report is to illustrate a case of cherubism in a 9-year-old Saudi boy which is a very rare occurrence as only 1 case of cherubism has been reported so far in the Saudi Arabian population.

### KEYWORDS

Cherubism; Genetic mutation; Multilocular cystic lesions; Self-regressive lesion; Calcitonin therapy.

### RESUMO

Querubismo é uma desordem fibro-óssea hereditária rara caracterizada por aumento de volume bilateral da mandíbula e/ou maxila com graus variáveis de severidade. Ocorre devido a mutação dominante no gene SH3BP2 no cromossomo 4p16.3. Radiograficamente as lesões de querubismo aparecem como radiolucência multilocular semelhantes a bolhas de sabão nos ossos maxilares. Geralmente as lesões involuem espontaneamente quando o paciente atinge a puberdade. O tratamento se faz necessário apenas nos casos mais agressivos que demonstram deformidade facial severa ou comprometimento de funções vitais. Correções cirúrgicas são preferíveis quando a lesão está na fase dormente. O objetivo do presente relato é ilustrar um caso de querubismo em um paciente de 9 anos da Arábia Saudita, sendo este um evento raríssimo com apenas um outro caso relatado na população da Arábia Saudita.

### PALAVRAS-CHAVE

Querubismo; Mutação genética; Lesão cística multilocular; Lesão com regressão espontânea; Terapia com calcitonina.

## INTRODUCTION

Cherubism, also called Multilocular Cystic Disease of the jaws, is an uncommon inherited bone condition occurring in paediatric patients of age 2- 7 years and early teenagers and regresses following puberty. Sir William Jones first studied it in 1933 in a family in which several members were affected. He coined the term CHERUBISM, which means children with “full round faces gazing upwards to the sky”, describing the affected patients’ appearance [1,2].

Cherubism occurs mainly due to mutation in the SH3 - domain binding protein 2 (SH3BP2) on chromosome 4p16.3, called autosomal dominant cherubism [3-5]. According to the WHO, it is a self-limiting ailment [6]. In cherubism, the normal bone structure is substituted by proliferating fibrous tissue consisting of many osteoclasts. The resultant bony septae give the characteristic multilocular appearance on radiographs [7].

It is a familial disease with a 100% penetrance in males and a 50%–70% penetrance in females for the autosomal dominant characteristic (2:1). Although it was initially diagnosed as “familial fibrous dysplasia of the jaws,” current genomic studies have revealed that it is a distinct entity at the molecular level [8,9]. Although cases without a familial past have also been documented, most cases exhibit a linked family history [10,11].

The diagnosis of cherubism is made using histology and radiographic evidence though biopsy and histopathologic examinations are not an absolute necessity in most cases to confirm the diagnosis of cherubism [12]. The clinical findings include Familial occurrence, bilateral swelling of the mandible, high-arched palate, lack of second and third molars, lymph node swelling, self- resolution of the lesion after puberty [13]. Numerous dental alterations can be observed, such as early primary tooth shedding, misplaced permanent teeth, supernumerary teeth, irregular eruption patterns, and root resorption [13,14]. Clinical signs such as painless lesions, increased bone volume, and sporadic symptoms, including tooth loss, slobbering, xerostomia, impacted teeth, phonetic issues, and malocclusion, impact the patients’ psychosocial well-being and aesthetics [14]. In rare circumstances, airway impairment is accompanied by vision and hearing loss [15-17].

Many variations have been reported in cherubism regarding the age of presentation, clinical signs and symptoms, gender and familial history. Motamedi and Raposo- Amaral suggested a grading system to classify cherubism based on the facial bones involved and other signs and symptoms [18,19] (Figure 1). Though many clinicians use this classification to define the lesion and other signs, some clinicians don’t

## CLASSIFICATION OF CHERUBISM

Motamedi (1998) and Raposo-Amaral (2007)

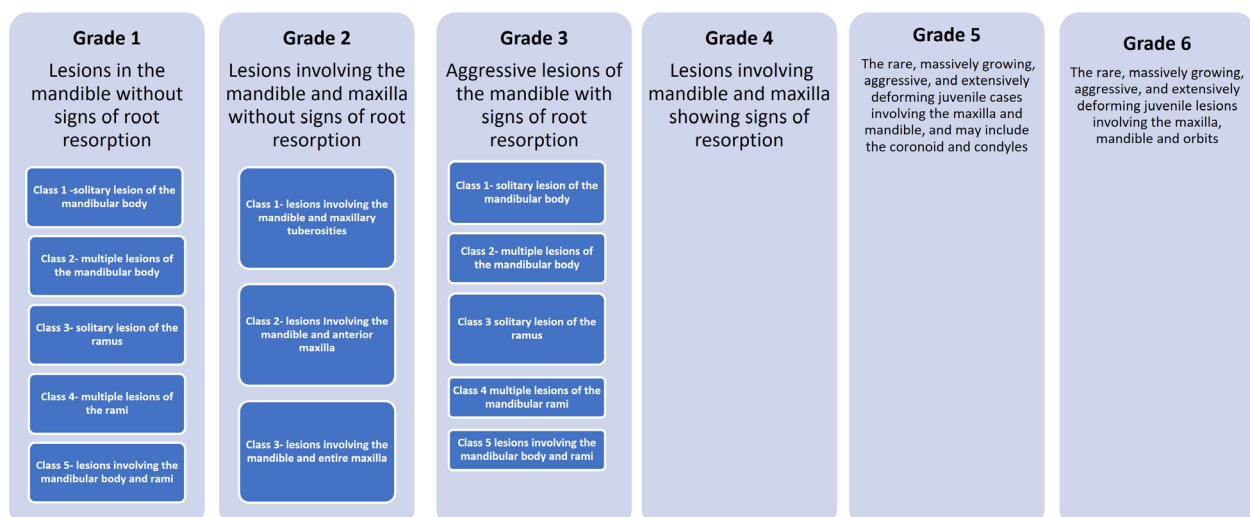


Figure 1 - Classification of Cherubism according to Motamedi (1998) and Raposo- Amaral (2007).

use the classification as the presentation of the disease is unique in different patients.

Cherubism is a self-limiting disease that degenerates extemporaneously after adolescence. The radiolucent spaces are filled up with a sclerotic bone. In rare cases, the radiolucent spaces may remain, and surgical correction is necessary to restore normal facial features [19,20].

The present case report aims to illustrate a case of cherubism in the Saudi Arabian population which is a very rare occurrence as only 1 case of cherubism has been reported and published in the population.

## CASE PRESENTATION

In the present case, an 8 years 9 months old male child reported to the dental clinics of Jizan University for a routine dental check-up. During the oral examination, it was detected that the cheeks of the patient were abnormally swollen and chubby (Figure 2). There was no history of pain or fever or any associated symptoms. The mother reported that the swelling was present for 2 years with no obvious discomfort to the patient.

When examined, the patient was noted to have mixed dentition with exfoliating primary teeth and erupting permanent teeth. In addition, 75 was affected by dental caries, and 85 was missing due to extraction that was done previously. Panorama and CBCT were advised for further diagnosis.

The orthopantomogram (OPG) showed multiple, symmetric radiolucent lesions in the angle of the mandible, giving a typical soap bubble appearance, a classical sign of cherubism (Figure 3). In addition, these multilocular lesions extended into the ramus and coronoid process of the mandible, sparing the condylar process, a pathognomonic sign of cherubism. In OPG, maxillary involvement was not evident. Thus, CBCT was done.

CBCT imaging showed the absence of a significant part of the body of the mandible, ramus of the mandible and the coronoid process (Figures 4 and 5). The maxillary tuberosity was involved, pushing the permanent teeth buds mesially. No histopathological analysis was undertaken for this case as the presenting symptoms were not the chief complaint and it

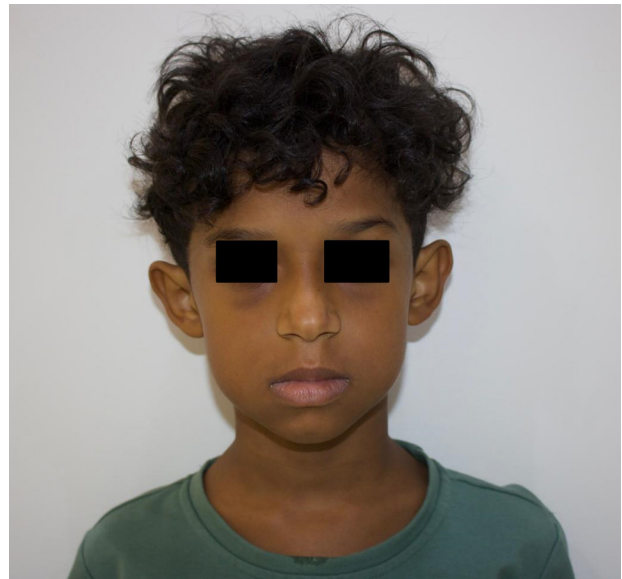

Figure 2 - Facial Appearance of the patient.

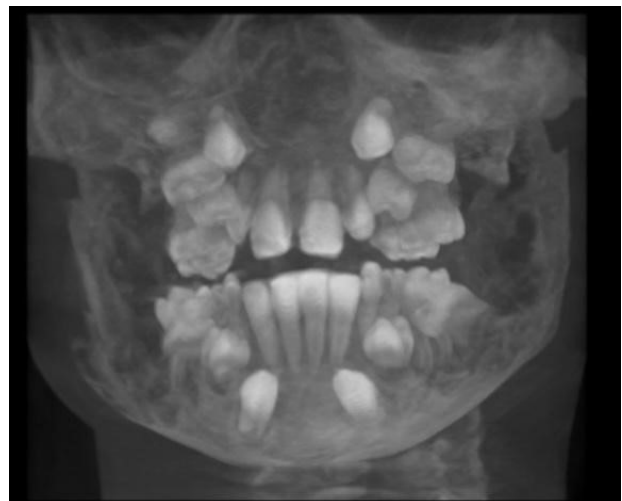


Figure 3 - CBCT (Frontal View).

would be an invasive procedure for the paediatric patient.

Diagnosis of the present case was made based on the age of the patient, presenting clinical symptoms and radiological findings. Patient was treated for dental caries with least surgical intervention and patient was advised a long-term follow-up.

## DISCUSSION

Cherubism is a type of non-cancerous bone disease that only affects the jaws. Additionally, some publications refer to this condition as



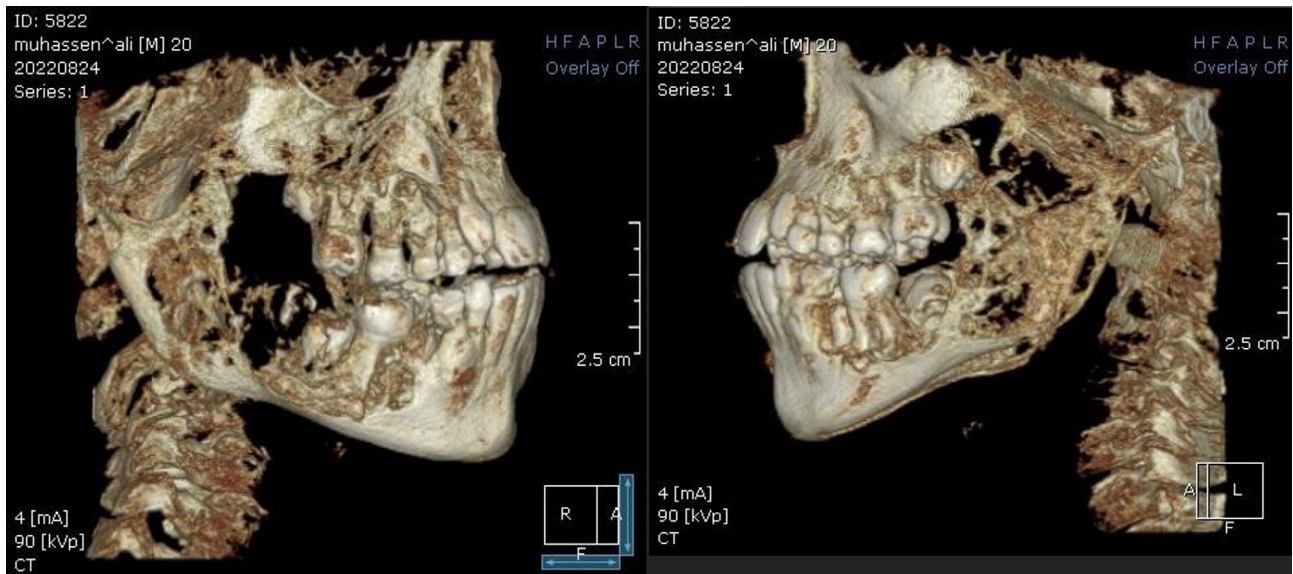


Figure 4 - CBCT image (Lateral View).

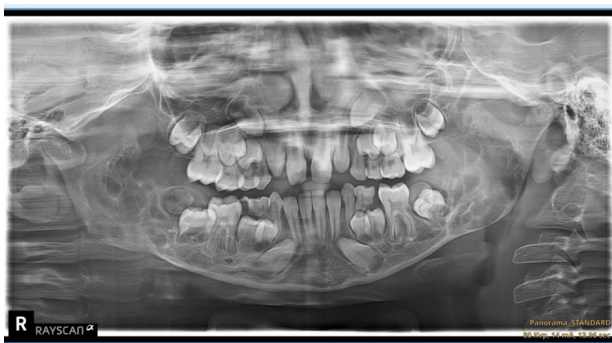

Figure 5 - OPG of the Patient.

familial fibrous dysplasia, which is a member of the family of fibrous osseous illnesses [6,7]. Cherubism is associated with mutations in genes encoding the binding protein SH3BP2 on chromosome 4p16.3 [21,22]. Mutation in this binding protein causes dysregulation of the Msx-1 gene which is implicated in the regulation of mesenchymal collaboration in craniofacial morphogenesis [22].

In cherubism, the affected child appears normal at birth, but unilateral or bilateral painless swelling occurs at the age of 14 months to 12 years on average. Frazier et al. [23] reported a case of unilateral swelling of the maxilla and mandible in an 8-year-old female patient. In the present case, an 8-year-old boy was affected by bilateral, painless swelling. This swelling may continue to grow until puberty and later undergo involution where the radiolucent space is

replaced with sclerotic bone [24]. By the 4<sup>th</sup> or 5<sup>th</sup> decade of life, normal facial features are naturally restored. However, in extreme or severe cases surgical corrections may become necessary [25].

Cherubism has been classified in the past by Marck and Kudryk in 1992 into 4 grades based on the bones involved and the symmetry of the lesion [26]. In 2007, Motamedi and Raposo- Amaral suggested a system of grades to classify cherubism based on the facial bones involved and other signs and symptoms [18,19]. This classification was more widely accepted as it describes the disease in terms of grade, class and sub-class (Figure 1). According to this classification, our case could be categorized into the grade 2 class1 category.

In the present case, OPG was taken to rule out swelling due to dental infection. The mother of the patient mentioned that the swelling was present for 2 years. In OPG, bilateral, multilocular radiolucencies were observed in the ramus of the mandible involving the coronoid process however preserving the condyles. This observation is a pathognomonic sign of cherubism [27]. But this was not found to be the case as Bianchi et al. reported a case of cherubism with condylar involvement [28]. The roots of primary and permanent teeth were found to be intact, and no signs of resorption were observed. These OPG observations were found to be similar to a case reported by Shakeel et al. [29] To confirm the involvement of maxilla, CBCT was advised for the patient. In CBCT, it was seen that the maxillary

tuberosity was involved in displacing the primary and permanent teeth anteriorly. The base of the skull was observed to be intact. No resorption of the roots of permanent teeth was observed.

The radiographic differential diagnosis for cherubism comprises of brown tumour of hyperparathyroidism, craniofacial fibrous dysplasia, Gigantiform cementoma and Jaffe-Campanacci syndrome. Even though lesions of cherubism and craniofacial fibrous dysplasia display similar radiologic features, they can be differentiated based on clinical and histological findings [30]. Signs and symptoms more explicitly found in cherubism are bilateral swellings of the mandible, the lesion involving the maxilla and mandible, and self-regression of the lesions by adolescence [31,32]. Whereas patients suffering from fibrous dysplasia classically do not present with swelling of cheeks and eyes turning upwards, or displacement of teeth. Cherubism is reported to be associated with various other syndromes such as Noonan's syndrome, neurofibromatosis type 1, fragile X syndrome and Ramon's syndrome. Biopsy and histopathological examination are not absolute necessity in cases of cherubism because histologically we can see many randomly dispersed multinucleated giant cells and vascular spaces in the connective tissue stroma which is a similar finding in hyperthyroidism and Central giant cell granuloma, making it nearly impossible to differentiate between the disorders [12,33]. Yet, in some reports biopsies have been performed in order to address the chief complaint of the patient [34].

Cherubism is a self-regressing disease which resolves by puberty. Treatment is necessary only in cases where esthetics and mastication, and deglutition are compromised. It is preferred by physicians and surgeons to wait till puberty before opting for a treatment plan [35]. Surgical correction is done in aggressive forms of cherubism where ocular disturbances and problems with breathing or deglutition are reported. If surgery is done in the active phase of the lesion, there is a higher chance of relapse, and the disease may exacerbate [36]. Calcitonin therapy has been reported to be successful in reducing the resorption of bone and reducing the maxillary and mandibular cystic lesions [37]. In the present case, no treatment was advised for the swelling of the jaw. Dental caries with primary molars was restored with the least surgical intervention. The patient has been placed under observation

and is recalled at an interval of 6 months for examination.

## CONCLUSION

There are no pathognomonic features of cherubism as every case presents with diverse signs and symptoms. The diagnosis of cherubism can be done by considering the clinical features, radiological features and histological features. Though histological features are inconclusive and do not significantly contribute to the diagnosis. Genetic testing can be a more advanced diagnostic tool in the case of cherubism.

## Author's Contributions

NB: Corresponding author. BAH, NAK, MAQ, LEN, FHK: Co-author.

## Conflict of Interest

There is no conflict of interest.

## Funding

Nil.

## Regulatory Statement

This case report was prepared in accordance with all the provisions of the local human subjects oversight committee guidelines and policies of: Ethics Committee of Scientific Research at Faculty of Dentistry.

## REFERENCES

1. Jones WA. Further observations regarding familial multilocular cystic disease of the jaws. *Br J Radiol.* 1938;11(124):227-41. <http://dx.doi.org/10.1259/0007-1285-11-124-227>.
2. Jones WA, Gerrie J, Pritchard J. Cherubism: familial fibrous dysplasia of the jaws. *J Bone Joint Surg Br.* 1950;32(3):334-47. <http://dx.doi.org/10.1302/0301-620X.32B3.334>.
3. Mangion J, Rahman N, Edkins S, Barfoot R, Nguyen T, Sigurdsson A, et al. The gene for cherubism maps to chromosome 4p16.3. *Am J Hum Genet.* 1999;65(1):151-7. <http://dx.doi.org/10.1086/302454>. PMID:10364527.
4. Carvalho Silva E, Carvalho Silva GC, Vieira TC. Cherubism: clinicoradiographic features, treatment and long-term follow-up of 8 cases. *J Oral Maxillofac Surg.* 2007;65(3):517-22. <http://dx.doi.org/10.1016/j.joms.2006.05.061>. PMID:17307601.
5. Özkan Y, Varol A, Turker N, Aksakalli N, Basa S. Clinical and radiological evaluation of cherubism: a sporadic case report and review of the literature. *Int J Pediatr Otorhinolaryngol.* 2003;67(9):1005-12. [http://dx.doi.org/10.1016/S0165-5876\(03\)00179-4](http://dx.doi.org/10.1016/S0165-5876(03)00179-4). PMID:12907058.

6. Pindborg JJ, Kramer IR. Histological typing of odontogenic tumours, jaw cysts, and allied lesions. 1st ed. Geneva: WHO; 1971. p. 18-9.
7. Jones WA. Further observations regarding the familial multilocular cystic disease of the jaws. *Br J Radiol.* 1938;11(124):227-41. <http://dx.doi.org/10.1259/0007-1285-11-124-227>.
8. Reichenberger EJ, Levine MA, Olsen BR, Papadaki ME, Lietman SA. The role of SH3BP2 in the pathophysiology of cherubism. *Orphanet J Rare Dis.* 2012;7(Suppl 1):S5. <http://dx.doi.org/10.1186/1750-1172-7-S1-S5>. PMID:22640988.
9. Lima GM, Almeida JD, Cabral LA. Cherubism: clinicoradiographic features and treatment. *J Oral Maxillofac Res.* 2010;1(2):e2. <http://dx.doi.org/10.5037/jomr.2010.1202>. PMID:24421967.
10. Hyckel P, Berndt A, Schleier P, Clement JH, Beensen V, Peters H, et al. Cherubism—new hypotheses on pathogenesis and therapeutic consequences. *J Craniomaxillofac Surg.* 2005;33(1):61-8. <http://dx.doi.org/10.1016/j.jcms.2004.07.006>. PMID:15694152.
11. Faircloth WJ Jr, Edwards RC, Farhood VW. Cherubism involving a mother and daughter: case reports and review of the literature. *J Oral Maxillofac Surg.* 1991;49(5):535-42. [http://dx.doi.org/10.1016/0278-2391\(91\)90185-O](http://dx.doi.org/10.1016/0278-2391(91)90185-O). PMID:2019904.
12. Papadaki ME, Lietman SA, Levine MA, Olsen BR, Kaban LB, Reichenberger EJ. Cherubism: best clinical practice. *Orphanet J Rare Dis.* 2012;7(Suppl 1):S6. <http://dx.doi.org/10.1186/1750-1172-7-S1-S6>. PMID:22640403.
13. Pontes FS, Ferreira AC, Kato AM, Pontes HA, Almeida DS, Rodini CO, et al. Aggressive case of cherubism: 17-year follow-up. *Int J Pediatr Otorhinolaryngol.* 2007;71(5):831-5. <http://dx.doi.org/10.1016/j.ijporl.2007.01.017>. PMID:17360048.
14. Prajapati VK. Non-familial Cherubism. *Contemp Clin Dent.* 2013;4(1):88-9. <http://dx.doi.org/10.4103/0976-237X.111609>. PMID:23853461.
15. Lima GM, Almeida JD, Cabral LA. Cherubism: clinicoradiographic features and treatment. *J Oral Maxillofac Res.* 2010;1(2):e2. <http://dx.doi.org/10.5037/jomr.2010.1202>. PMID:24421967.
16. Marx RE, Stern D. Oral and maxillofacial pathology: a rationale for diagnosis and treatment. Hanover Park: Quintessence Pub. Co.; 2012.
17. Khirani S, Kadlub N, Delord V, Picard A, Fauroux B. Nocturnal mouthpiece ventilation and medical hypnosis to treat severe obstructive sleep apnea in a child with cherubism. *Pediatr Pulmonol.* 2013;48(9):927-9. <http://dx.doi.org/10.1002/ppul.22686>. PMID:23129383.
18. Motamedi MHK. Treatment of cherubism with locally aggressive behavior presenting in adulthood: report of four cases and a proposed new grading system. *J Oral Maxillofac Surg.* 1998;56(11):1336-42. [http://dx.doi.org/10.1016/S0278-2391\(98\)90618-8](http://dx.doi.org/10.1016/S0278-2391(98)90618-8). PMID:9820222.
19. Raposo-Amaral CE, de Campos Guidi M, Warren SM, Almeida AB, Amstalden EM, Tiziane V, et al. Two-stage surgical treatment of severe cherubism. *Ann Plast Surg.* 2007;58(6):645-51. <http://dx.doi.org/10.1097/01.sap.0000248141.36904.19>. PMID:17522488.
20. Ueki Y, Mukai T, Yoshitaka T. Mechanism of inflammation in cherubism. *J Bone Miner Res.* 2010;25(Suppl 1):1.
21. Özkan Y, Varol A, Turker N, Aksakalli N, Basa S. Clinical and radiological evaluation of cherubism: a sporadic case report and review of the literature. *Int J Pediatr Otorhinolaryngol.* 2003;67(9):1005-12. [http://dx.doi.org/10.1016/S0165-5876\(03\)00179-4](http://dx.doi.org/10.1016/S0165-5876(03)00179-4). PMID:12907058.
22. Carvalho Silva E, Carvalho Silva GC, Vieira TC. Cherubism: clinicoradiographic features, treatment, and long-term follow-up of 8 cases. *J Oral Maxillofac Surg.* 2007;65(3):517-22. <http://dx.doi.org/10.1016/j.joms.2006.05.061>. PMID:17307601.
23. Frazier JJ, Sah SK, Reichenberger EJ, Liang H. Unilateral cherubism in a family with a history of bilateral cherubism: confirmed by SH3BP2 mutation. *J Oral Maxillofac Radiol.* 2018;6(3):59-64. [http://dx.doi.org/10.4103/jomr.jomr\\_30\\_18](http://dx.doi.org/10.4103/jomr.jomr_30_18).
24. Jain V, Sharma R. Radiographic, CT and MRI features of cherubism. *Pediatr Radiol.* 2006;36(10):1099-104. <http://dx.doi.org/10.1007/s00247-006-0261-8>. PMID:16847596.
25. Kau CH, Souccar NM, English JD, Kamel SG, Wong ME. The surgical and orthodontic management of cherubism in a growing child. *J Craniomaxillofac Surg.* 2012;40(3):229-33. <http://dx.doi.org/10.1016/j.jcms.2011.04.012>. PMID:21676623.
26. Marck PA, Kudryk WH. Cherubism. *J Otolaryngol.* 1992;21(2):84-7. PMID:1583713.
27. Wongworawat YC, Jack D, Inman JC, Abdelhalim F, Cobb C, Zuppan CW, et al. Regional lymph node enlargement in clinically severe cherubism. *Clin Pathol.* 2019;12:X19861107. <http://dx.doi.org/10.1177/2632010X19861107>. PMID:31321387.
28. Holmes KR, Holmes RD, Martin M, Murray N. Practical approach to radiopaque jaw lesions. *Radiographics.* 2021;41(4):E1164-85. <http://dx.doi.org/10.1148/rg.2021200187>. PMID:34086497.
29. Shakeel M, Imran M, Shafi M, Ahad M. Cherubism. *Oral Maxillofac Pathol J.* 2015;6(1):578-81.
30. Beaman FD, Bancroft LW, Peterson JJ, Kransdorf MJ, Murphey MD, Menke DM. Imaging characteristics of cherubism. *AJR Am J Roentgenol.* 2004;182(4):1051-4. <http://dx.doi.org/10.2214/ajr.182.4.1821051>. PMID:15039186.
31. Mangion J, Edkins S, Goss AN, Stratton MR, Flanagan AM. Familial craniofacial fibrous dysplasia: absence of linkage to GNAS1 and the gene for cherubism. *J Med Genet.* 2000;37(11):37e. <http://dx.doi.org/10.1136/jmg.37.11.e37>. PMID:11073546.
32. Yamaguchi T, Dorfman HD, Eising S. Cherubism: clinicopathologic features. *Skeletal Radiol.* 1999;28(6):350-3. <http://dx.doi.org/10.1007/s002560050530>. PMID:10450884.
33. Misra SR, Baskaran P, Gopal M, Rastogi V. Aggressive central giant cell granuloma of the mandible, a diagnostic dilemma. *J Oral Maxillofac Radiol.* 2015;3(3):88-91. <http://dx.doi.org/10.4103/2321-3841.170614>.
34. Patussi C, Sassi LM, Bixofix RB, Silva WPP, Shussel JL. Non-familial cherubism: report of a case. *Braz Dent Sci.* 2015;18(4):133-8. <http://dx.doi.org/10.14295/bds.2015.v18i4.1137>.
35. Roginsky VV, Ivanov AL, Ovtchinnikov IA, Khonsari RH. Familial cherubism: the experience of the Moscow Central Institute for Stomatology and Maxillo-Facial Surgery. *Int J Oral Maxillofac Implants.* 2009;38(3):218-23. <http://dx.doi.org/10.1016/j.ijom.2008.10.010>. PMID:19038533.
36. Peñarrocha M, Bonet J, Mínguez JM, Bagán JV, Vera F, Mínguez I. Cherubism: a clinical, radiographic, and histopathologic comparison of 7 cases. *J Oral Maxillofac Surg.* 2006;64(6):924-30. <http://dx.doi.org/10.1016/j.joms.2006.02.003>. PMID:16713807.
37. de Lange J, van den Akker HP, Scholtemeijer M. Cherubism treated with calcitonin: report of a case. *J Oral Maxillofac Surg.* 2007;65(8):1665-7. <http://dx.doi.org/10.1016/j.joms.2006.06.266>. PMID:17656300.

**Nezar Boreak**  
(Corresponding address)

Jazan University, Department of Restorative Dental Sciences, Jazan, Saudi Arabia  
Email: nboraak@jazanu.edu.sa

Date submitted: 2022 Nov 16  
Accept submission: 2023 Feb 03