



CASE REPORT

Large desmoplastic fibroma: case report using microvascularized fibula graft for reconstruction

Fibroma desmoplásico de grandes proporções: relato de caso usando enxerto microvascularizado de fíbula para reconstrução

Cleverson PATUSSI¹, Laurindo Moacir SASSI¹, Regiane Benez BIXOFIS¹, Paola Andréia Galbiatti PEDRUZZI², Alfredo Benjamim Duarte DA SILVA³, Juliana Lucena SCHUSSEL¹

1 – Department of Oral and Maxillofacial Surgery – Erasto Gaertner Hospital – Curitiba/PR – Brazil.

2 – Department Head and Neck Surgery – Erasto Gaertner Hospital – Curitiba/PR – Brazil.

3 – Serviço de Cirurgia Plástica e Restauradora – Erasto Gaertner Hospital – Curitiba/PR – Brazil.

ABSTRACT

The Desmoplastic Fibroma is a benign rare tumor of fibroblastic origin, representing only 0.03% of benign bone tumors. Displays aggressive behavior and high rates of recurrence, which makes the treatment more aggressive. The authors present a case of an 11 years-old female, complaining of increased volume in the jaw. The patient had an extensive swelling of the left mandibular body with invasion of the border of the tongue and floor of the mouth at the same side. She had a history of 4 recurrences at the same site. Image exams revealed expansive lesion in body and ramus of the mandible with involvement of soft tissue on the lingual side of the lesion. The treatment was excision of the lesion with extra oral access and reconstruction with microvascularized fibula graft. The patient has been followed for 2 years with no clinical or radiographic signs and without recurrence.

KEYWORDS

Desmoplastic fibroma; Benign bone tumor; Microvascularized fibula graft.

RESUMO

O Fibroma Desmoplásico é um tumor benigno raro de origem fibroblástica que representa apenas 0,03% dos tumores ósseos benignos. Apresenta comportamento agressivo e elevadas taxas de recorrência, o que torna o seu tratamento mais agressivo. Os autores apresentam um relato de caso de uma paciente do sexo feminino de 11 anos de idade com queixa de aumento de volume em mandíbula. A mesma apresentou extensa expansão do corpo mandibular esquerdo, com invasão da borda da língua e assoalho da boca do mesmo lado, com histórico de quatro recorrências na mesma localização. Os exames de imagem revelaram lesão expansiva no corpo e ramo da mandíbula com envolvimento dos tecidos moles do lado lingual da lesão. O tratamento foi a excisão da lesão com acesso extra-oral e reconstrução com enxerto microvascularizado de fíbula. A paciente apresenta seguimento de 2 anos sem sinais clínicos ou radiográficos de recidiva.

PALAVRAS-CHAVE

Fibroma desmoplásico; Tumor ósseo benigno; Fíbula, enxerto microvascularizado.

INTRODUCTION

The desmoplastic fibroma (DF) is considered a rare benign tumor that presents an aggressive behavior with local infiltrative capacity [1-2]. It usually occurs in the first three decades of life and has higher rates of regional recurrence after treatment compared with other benign bone tumors [3-4]. It was first described

by Jaffe [5] in 1958 with the finding of multiple sites involved as tibia, scapula and femur. The first report on gnathic bone occurred in 1965 by Griffith and Irbyin [6], since numerous similar cases were observed [1-6]. The DF corresponds to 1% of all bone tumors and its treatment still generates discussion among authors [4]. Many surgical treatments were reported in literature, whereas, curettage has a high rate of recurrence and segmental resection is considered the

treatment of choice for this type of lesion [4]. Radiation and chemotherapy are also an alternative therapy for the treatment of desmoplastic fibroma, and no recurrences were observed with these modality of treatment. [4-7,8]

CASE REPORT

Caucasian 11 years-old female, in good general condition, was referred to Service of Oral and Maxillofacial Surgery of Erasto Gaertner Hospital (EGH) complaining of swelling of the face in the left jaw. (Figure 1)

Patient presented a left mandible swelling, with an invasion on the lateral border of the tongue and floor of the mouth in same side, extending from tooth 33 to retromolar area. Patient reported that the lesion was first diagnosed when she was 3 years, and recurred at age of 5 and 7. By the time she arrived at EGH, she had her fourth recurrence.

The computed tomography (CT) showed an expansive hypodense lesion in body and ramus of the mandible with infiltration of adjacent soft tissue, and rupture of the cortical bone. The CT examination, together with the clinical history and patient examination were essential for surgical planning. (Figure 2)

The lesion was fully resected and bone defect was reconstruct using a microsurgical fibula graft. (Figures 3 and 4) Histologically, moderate cellular collagenous stroma with spindle-shaped cell proliferation could be observed, as well as tumor cells showing cellular pleomorphism and hyperchromatic nuclei, compatible with desmoplastic fibroma diagnosis (Figures 5 and 6). Patient had a good outcome and showed no signs of recurrence after 2 years of follow-up. (Figures 7 and 8).

During the hospitalization and outpatient appointments, the patient had a multidisciplinary attention. A team of nutritionists, occupational therapist, speech therapist, psychologists and dentists ere involved on patient`s rehabilitation.

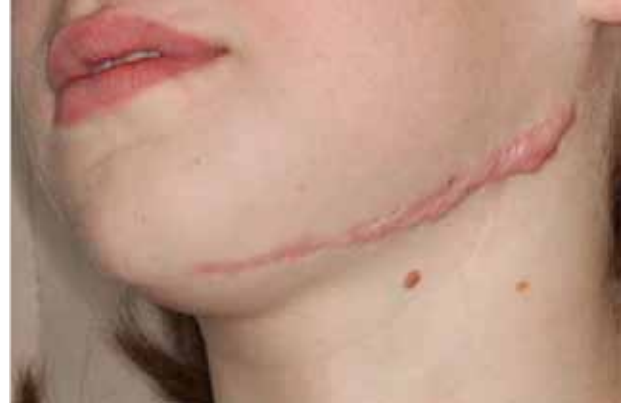

Figure 1 - Patient with scar in the mandibular region on the left side, with a discreet volume increase.

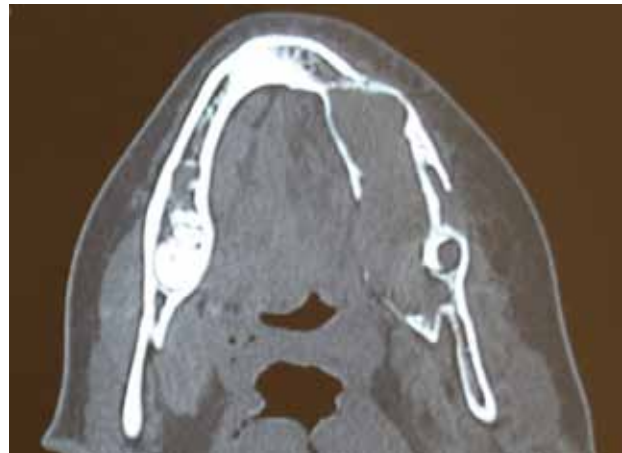


Figure 2 - Computed tomography showing lesion in the body and ramus of the mandible with a large volume increase of the tongue

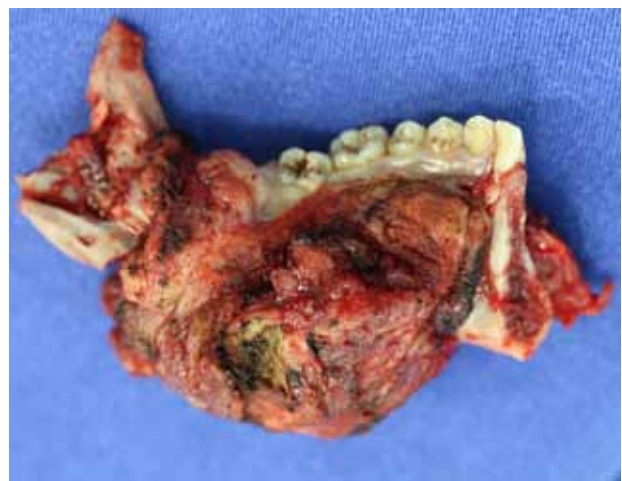

Figure 3 - Surgical specimen of resection of the lesion.

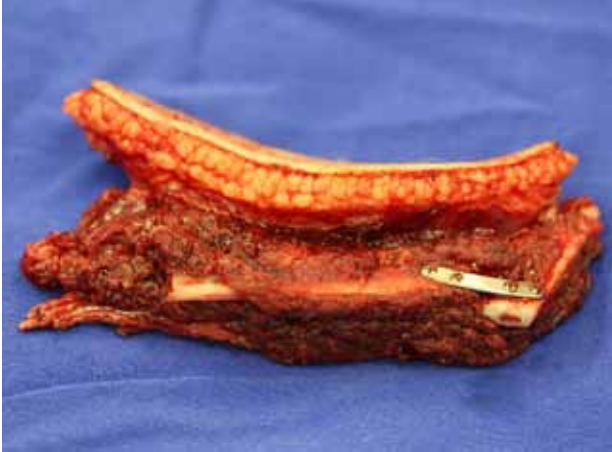

Figure 4 - Microvascularized fibula graft with reconstruction of the resected mandible.

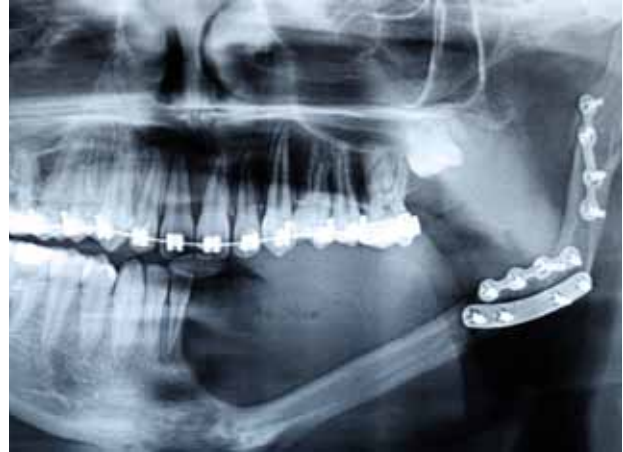

Figure 7 - Postoperative panoramic radiograph after 2 years.

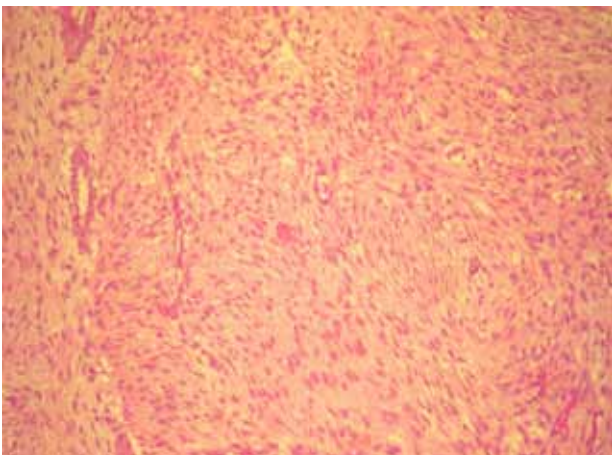


Figure 5 - Proliferation of spindled cells in a cellular stroma (H&E, 100X).

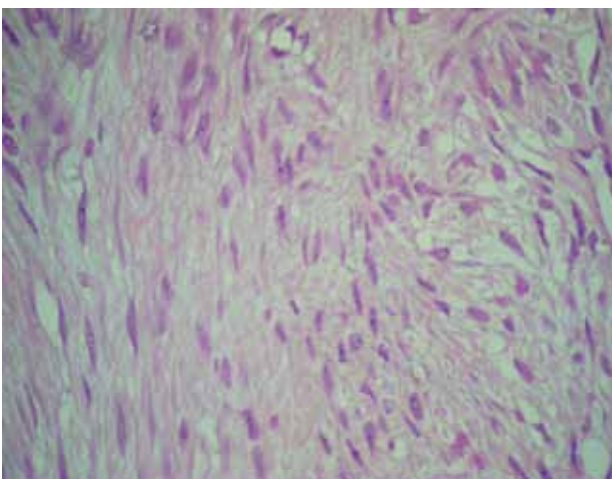


Figure 6 - Pleomorphic and hyperchromatic nuclei (H&E, 400X).

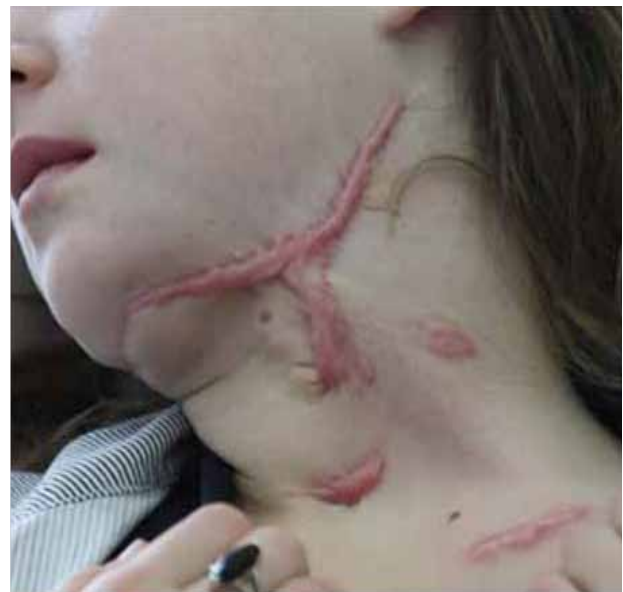

Figure 8 - Facial postoperative aspect after 2 years.

DISCUSSION

Said-Al-Naief et al. [4] described in 2006 a review of 40 years reporting 74 cases of desmoplastic fibroma in the jaws. They found it more frequently in the mandible (84%), in accordance with the case presented. Freedman et al [9] reported 70% of desmoplastic fibromas of the mandible occur in the molar-ramus region, 21% in the region of premolars, and only 9% in the anterior mandible.

The desmoplastic fibroma usually affects patients younger than 30 years old and shows no sex predilection, and has a high rate of recurrence [9-10]. As observed in the present case, patient had four recurrences until perform more aggressive surgical treatment. A microvascularized fibula graft was performed because of the lesion's extension, in order to improve rehabilitation and restore function with satisfactory aesthetic result.

The aim of mandible reconstruction is restore mastication, speech, swallowing and facial contour, and depends on surgical team experience as well patients characteristics. [11] The microvascularized fibula graft is an alternative for reconstruction of segments or even entire jaw. [12] The main objective of this technique is to keep the largest possible contact between the graft and the recipient area. A multidisciplinary team with head and neck surgeons, maxillofacial surgeons and plastic surgeons is necessary to perform all surgical procedures, including graft fixation and vascular anastomosis. In the presented case patient recovered function and aesthetics in a satisfactory manner.

Histologically the desmoplastic fibroma is a moderate cellular collagenous stroma with small elongated fibroblasts [8] and tumor cells showing cellular pleomorphism, hyperchromatic nuclei and mitosis. Both the lack of a capsule and the nature of the injury are trademarks of desmoplastic fibroma [4].

Tissue cellularity may vary from one area to another; the cellular areas may have less collagen and fibroblasts in a smaller volume. Important note that fibroblasts do not show atypia or mitosis. Bone tissue is not present inside the lesion, only in regions of interface between tumor margins and healthy tissue [8-9].

The differential diagnosis should consider well-differentiated fibrosarcoma and soft tissue fibromatosis. Clinically, DF and soft tissue fibromatosis bone infiltration are very similar.

Thus, it is necessary a biopsy to obtain a definitive diagnosis and to choose best treatment [8-9].

DF characteristically has a high rate of recurrence and local infiltrative nature, however, histologically, has no malignant features. Thus, with history of four recurrences and local destruction, a more aggressive treatment was chosen compared with previous. After 30 months follow-up, patient shows no signs of local recurrence and obtained satisfactory rehabilitation.

The use or not of chemotherapy and radiotherapy is a controversial subject in the literature. Some authors believe that neoadjuvant agents can induce a genetic mutation and sarcoma formation, while others believe in the benefits of these therapeutic modalities in the treatment of DF [4-7].

In a survey to the U.S. National Library of Medicine, National Institutes of Health (PUBMED) using the terms "Desmoplastic fibroma" + "jaws" in English literature were found 45 publications related to Desmoplastic Fibroma in the jaws, of which 23 are reviews, 7 present case report associated or not with literature report (1,4,7,9,13,14) and 15 articles related to this pathology. There is therefore a low frequency of this type of neoplasia considering the small amount of publications and discussion in the literature.

CONCLUSION

DF is a rare benign tumor, with infiltrative features and fast growth sometimes destructive. Better outcome are related to early diagnosis and surgical treatment. In advanced cases more aggressive treatment is recommended, with margins resection. It is thereby, surgeon's responsibility and criteria to decide the best approach for this tumor.

REFERENCES

1. Bohm P, Krober S, Greschniok A, Laniado M, Kaiserling E. Desmoplastic fibroma of the bone. A report of two patients, review of the literature, and therapeutic implications. *Cancer*. 1996;78:1011-23.
2. Langlais RP, Langland OE, Nortje CJ. *Multilocular radiolucencies* Baltimore: Williams & Williams; 1995.

3. Siemssen SJ, Anagnostaki T. Aggressive fibromatosis (extraabdominal desmoids) of the head and neck. *Br J Plast Surg*. 1984; 37:453-457.
4. Said-Al-Naief N, Fernandes R, Louis P, Bell W, Siegal GP. Desmoplastic fibroma of the jaw: a case report and review of literature. *Oral Surg Oral Med Oral Pathol Oral Radiol Endod*. 2006; 101:82-94.
5. Jaffe HL. Tumors and tumorous conditions of the bones and joints. Philadelphia: Lea & Febiger; 1958. p.298.
6. Griffith JG, Irby WB. Desmoplastic fibroma: report of a rare tumor of the oral structures. *Oral Surg Oral Med Oral Pathol*. 1965;20:269-75.
7. Nag HL, Kumar R, Bhan S, Awasthy BS, Julka PK, Ray RR. Radiotherapy for desmoplastic fibroma of bone: a case report. *Journal of Orthopaedic Surgery*. 2003;11(1):90-93
8. Boedeker D, Kelsch R, Kraut R. Desmoplastic fibroma of the anterior maxillary alveolus. *J Oral Maxillofac Surg*. 2011 Aug; 69(8): 2164-6.
9. Freedman PA, Cardo VA, Kerpel SM, Lumerman H. Desmoplastic fibroma (fibromatosis) of the jaw bones: Report of a case and review of the literature. *Oral Surg Oral Med Oral Pathol*. 1978;46:386.
10. Herford A, Reder P, Ducic Y. Multifocal desmoplastic fibromas of the mandible. *J Oral Maxillofac Surg*. 2001;59:1078.
11. Sassi LM, Dissenha JL, Pedruzzi PAG, Oliveira, BV. Vascularized fibular graft for mandibular reconstruction - a new technique (variety IV). *Rev. Bras. Cir. Cabeça Pescoço*. 2011Apr;40(2):90-2.
12. Sassi LM, Dissenha JL, Pedruzzi PAG, Cervantes O, Ramos GHA, Oliveira, BV. Reconstruction with microvascularized fibula graft in mandibles with double segment in toothed mandible body – Variation II. *Rev. Bras. Cir. Cabeça Pescoço*. 2007 July; 36 (3):183-4,
13. Jamali M. Desmoplastic fibroma: report of rare lesion in unusual craniofacial location. *N Y State Dent J*. 2013 Apr;79 (3):43-5
14. Gondak RO, Corrêa MB, da Costa MV, Vargas PA, Lopes MA. Maxillary desmoplastic fibroma with initial symptoms suggestive of sinusitis. *Oral Surg Oral Med Oral Pathol Oral Radiol*. 2013;116(6):e510-3. doi: 10.1016/j.oooo.2013.03.016. Epub 2013 May 10.

Cleverson Patussi
(Corresponding address)

Department of Oral and Maxillofacial Surgery, ErastoGaertner Hospital
Rua Dr. Ovande do Amaral, 20. Curitiba, Brazil 81520-060
e-mail: cleversonpatussi@hotmail.com

Date submitted: 2013 Apr 30

Accept submission: 2013 Oct 21