

Evaluation of the condylar position in subjects with temporomandibular joint functional disorders by cone beam computed tomography

Avaliação da posição condilar de sujeitos com disfunção temporomandibular funcional por meio de tomografia computadorizada de feixe cônico

Marcelo Oliveira MAZZETTO¹, Giovana Cherubini VENEZIAM¹, Laís Valencise MAGRI¹, Mario Kaissar NASR¹, Alexandra Faria PAIVA¹, Guiovaldo PAIVA²

1 – Department of Restorative Dentistry – Ribeirão Preto School of Dentistry – University of São Paulo (FORP-USP) – Ribeirão Preto – SP – Brazil.

2 – Center of Diagnosis and Treatment of the Temporomandibular Joint at São Paulo

ABSTRACT

Objective: The aim of the study was to investigate the condylar position inside the articular cavity in temporomandibular disorder (TMD) subjects with signs and symptoms of functional articular disorders through images made with cone beam computed tomography (CBCT) at sagittal plane. **Material & Methods:** CBCT temporomandibular joint images of 62 patients (13 male and 49 female, mean age, 39.7 years) with intra-articular signs and symptoms diagnosed by the Craniomandibular Index were analyzed using the measurement method recommended by Kawamura and Ikeda (2009). We obtained linear measures of posterior space (PS), superior space (SS), and anterior space (AS) to determine the condyle position for each joint. T-test for independent samples for comparison between genders and ANOVA for age intervals was applied. **Results:** Statistical significant differences were found between males and females with TMD for SS of right temporomandibular joint (TMJ) and PS and SS of left TMJ ($p < 0.05$). By age-intervals, the statistical comparison showed no significant differences in the joint space among different age-intervals ($p > 0.05$). It was found that in TMD patients PS was slightly reduced, while SS and AS were slightly increased. **Conclusion:** There is no difference in condylar position by age-intervals; males present the superior space higher than females and; subjects with intra-articular TMD presented a more posterior and inferior condylar position.

KEYWORDS

Temporomandibular Disorders; Tomography Emission-Computed; Mandibular Condyle.

RESUMO

Objetivo: O objetivo deste trabalho foi investigar a posição condilar dentro da cavidade articular em sujeitos com Disfunções Temporomandibulares (DTM) através de imagens realizadas com tomografias computadorizadas com feixe cônico (CBCT) no plano sagital. **Material e Métodos:** Imagens de CBCT das articulações temporomandibulares de 62 pacientes (13 homens e 49 mulheres, com idade média, 39,7 anos) com sinais e sintomas intra-articulares diagnosticadas pelo Índice Craniomandibular (Fricton e Schiffman, 1986) foram analisadas utilizando o método de medida preconizado por Ikeda e Kawamura (2009). Foram obtidas as medidas lineares de espaço posterior (PS), espaço superior (SS), e o espaço anterior (AS) para determinar a posição do côndilo para cada articulação. Para comparação entre sexos foi utilizado o Teste-T (amostras independentes) e para comparação dos intervalos de idade foi utilizado o ANOVA. **Resultados:** Foi observada diferença estatisticamente significante entre homens e mulheres com DTM para SS da articulação temporomandibular (ATM) direita e SS e PS da ATM esquerda ($p < 0,05$). Não foi encontrada diferença na análise por intervalo de idade ($p > 0,05$). Sujeitos com DTM apresentaram PS ligeiramente reduzido e AS e SS aumentados. **Conclusão:** Não há diferença na posição condilar de acordo com a idade; homens apresentam o espaço superior maior, quando comparados às mulheres e; sujeitos com DTM articular apresentam uma posição condilar mais posterior e inferior.

PALAVRAS-CHAVE

Disfunção temporomandibular; Tomografia computadorizada; Côndilo mandibular.

INTRODUCTION

Temporomandibular Disorders (TMD) comprise a group of skeletal muscle and neuromuscular conditions that affect temporomandibular joints (TMJ), mastication muscles, and all of the associated tissues [1].

In the literature, it is recognized that TMD diagnosis according to its subtypes has been often difficult. The diagnosis of signs and symptoms of different categories may coincide; additionally a clinical problem may be present at the same time and the clinical signs may be difficultly to measure consistently [2].

Thus currently, TMD has been characterized by the report as a sign or a combination of signs and symptoms that may be characterized by the following evaluation instruments: Helkimo Index, Craniomandibular Index and RDC/TMD [3,4].

The literature recommended that the clinical TMD assessment and differential diagnosis are based on information obtained from the patient's historical records, clinical examination and, TMJ radiograph or other imaging procedures, when indicated. [1,5].

Several imaging modalities have been used to show the condyle position in the articular cavity. Cone Beam Computed Tomography (CBCT) has been used for obtaining tridimensional (3D) image of the temporomandibular joint (TMJ) and has been shown to outline the articular structures with high precision [6].

Meanwhile, a fundamental question regarding the use of images for TMJ evaluation is which would be the ideal condyle position in the articular cavity when the teeth are at maximum habitual intercuspation. For this reason many authors have carried out studies on asymptomatic subjects and TMD patients attempting to establish standards for the articular space measurement and determine the ideal condylar position in the articular fossa

[6-8]. However, there are several evaluation methodologies described in the literature and there is no consensus on both the best method and specific physiological condyle position [9].

It is believed that an excellent mandible function is a pre-requisite for the condyle/disc health and it should be considered in the study on the relationship between the dysfunction of the stomatognathic system and the occlusion [6].

The aim of this study was to evaluate the condyle position within the articular cavity in subjects with Temporomandibular Disorders who had signs and symptoms of functional joint problems through images performed with cone beam computed tomography (CBCT) at sagittal plane, using the same methodology to measure the articular space proposed by Ikeda and Kawamura in 2009 [6].

MATERIAL & METHODS

This research was approved by the Research Ethics Committee of Ribeirão Preto School of Dentistry, University of Sao Paulo (process number no. (2008.1.1058.58.3 CAAE 0064.0.138.000 -08).

The patients were initially evaluated through the Craniomandibular Index, which is subdivided into: 1) Dysfunction index, containing items that reflect pain and functional problems in the TMJ; and 2) Palpation Index identifying the muscle pain [3].

Sixty-two TMD patients with positive responses to the Dysfunction index of the Craniomandibular Index were selected. Inclusion criteria comprised the following signs and symptoms: presence of TMJ noise during mandibular movements and restriction of movements associated with or without the presence of pain during capsular palpation. This study included 13 males and 49 females aged between 16 and 64 years-old (mean of 39.7 years-old).

CBCT images were obtained with i-CAT system (Imaging Sciences International, Hatfield,

PA, USA). The volumes were reconstructed with 0.3 mm isometric voxel, with exposure to 120 kVp, tube current of 37.10 mA and exposure time of 17.8 s. The patient was placed at upright position seated with their back in a direction perpendicular to the ground. The head was stabilized with ear rods in the external auditory canal. The images were analyzed with the In Vivo Dental program version 5.0 (Anatomage Inc., USA) (Figure 1).

The standardized linear measurements of the space between the condyle and the articular fossa were performed as proposed by Ikeda and Kawamura [6]. A true horizontal line obtained from the natural position of the head was used as reference. The distance from the uppermost point of the condyle (SC) to the uppermost articular fossa (SF) was measured as the superior joint space (SS). Tangent lines to the most prominent anterior and posterior borders of the condyle were traced from SF. The distance of the anterior (AC) and posterior (PC) tangents to points of the articular fossa were measured at right angles, showing the anterior (AS) and posterior (PS) spaces of the joint (Figure 2).

The spaces were measured on images by 3 experienced specialists in temporomandibular disorders and orofacial pain, through using the Software Invivo5 Anatomy Imaging Software

(Anatomage Inc., USA). For the statistical analysis, 124 measurements were obtained, comprising 62 measurements on the right side and 62 on the left. The considered values for descriptive analysis and statistics were obtained through an average of the measurements from the 3 evaluators.

After the normality assessment, t-test for independent samples was used for comparison between genders. For comparison age intervals (16 - 30, 31 - 45, 46 - 64), ANOVA was applied.

RESULTS

PS, SS and AS average measurements were 1.9 mm (DP 0.5), 3.1 mm (DP 0.9), 2.0 mm (DP 0.5), respectively. Right TMJ exhibited 1.9 mm (DP 0.5), 3.0 mm (DP 1.0) and 1.9 mm (DP 0.5), while left TMJ showed 1.8 mm (DP 0.7), 3.2 mm (DP 1.0) 2.0 mm (DP 0.7), respectively.

The statistical analysis showed no statistical significant differences in the condylar position between males and females with temporomandibular disorder. Precisely, the differences were checked for SS of R TMJ and PS and SS of L TMJ ($p < 0.05$), so that the measurement observations suggested that the joint space in these regions was higher in male (Table 1).

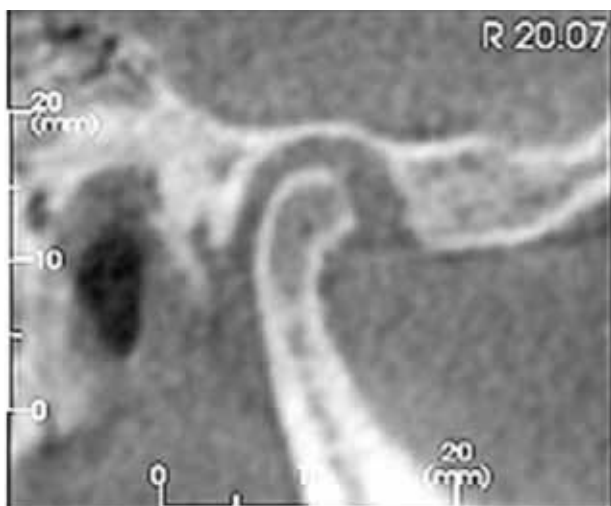


Figure 1 - CBCT image of a TMJ patient's research.

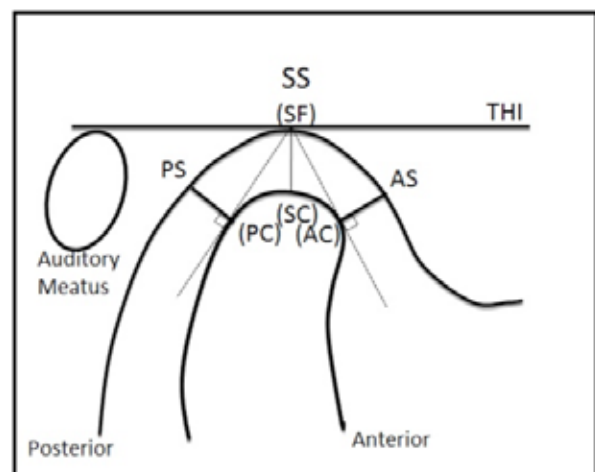


Figure 2 - Pattern used for measurements of condylar space as proposed by Ikeda e Kawamura, 2009.

Table 1 - Statistics for comparison between genders, with average and standard-deviation (T-student Test).

			Female	Male	p-values
RTMJ	PS	Aver	1.58	2.13	0.0667
		SD	1.84	0.41	
	SS	Aver	2.83	3.64	0.0069
		SD	0.95	0.87	
	AS	Aver	1.93	2.02	0.5674
		SD	0.53	0.55	
LTMJ	PS	Aver	1.72	2.33	0.0020
		SD	0.57	0.75	
	SS	Aver	2.93	4.04	0.0003
		SD	0.88	1.08	
	AS	Aver	2.06	1.96	0.6975
		SD	0.78	0.65	

When the subjects were divided by age-intervals of 16 to 30, 31 to 45 and 46 to 64, the statistical comparison showed no significant differences in the joint space among different age-intervals ($p > 0.05$) (Table 2).

In this study, when articular TMD subjects averages were descriptively compared with the averages found in asymptomatic subjects with ideal TMJ functionality by Ikeda and Kawamura (PS 2.1 ± 0.3 mm; SS 2.5 ± 0.5 mm; AS 1.3 ± 0.2 mm) it was found that in TMD patients PS was slightly reduced, while SS and AS were slightly increased [6].

Table 2 - Statistical comparison of condylar position by age intervals (16-30, 31-45 and 46-64) – (ANOVA).

Age			16-30	31-45	46-64	p-values
	Patients		12	33	17	
RTMJ	PS	Aver	1.88	2.00	1.80	0.3142
		SD	0.37	0.52	0.37	
	SS	Aver	2.46	3.15	3.08	0.1049
		SD	0.66	1.00	1.08	
	AS	Aver	1.84	1.99	1.94	0.7050
		SD	0.41	0.58	0.54	
LTMJ	PS	Aver	1.74	1.97	1.67	0.2526
		SD	0.41	0.76	0.51	
	SS	Aver	2.82	3.28	3.17	0.5688
		SD	0.61	1.07	1.15	
	AS	Aver	2.14	2.00	2.05	0.8579
		SD	0.75	0.68	0.90	

DISCUSSION

Currently, temporomandibular joint imaging tests have been one of the most accepted auxiliary diagnosis procedures in scientific literature [1]. Radiographic techniques and magnetic resonance imaging have been used for the observation of the morphology of articular structures and the spatial relationship among them [6,10-12]. Magnetic resonance imaging has also been used for the evaluation of disc displacement [13]. Although it is thought that the conventional tomography allows a good view of joint morphology, it does not delineate tissues of different densities as clearly as the computerized tomography [6]. CBCT method produces images with high resolution and with a measurement error significantly lower than that of spiral computerized tomography [14].

However, in spite of various imaging modalities developed and validated for use in the diagnostic evaluation of the temporomandibular joint, their value has been limited mainly to the discovery of intracapsular pathological conditions [1].

It is recognized that TMD differential diagnosis of according to one of its subtypes is often difficult and there remains a lack of agreement with the exact criteria that define the various TMD subgroups, especially in research, which creates difficulties in establishing viable rates and procedures to be used in determining homogeneous subject groups for research. Notwithstanding, to obtain and compare results from different epidemiological studies, it is necessary to make a standardized data collection and instrument(s) to measure the degree of severity of the temporomandibular disorder.

In this study, patients were evaluated with the Craniomandibular index proposed and validated by Fricton and Schiffman [3,15]. This index is based on thorough clinical assessment and standardized mandibular movements, joint sounds and soreness to palpation of TMJ and masticatory muscles and neck, and is currently still very used and accepted in research. This study included patients who had positive responses in Dysfunction Index, which assesses the presence of joint problems, regardless of

the values obtained during Palpation Index. It is likely that this study has included patients with various joint pathologies, such as disc displacement with and without reduction, osteoarthritis, and structural incompatibilities, among others. The aim of this study was to evaluate the condylar positioning in patients with various signs and symptoms of functional joint problems, since the positioning of the condyle within the fossa in patients showing articular disc displacement, already has been extensively studied by demonstrating that, in general, there is a predominance of one position: the most posterior condyle in the articular fossa [7,10,16].

According to Vasconcelos Filho et al. two conditions could explain an association between the posterior position of the condyle and the displacement of the disc: 1) the condyle is displaced posteriorly because of reduced joint space resulting from the positioning anterior disc, 2) the condyle was located posteriorly which predisposed the disc displacement [17].

The results of this study showed a large variation in condylar position that can be noticed from the high value of standard deviation obtained; however, there was predominance of anterior and superior joint spaces slightly larger than the posterior space. These results disagree with those found by Ikeda and Kawamura (2009) in asymptomatic subjects in whom the superior and posterior spaces were higher than the anterior space, with a smaller standard deviation value [6]. Other studies on asymptomatic and normal TMJ subjects also observed an anteriorized condyle position (non-centralized) through computed tomography [18-20].

The comparison of patients by age-intervals of 16 to 30, 31 to 45 and 46 to 64, showed no significant differences in joint space.

Nevertheless, the comparison between genders showed a significant difference in the superior joint space, with males showing a space relatively larger than females. Similar results were found by Kinniburgh et al., (2000) when

evaluating asymptomatic subjects, but disagree with those presented by Ikeda and Kawamura (2009) who not verify the difference between genders [20]. It was also possible to observe that the values found in this study were higher for the superior space than those found in joints considered excellent by Ikeda and Kawamura (2009), but they were within the results found by Kinniburgh et al., (2000) in asymptomatic subjects [6,20].

Studies have also attempted to evaluate the influence of occlusion in TMJ. While some authors have suggested the relationship between the type of occlusion and shape of the articular fossa and condyle or condylar position within the fossa, other authors found no correlation or unique characteristics in the TMJ patients with normal occlusion [20-23].

Finally, it is important to consider that while imaging tests are of great value in assessing patients with TMJ internal disorders and that these data can provide useful clinical information, controversies regarding the etiology of TMD and its relation to occlusal factors and condylar position exist. Therefore, when considering the treatment of TMD according to the recommendations of the American Association of Dental Research (AADR), conservative and reversible interventions has been shown to be both appropriate and successful; in addition, internal derangements of the temporomandibular joint usually do not need to be "corrected"; instead, most symptomatic patients with internal derangements will respond well to pain management and physical medicine approaches.¹

CONCLUSION

There is no difference in condylar position by age-intervals and males present the superior space higher than females. The results of this study showed a large variation in condylar position, but there was a predominance of anterior and superior articular spaces slightly larger than the posterior space, suggesting that in these patients the condyle is at more posterior and inferior position.

REFERENCES

- Greene CS, Klasser GD, Epstein JB. Revision of the American Association of Dental Research's Science Information Statement about Temporomandibular Disorders. *J Can Dent Assoc.* 2010;76-115.
- Dworkin SF, LeResche L, DeRouen T, Von Korff M. Assessing clinical signs of temporomandibular disorders: reliability of clinical examiners. *J Prosthet Dent.* 1990;63(5):574-9.
- Fricton JR, Schiffman EL. Reliability of a Craniomandibular Index. *J Dent Res.* 1986;65(11):1359-64.
- Dworkin SF, LeResche L. Research diagnostic criteria for temporomandibular disorders: review, criteria, examinations and specifications, critique. *J Craniomand Disord* 1992;6(4):301-55.
- Clark GT, Delcanho RE, Goulet JP. The utility and validity of current diagnostic procedures for defining temporomandibular disorder patients. *Adv Dent Res.* 1993;7(2):97-112.
- Ikeda K, Kawamura A. Assessment of optimal condylar position with limited cone-beam computed tomography. *Am J Orthod Dentofacial Orthop.* 2009;135:495-501.
- Galeno J, Anderson PB, Xia JJ, Horng JC, Teichgraeber MD, Liebschner MAK. A comparative assessment of mandibular condylar position in patients with anterior disc displacement of the temporomandibular joint. *J Oral Maxillofac Surg.* 2004;62:39-43.
- Ikeda K, Kawamura A, Ikeda R. assessment of optimal condylar position in the coronal and axial planes with limited cone-beam computed tomography. *J Prosthodontol* 2011;432-438.
- Stamm T, Hohoff A, Van Meegen A, Meyer U: On the three-dimensional physiological position of the temporomandibular joint. *J Orofac Orthop* 2004;65:280-9.
- Ren YF, Isberg A, Westesson PL: Steepness of the articular eminence in the temporomandibular joint. Tomographic comparison between asymptomatic volunteers with normal disk position and patients with disk displacement. *Oral Surg Oral Med Oral Pathol Oral Radiol Endod.* 1995;80:258-66.
- Major PW, Kinniburgh RD, Nebbe B, Prasad NG, Glover KE: Tomographic assessment of temporomandibular joint osseous articular surface contour and spatial relationships associated with disc displacement and disc length. *Am J Orthod Dentofacial Orthop* 2002;121:52-61.
- Cai XY, Jin JM, Yang C. Changes in disc position, disc length, and condylar height in the temporomandibular joint with anterior disc displacement: a longitudinal retrospective magnetic resonance imaging study. *J Oral Maxillofac Surg.* 2011;69:340-6.
- Tasaki MM, Westesson PL, Isberg AM, Ren YF, Tallents RH. Classification and prevalence of temporomandibular joint disc displacement in patients and symptom-free volunteers. *Am J Orthod Dentofacial Orthop* 1996;109:249-62.
- Kobayashi K, Shimoda S, Nakagawa Y, Yamamoto A. Accuracy in measurement of distance using limited cone-beam computer-ized tomography. *Int J Oral Maxillofac Implants.* 2004;19:228-31.
- Fricton JR, Schiffman EL. The craniomandibular index: validity. *J Prosthet Dent.* 1987 Aug;52(2):222-8.
- Bonilla-Aragon H, Tallents RH, Katzberg RW, Kyrkanides S, Moss ME: Condyle position as a predictor of temporomandibular joint internal derangement. *J Prosthet Dent.* 1999;82:205-8.
- Vasconcelos Filho JO, Menezes AV, Freitas DQ, Manzi FR, Bóscolo FN, Almeida, SM: Condylar and disk position and signs and symptoms of temporomandibular disorders in stress-free subjects. *JADA.* 2007;138:1251-1255.
- Christiansen EL, Chann TT, Thompson JR, Hasso AN, Hinshaw DB Jr, Kopp S: Computed tomography of the normal temporomandibular joint. *Scand J Dent Res.* 1987;95:499-509.
- Vitral, RWF, Campos MJS, Rodrigues AF, Fraga MR. Temporomandibular joint and normal occlusion: is there anything singular about it? A computed tomographic evaluation. *Am J Orthod Dentofacial Orthop.* 2011;140:18-24.
- Kinniburgh RD, Major PW, Nebbe B, West K, Glover KE. Osseous morphology and spatial relationships of the temporomandibular joint: comparisons of normal and anterior disc positions. *Angle Orthod.* 2000;70:70-80.

**Marcelo Oliveira Mazzetto
(Corresponding address)**

School of Dentistry of Ribeirão Preto,
University of São Paulo (FORP-USP), Av.
do Café s/n, Ribeirão Preto, SP, Brazil,
CEP:14040-904
E-mail: mazzetto@forp.usp.br *

Date submitted: 2014 Feb 26

Accept submission: 2014 Jun 13